



SAPIENZA
UNIVERSITÀ DI ROMA

Hernias

Giuseppe Nigri

UOC Chirurgia Generale

Dipartimento di Scienze Medico-Chirurgiche e
Medicina Traslazionale

Sapienza Universtità di Roma

HERNIAS

- Hernia from Latin hernia "a rupture,"
- More than **600,000 hernias** are repaired annually in the US, making hernia repair **one of the most common operations** performed by general surgeons
- **Hernia:** an abnormal protrusion of an organ or tissue through a defect in its surrounding walls
- **Abdominal wall hernias** occur only at sites at which the aponeurosis and fascia are not covered by striated muscle:
 - inguinal, femoral, and umbilical areas, linea alba, lower portion of the semilunar line, and sites of prior incisions

Primary Abdominal Wall Hernias

Groin

Inguinal

- Indirect
- Direct
- Combined

Femoral

Anterior

Umbilical

Epigastric

Spigelian

Pelvic

Obturator

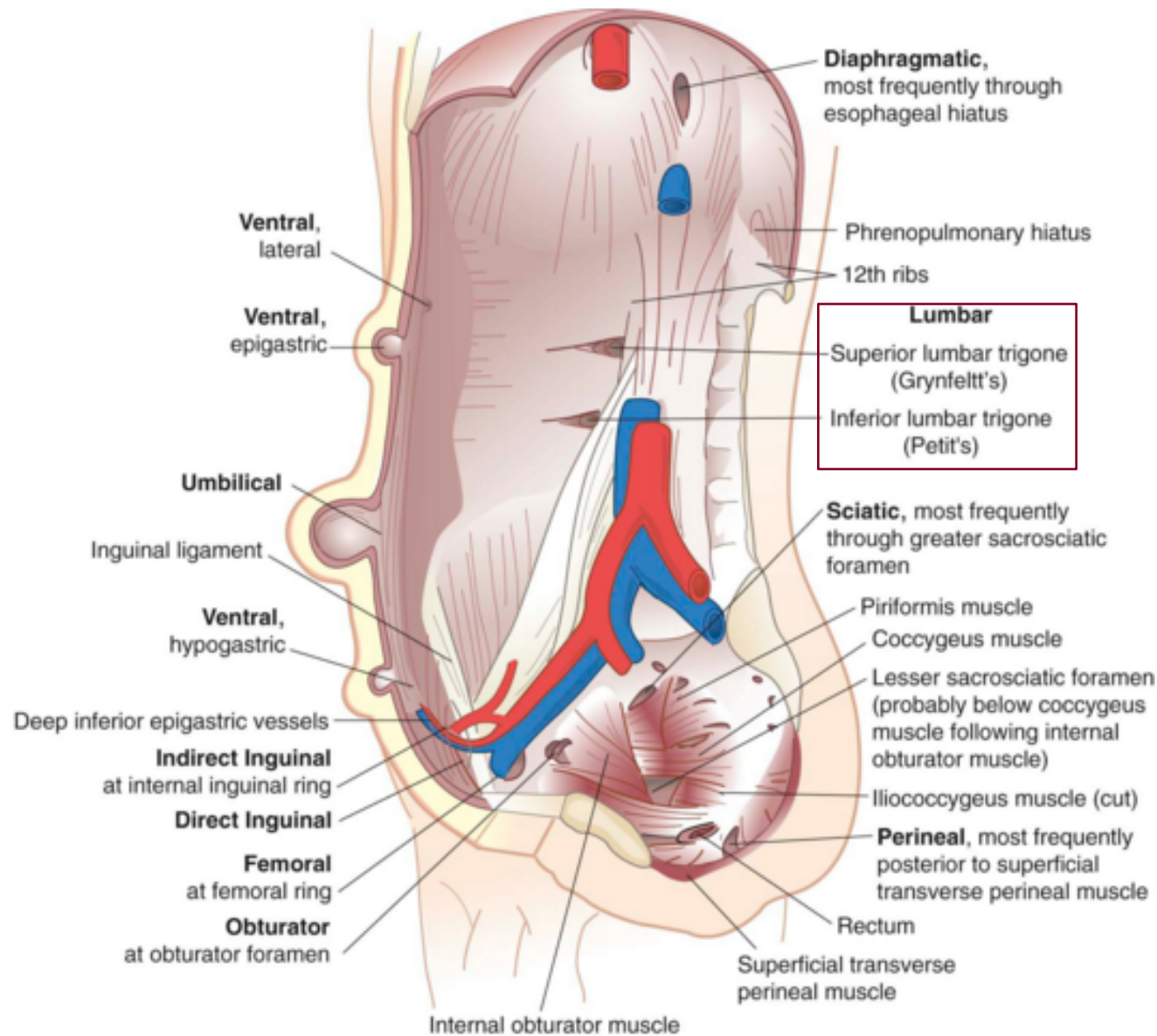
Sciatic

Perineal

Posterior

Lumbar

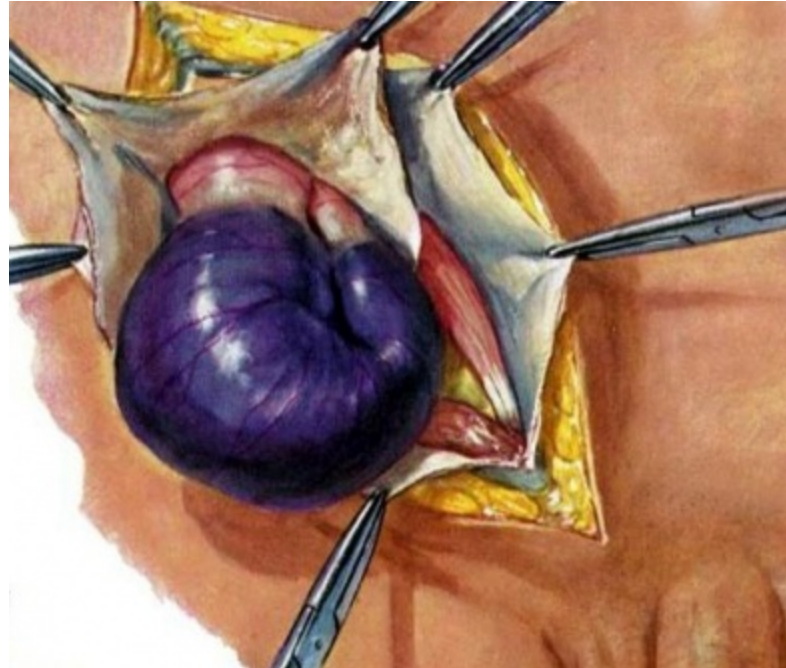- Superior triangle
- Inferior triangle



HERNIAS

- **Neck of a hernia:** it is located at the innermost musculoaponeurotic layer
- **Hernia sac:** it is lined by peritoneum and protrudes from the neck
- **Reducible:** when its contents can be replaced within the surrounding musculature, and it is irreducible or incarcerated when it cannot be reduced
- **A strangulated hernia** has compromised blood supply to its contents. Common in **large hernias that have small orifices**. The small neck obstructs arterial blood flow, venous drainage, or both
- **Adhesions** between the contents of the hernia and peritoneal lining of the sac can **entrap the hernia contents** and predisposes to intestinal **obstruction and strangulation**
- **Richter's hernia:** a **small portion of the antimesenteric wall** of the intestine is trapped within the hernia, and **strangulation can occur without the presence of intestinal obstruction**

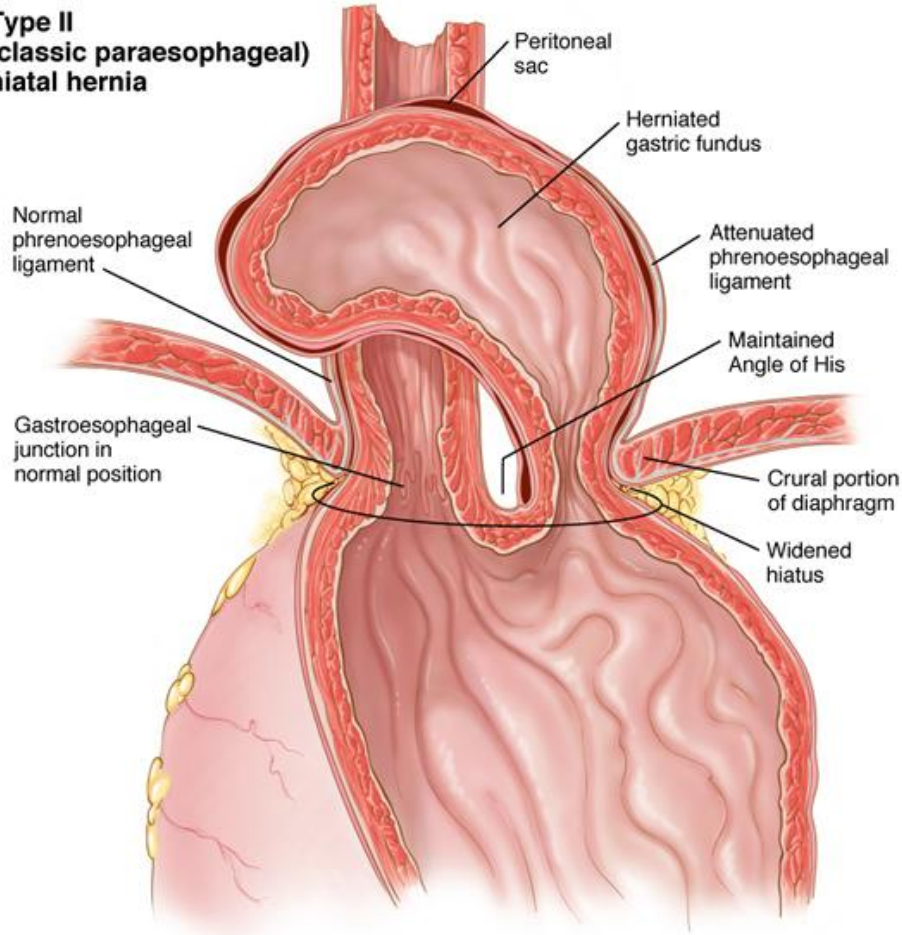
HERNIAS



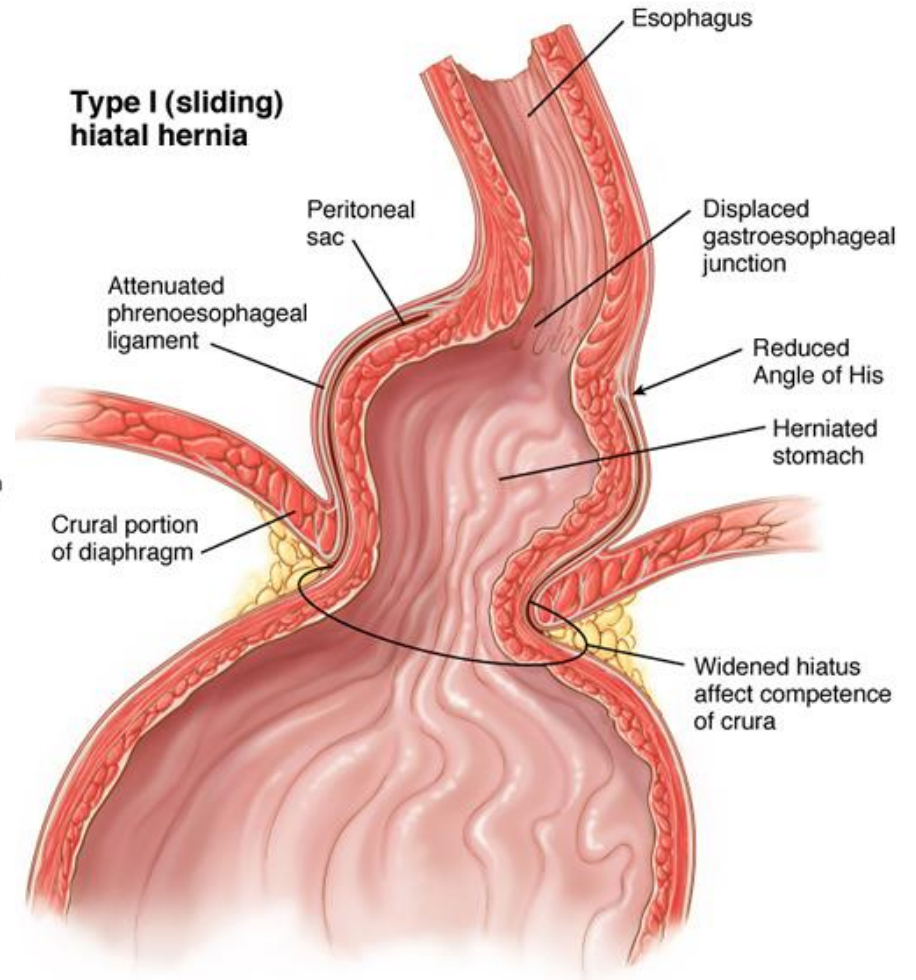
HERNIAS

- **An external hernia** protrudes through all layers of the abdominal wall
- **An internal hernia** is a protrusion of intestine through a defect in the peritoneal cavity
- **An interparietal hernia** occurs when the hernia sac is contained within a musculoaponeurotic layer of the abdominal wall

**Type II
(classic paraesophageal)
hiatal hernia**



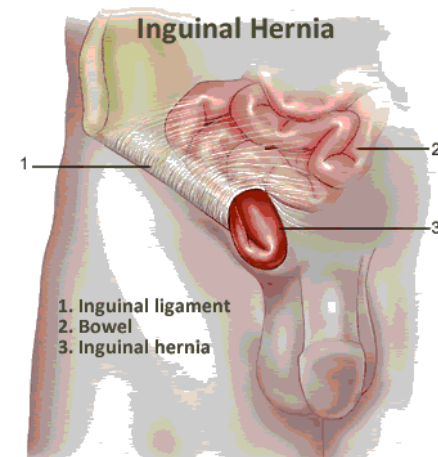
**Type I (sliding)
hiatal hernia**



INGUINAL HERNIAS

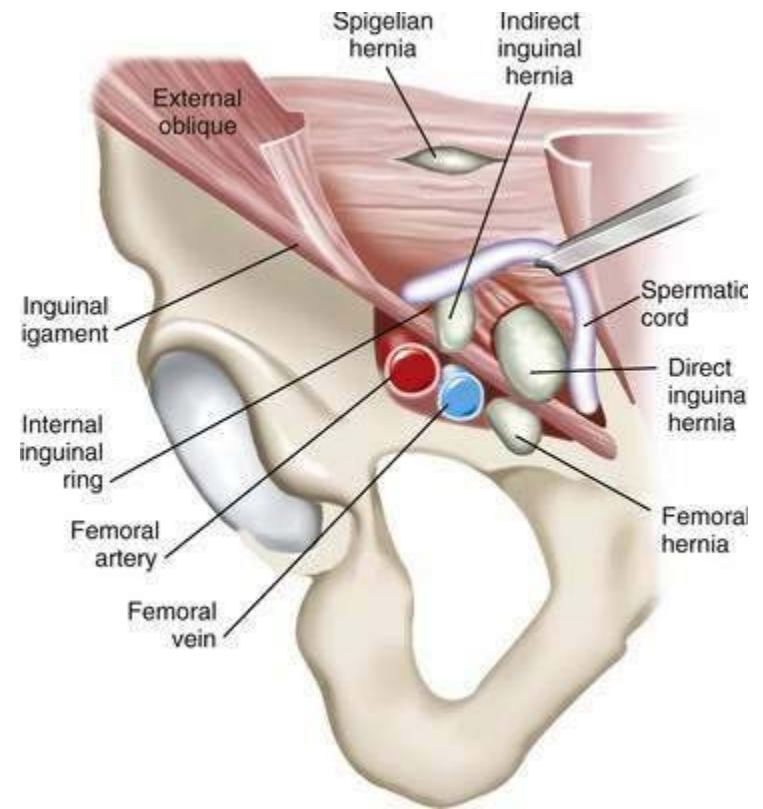
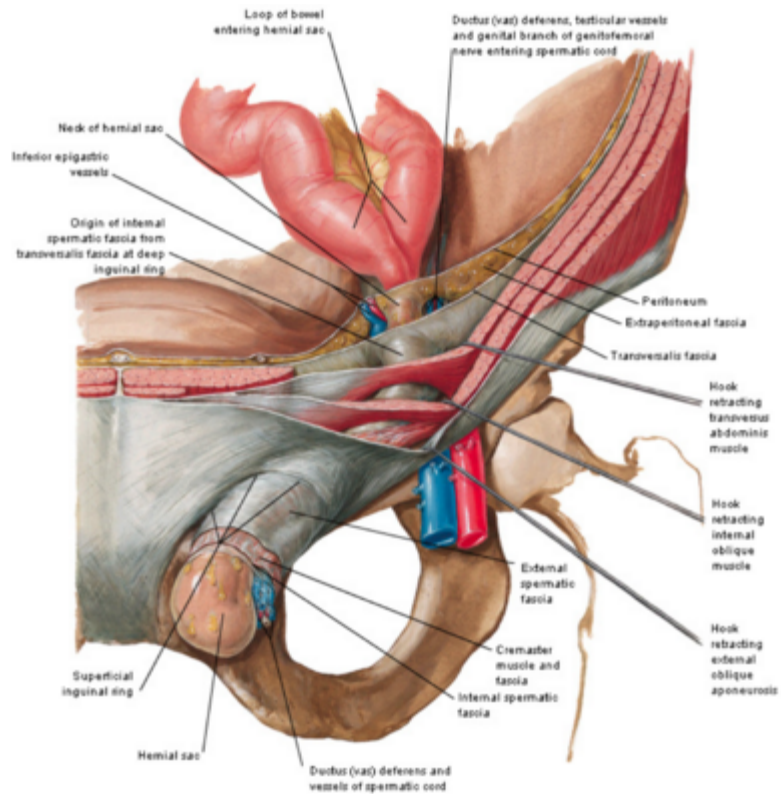
Direct or indirect

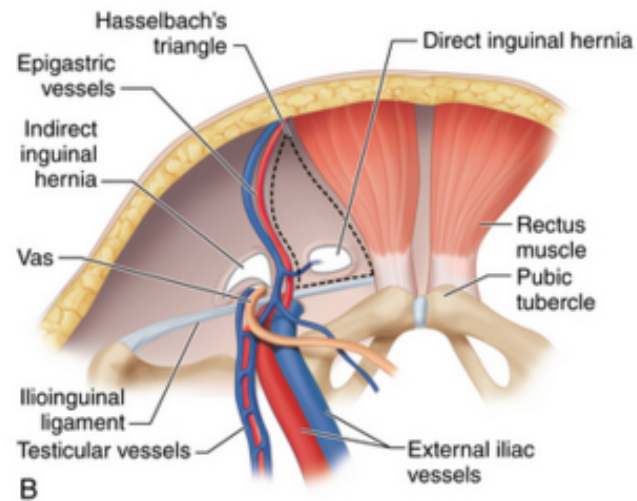
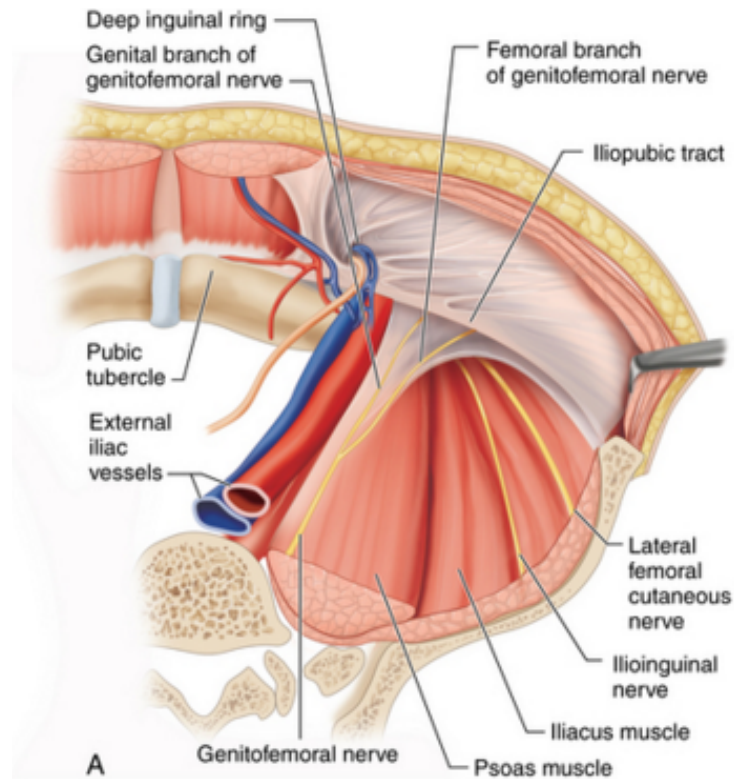
- **The sac of an indirect inguinal hernia** passes from the internal inguinal ring obliquely toward the external inguinal ring and ultimately into the scrotum
- **The sac of a direct inguinal hernia** protrudes outward and forward and is medial to the internal inguinal ring and inferior epigastric vessels
- A **pantaloon-type hernia** occurs when there is an indirect and direct hernia component
- It is estimated that **5% of the population** will develop an abdominal wall hernia, but the prevalence may be even higher
- About **75%** of all hernias occur in the inguinal region
 - **2/3 are indirect 1/3 are direct inguinal hernias**
- **Femoral hernias: 3% of all groin hernias**



INGUINAL HERNIAS

- **Men are 25 times more likely** to have a **groin hernia** than women
- An **indirect inguinal hernia** is the **most common** hernia
- In men, **indirect/direct** ratio of 2 : 1. Direct hernias are uncommon in women
- **Female-to-male ratio:** femoral hernias 10:1; umbilical hernias 2:1
- Although **femoral hernias** occur more frequently in women than in men, **inguinal hernias** remain the **most common hernia in women**. **Femoral hernias are rare in men**
- 10% of women and 50% of men who have a **femoral hernia** have or will develop an **inguinal hernia**

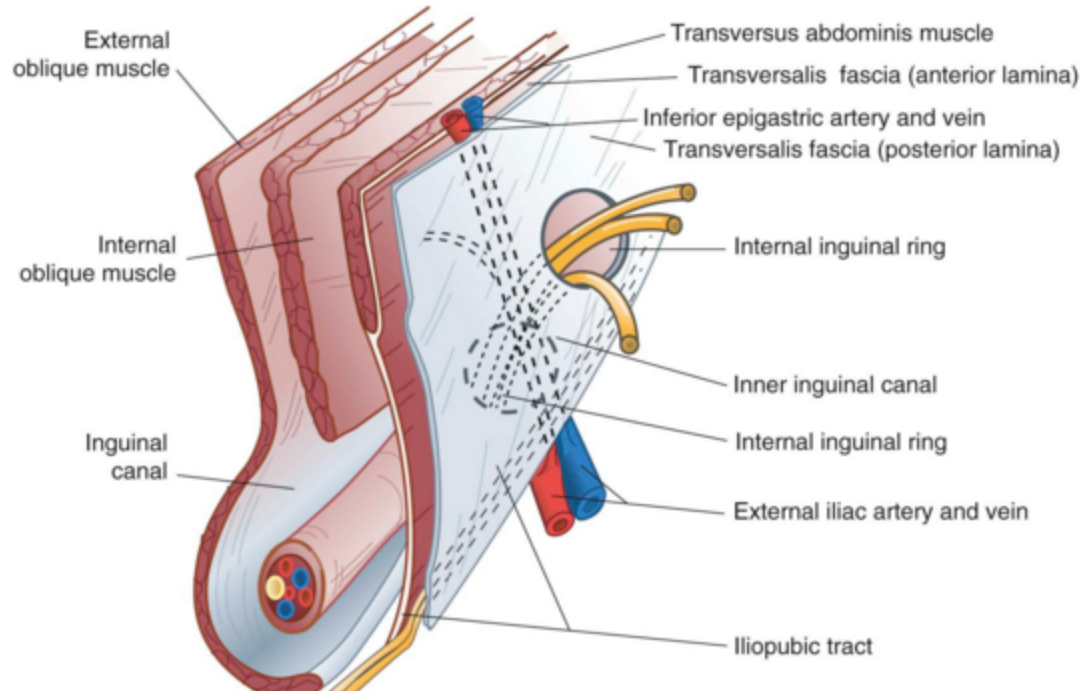


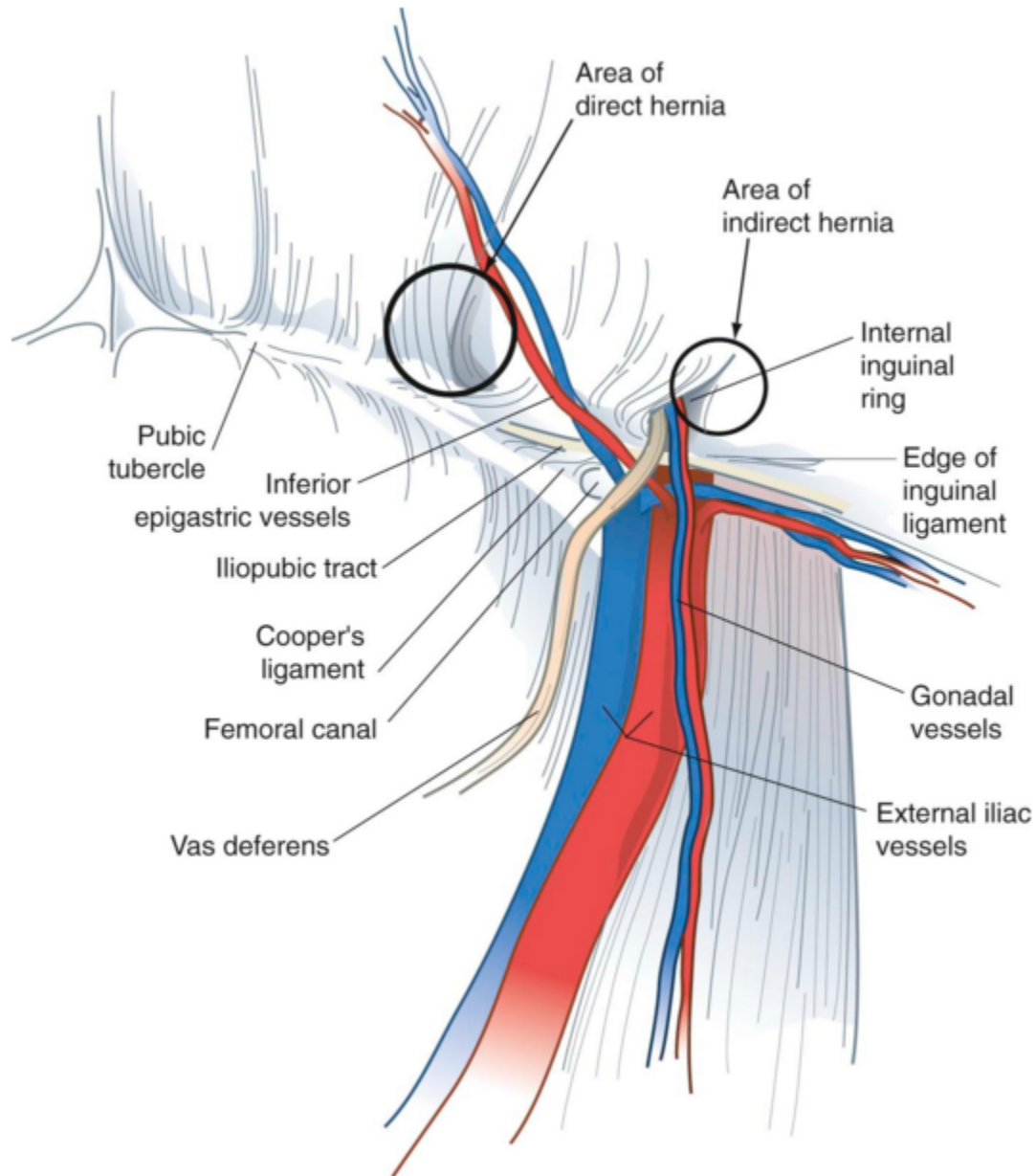


INGUINAL HERNIAS

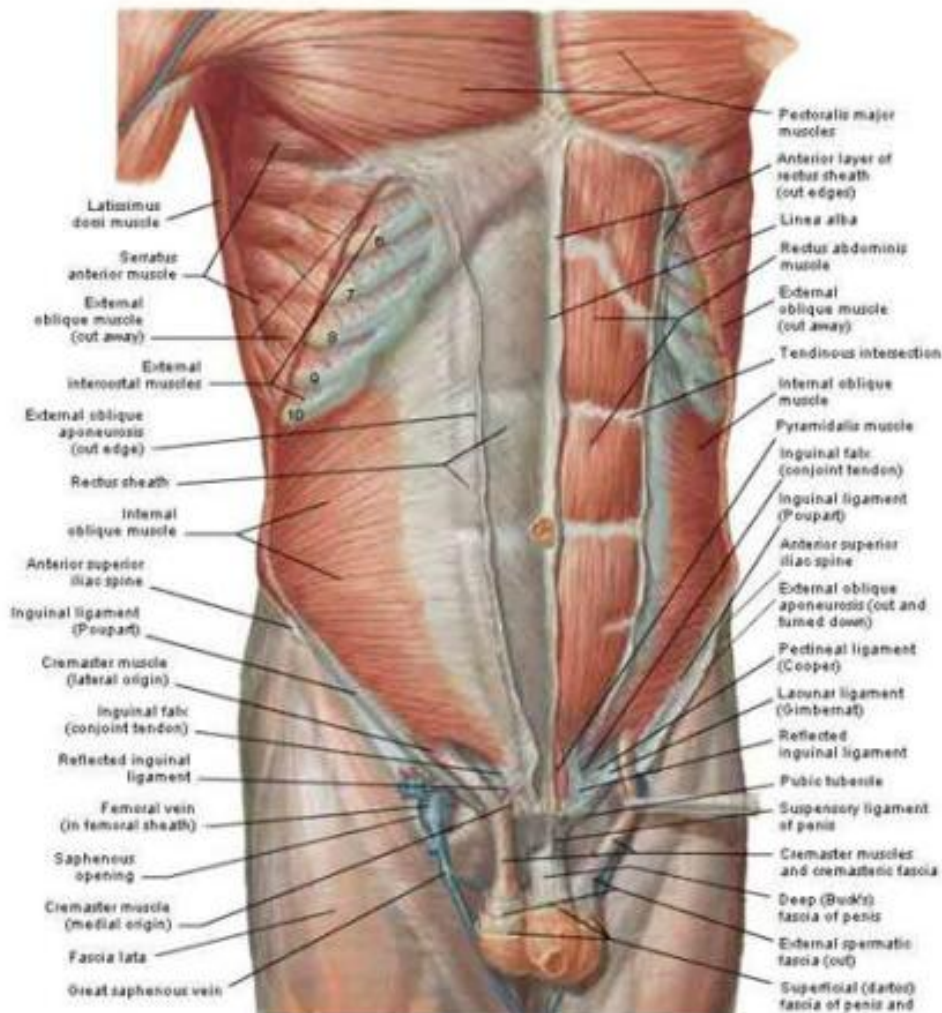
- **Indirect inguinal and femoral hernias** occur more commonly on the **right side**. This is attributed to a **delay in atrophy of the processus vaginalis** after the normal slower descent of the right testis to the scrotum during fetal development
- The predominance of **right-sided femoral hernias** is probably caused by the **tamponading effect of the sigmoid colon on the left femoral canal**
- The prevalence of hernias **increases with age**
- **Strangulation: 1% to 3% of groin hernias; ↑ with age**
- Most strangulated hernias are **indirect inguinal hernias**
- **Femoral hernias have the highest rate of strangulation (15% to 20%) of all hernias** and it is therefore **recommended that all femoral hernias be repaired at the time of discovery**

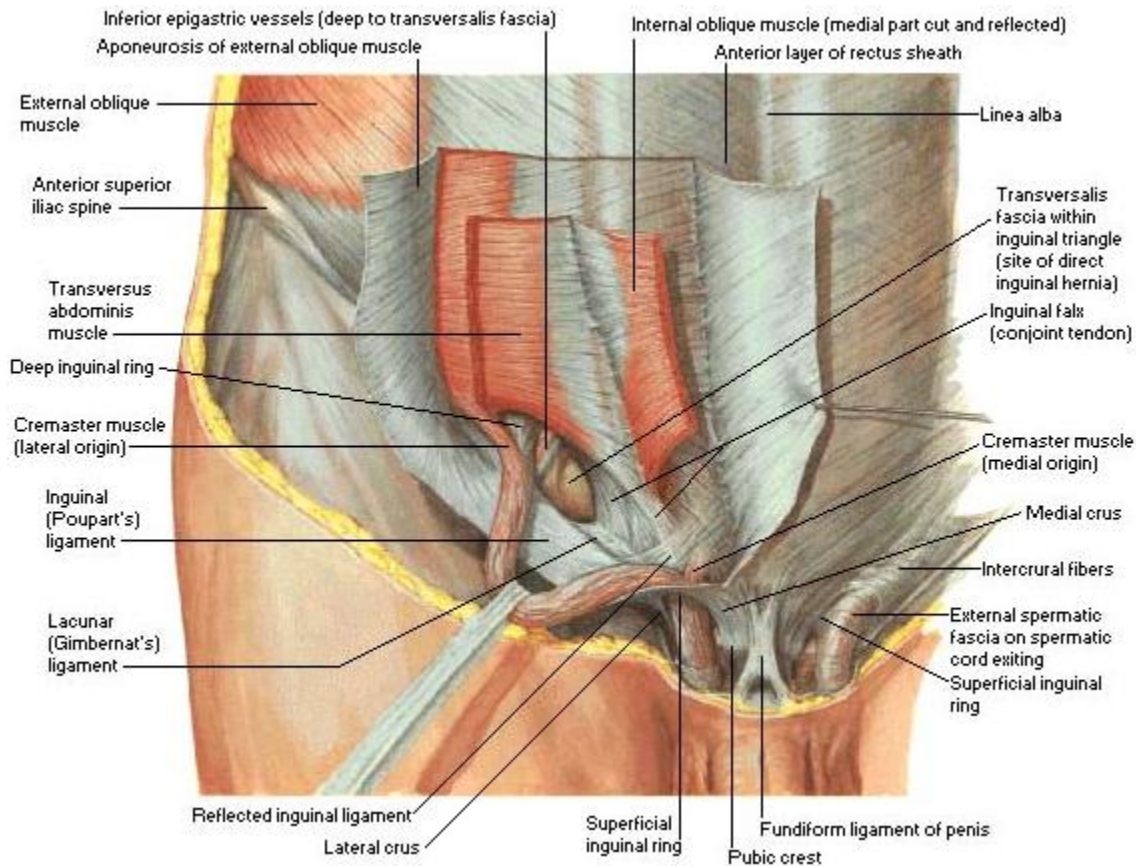
ANATOMY OF THE GROIN

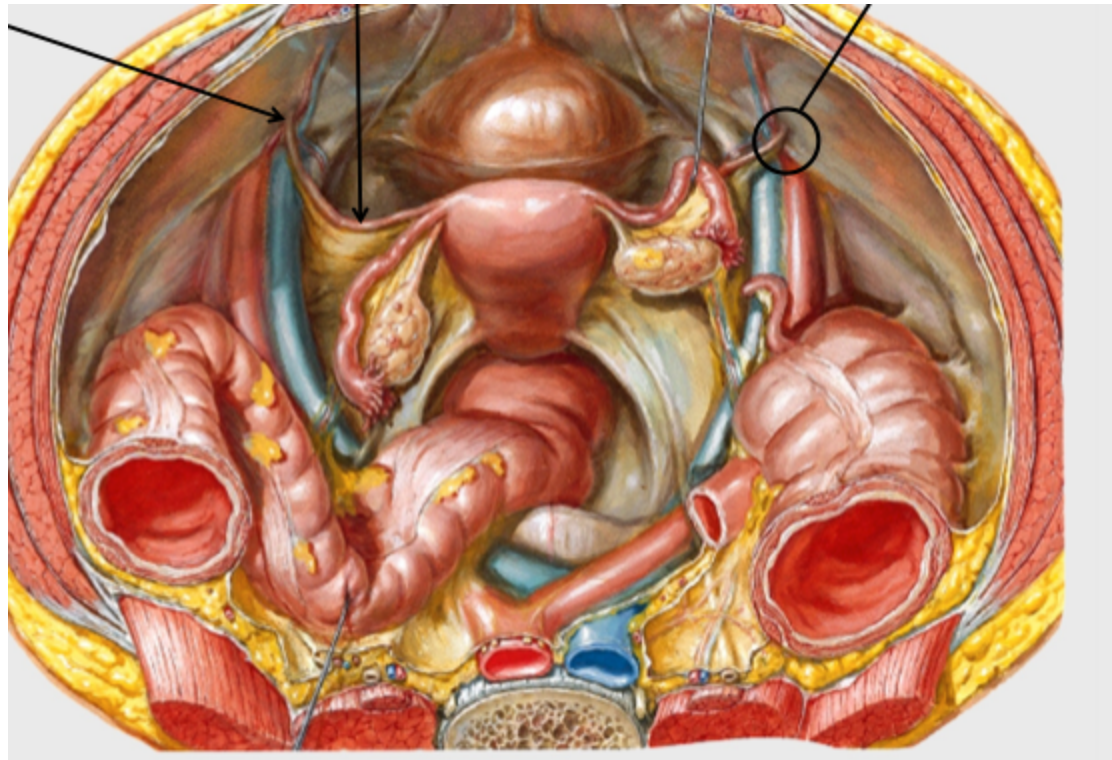


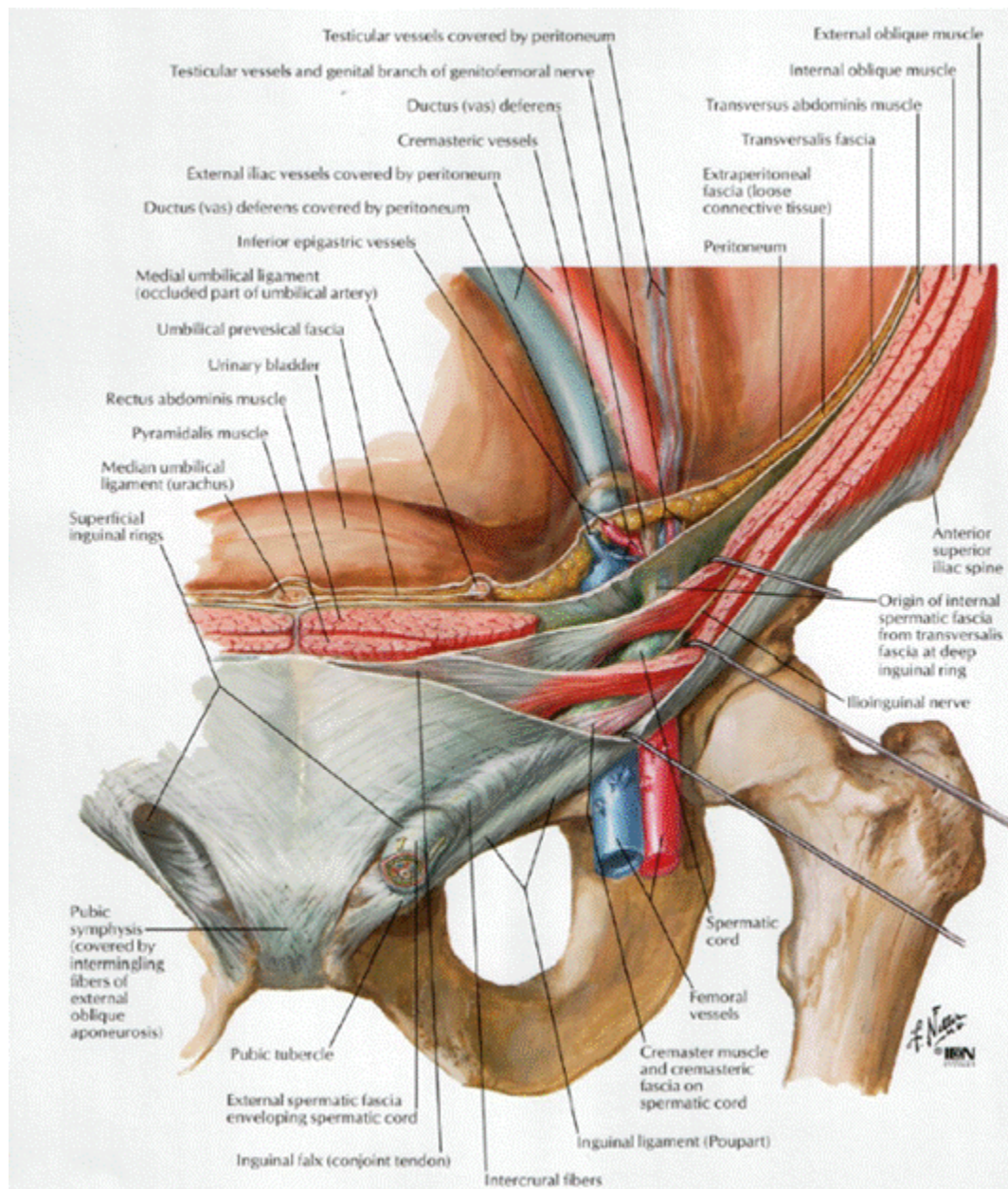


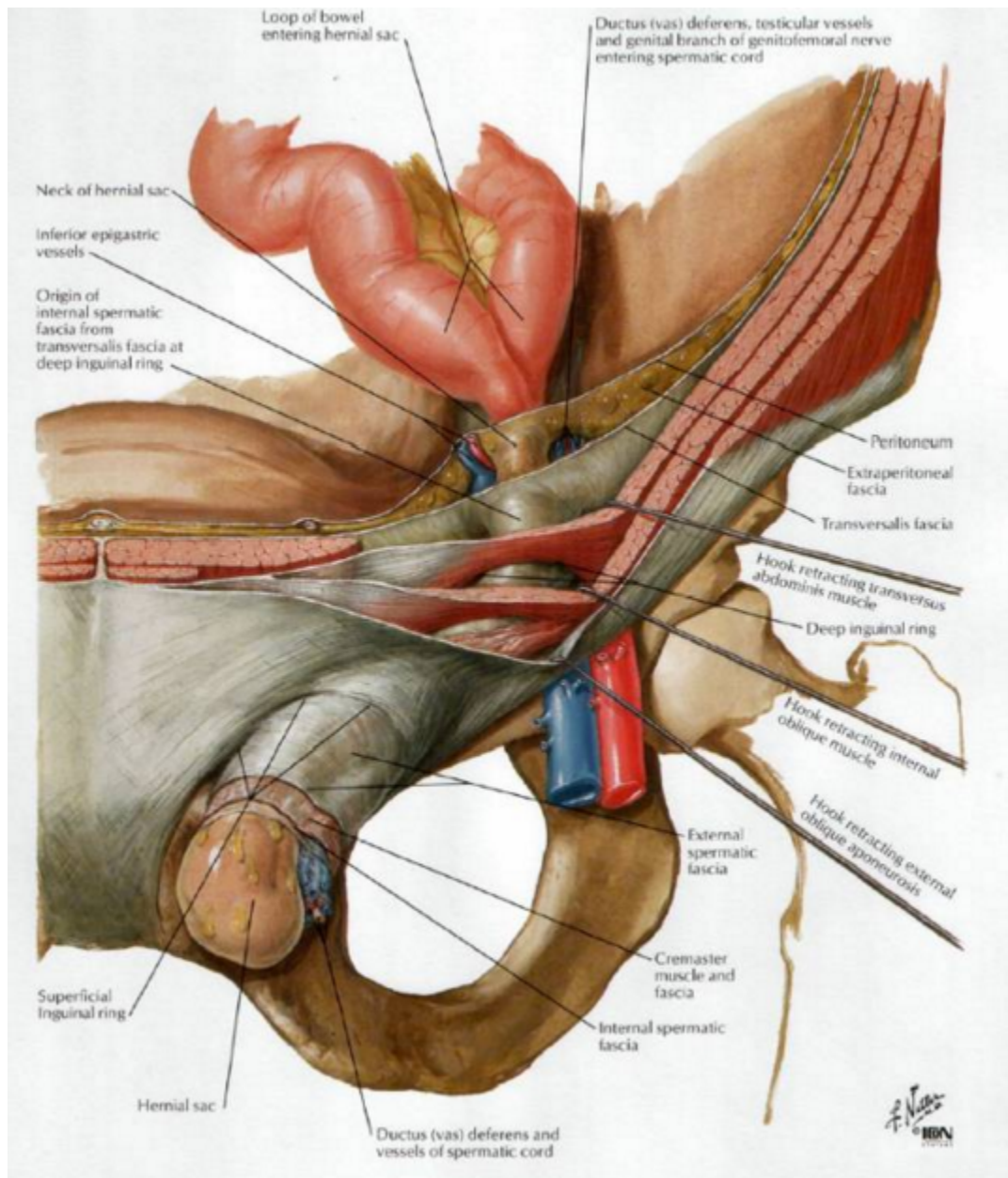
Anterior Abdominal Wall Intermediate Dissection

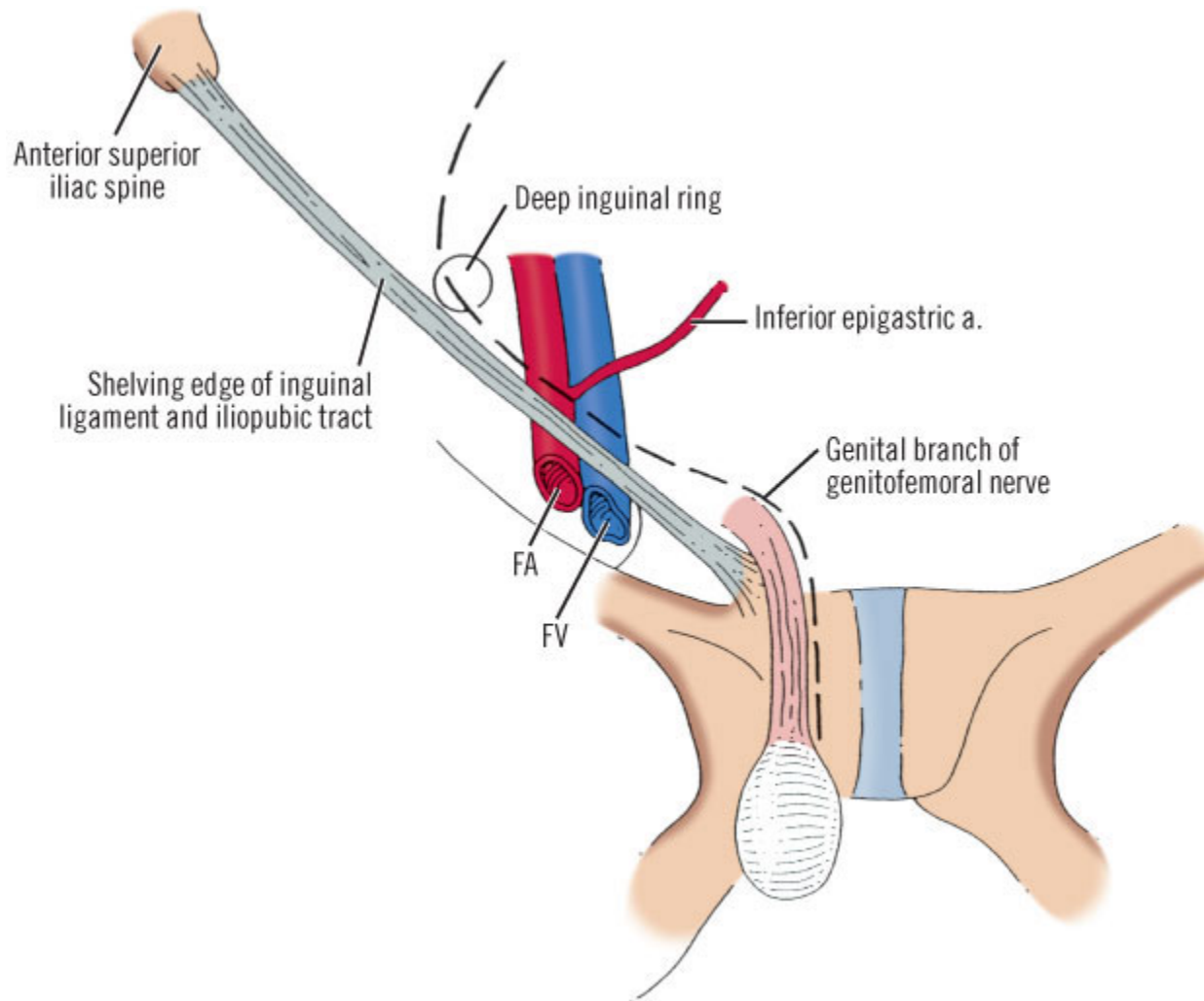












ANATOMY OF THE GROIN

External Oblique Muscle

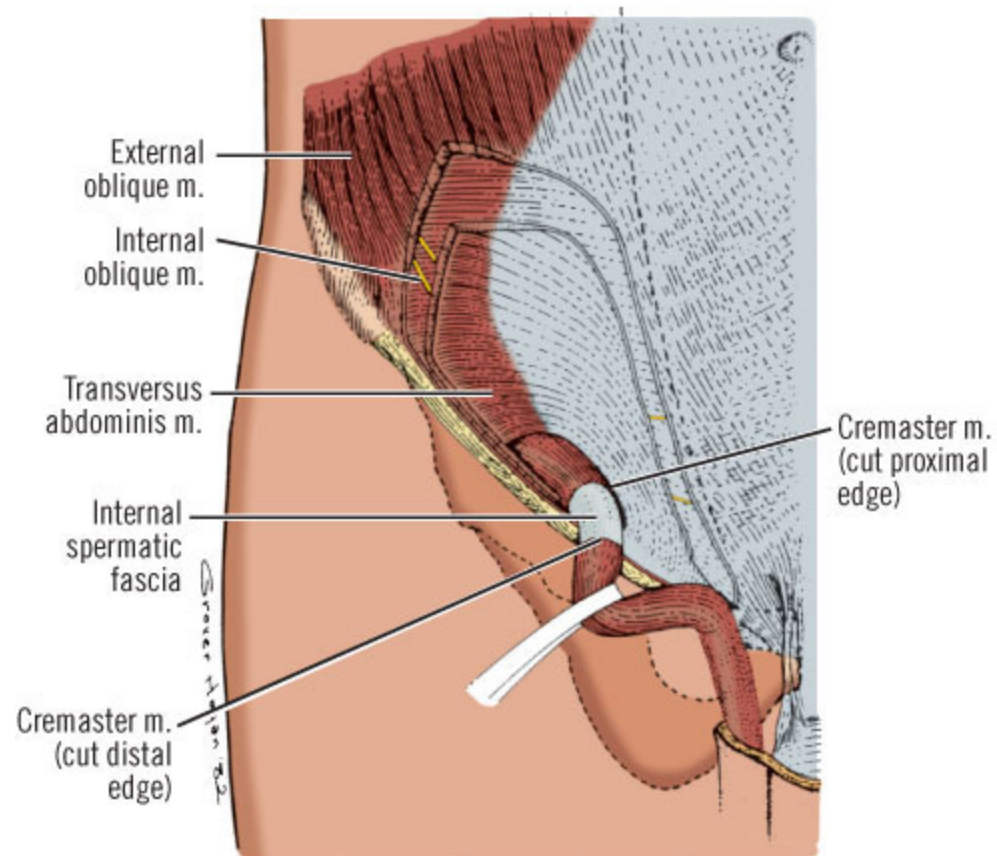
Origin: sternum, ribs 5-12

Insertion: pubis, linea alba, iliac crest

Innervation: lower intercostal,) ileohypogastric (T12-L1) and ileoinguinal (T12-L1) nerves

Blood Supply: intercostal arteries, subcostal artery and deep circumflex iliac artery

Action: bilaterally compresses the abdomen and flexes (bends) the spine.
Unilaterally: laterally flexes trunk to same side and rotates trunk to opposite side

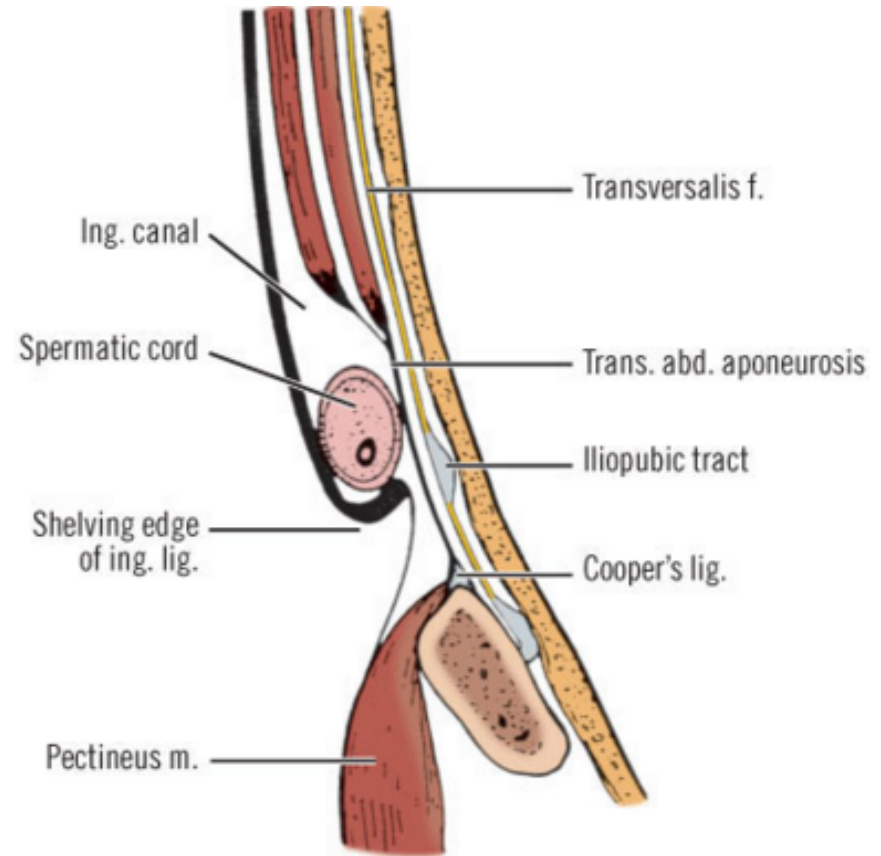
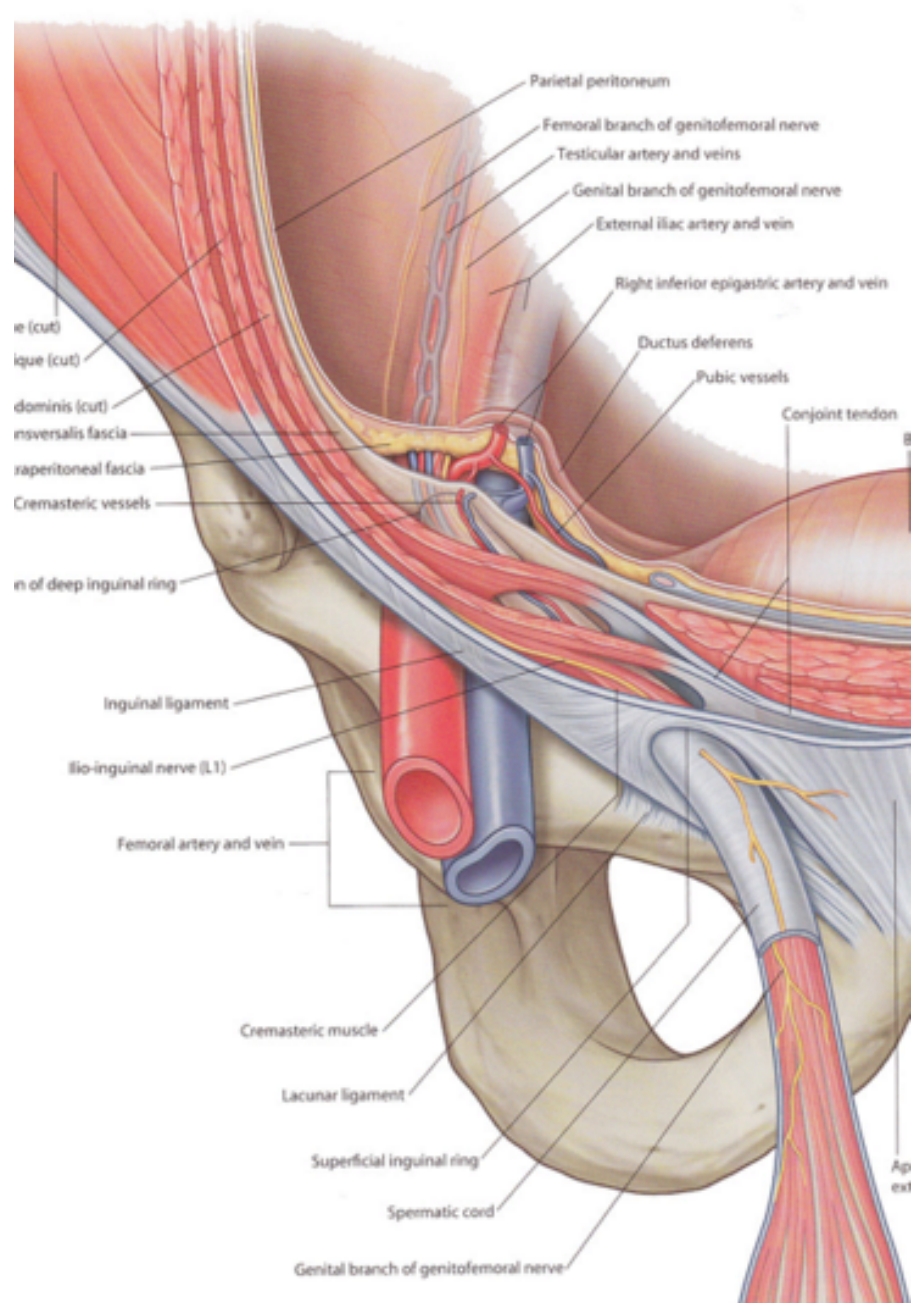


External Oblique Muscle

The external oblique muscle is **the most superficial** of the lateral abdominal wall muscles

The **external oblique aponeurosis** serves as the superficial boundary of the inguinal canal. **The inguinal ligament (Poupart's ligament)** is the inferior edge of the external oblique aponeurosis and extends from the anterior superior iliac spine to the pubic tubercle, turning posteriorly to form a shelving edge

The lacunar ligament is the fan-shaped medial expansion of the inguinal ligament, which inserts into the pubis and forms the medial border of the femoral space. The external (superficial) inguinal ring is an ovoid opening of the external oblique aponeurosis that is positioned superiorly and slightly laterally to the pubic tubercle. The spermatic cord exits the inguinal canal through the external inguinal ring.



Internal Oblique Muscle

Origin: inguinal ligament, iliac crest, lumbodorsal fascia

Insertion: pubis, ribs 9-12, linea alba

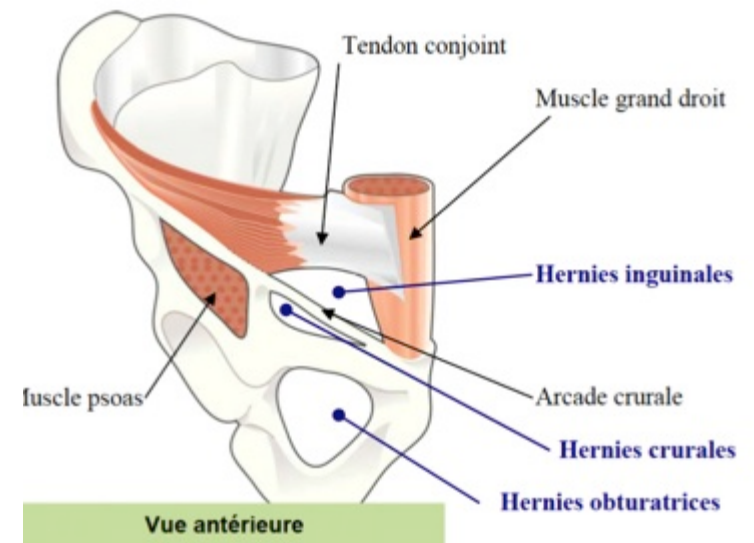
Innervation: lower 5 thoracic nerve, 1^o lumbar nerve (T8-L1) ileohypogastric (T12-L1) and ileoinguinal (T12-L1) nerves

Blood Supply: intercostal arteries, subcostal arteries

Action: bilaterally compresses the abdomen and flexes (bends) the spine.
Unilaterally: laterally flexes and rotates the spine to the same side

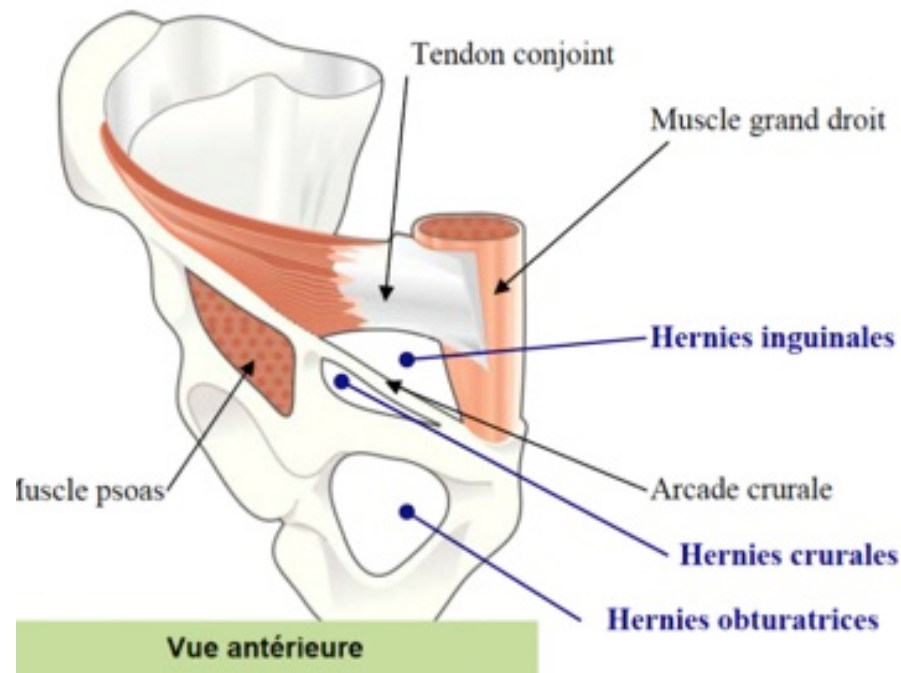
Internal Oblique Muscle

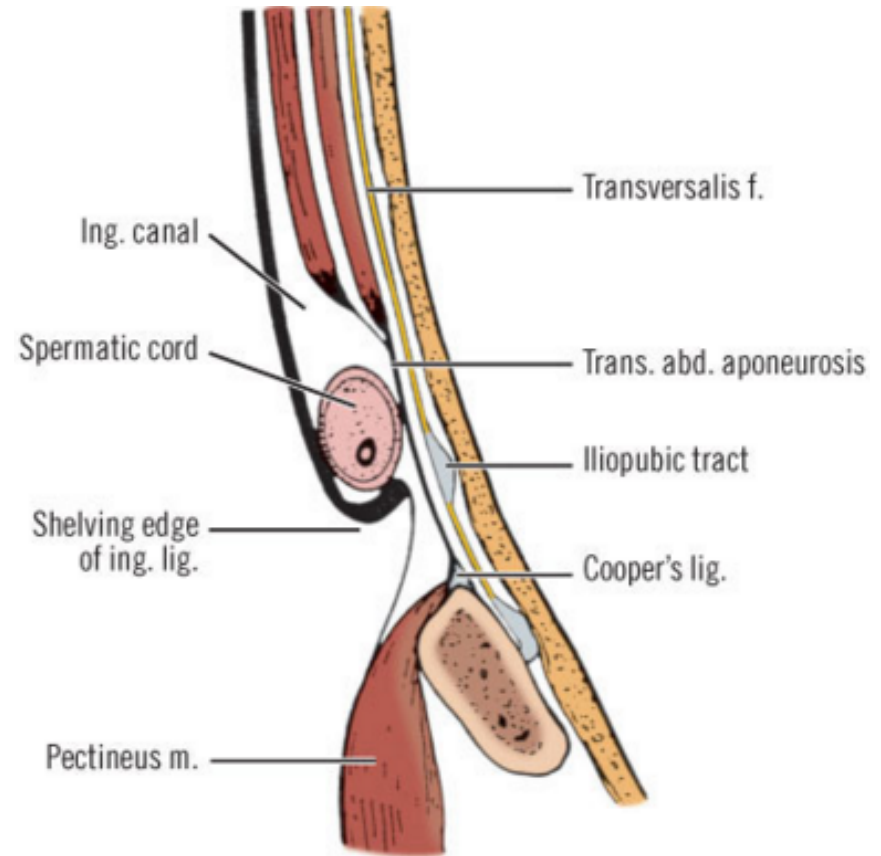
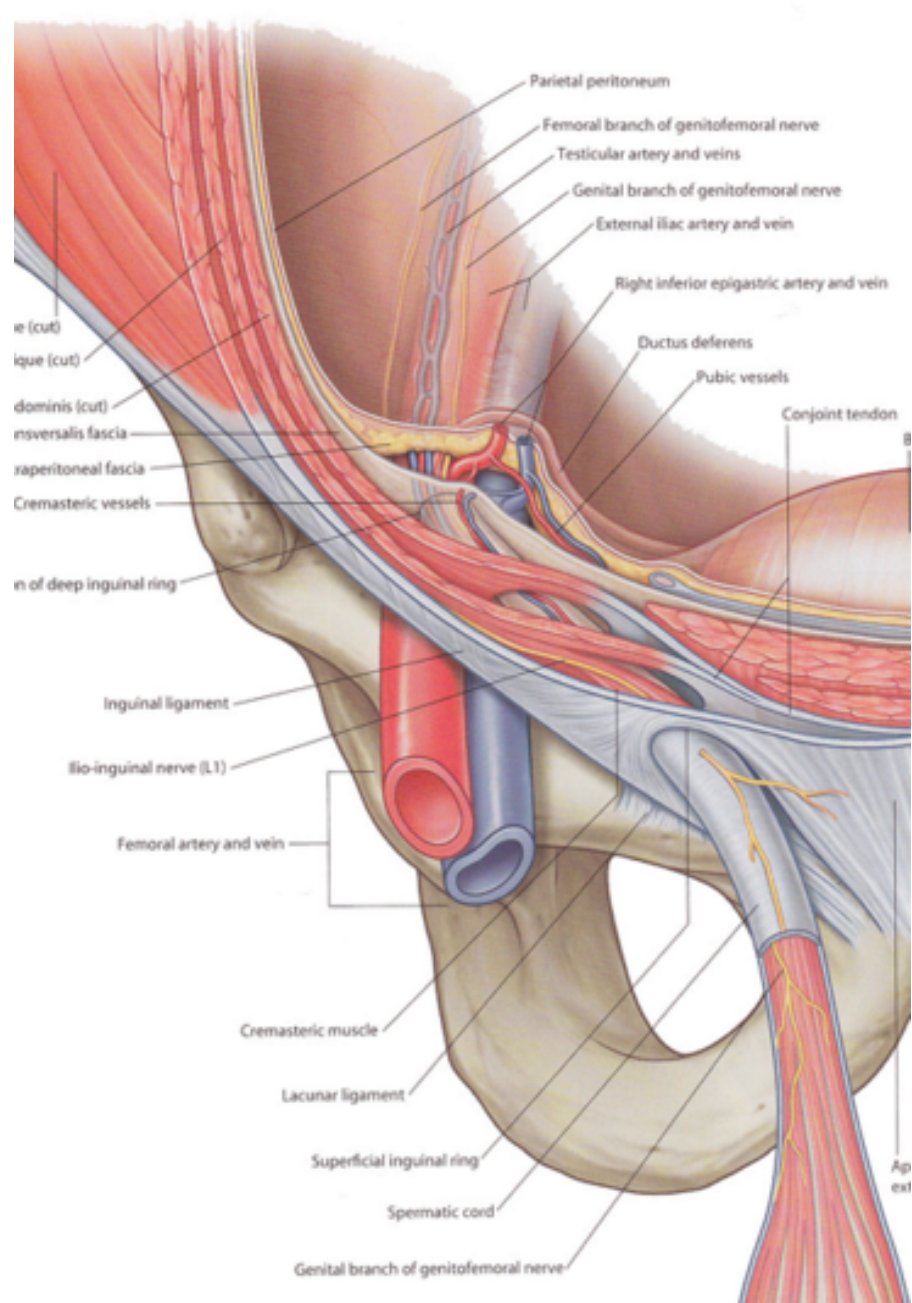
- It forms the **middle layer of the lateral abdominal musculoaponeurotic complex**
- The internal oblique muscle serves as the cephalad (or superior) border of the inguinal canal
- The medial aspect of the internal oblique aponeurosis fuses with fibers from the transversus abdominis aponeurosis to form a **conjoined tendon**



Internal Oblique Muscle

- This structure actually is present in only 5% to 10% of patients and is most evident at the insertion of these muscles on the pubic tubercle
- The cremasteric muscle fibers arise from the internal oblique, encompass the spermatic cord, and attach to the tunica vaginalis of the testis





Transversus Abdominis Muscle

Origin: inguinal ligament, iliac crest, lower six ribs, lumbodorsal fascia

Insertion: Upper $\frac{3}{4}$ form the back of the rectus sheath, and insert on the linea alba. The lower fourth form the front of the rectus sheath and attaches to the pubis

Innervation: lower 6 thoracic nerves, 1^o lumbar nerve (T7-L1) ileohypogastric (T12-L1) and ileoinguinal (T12-L1) nerves

Blood Supply: subcostal arteries

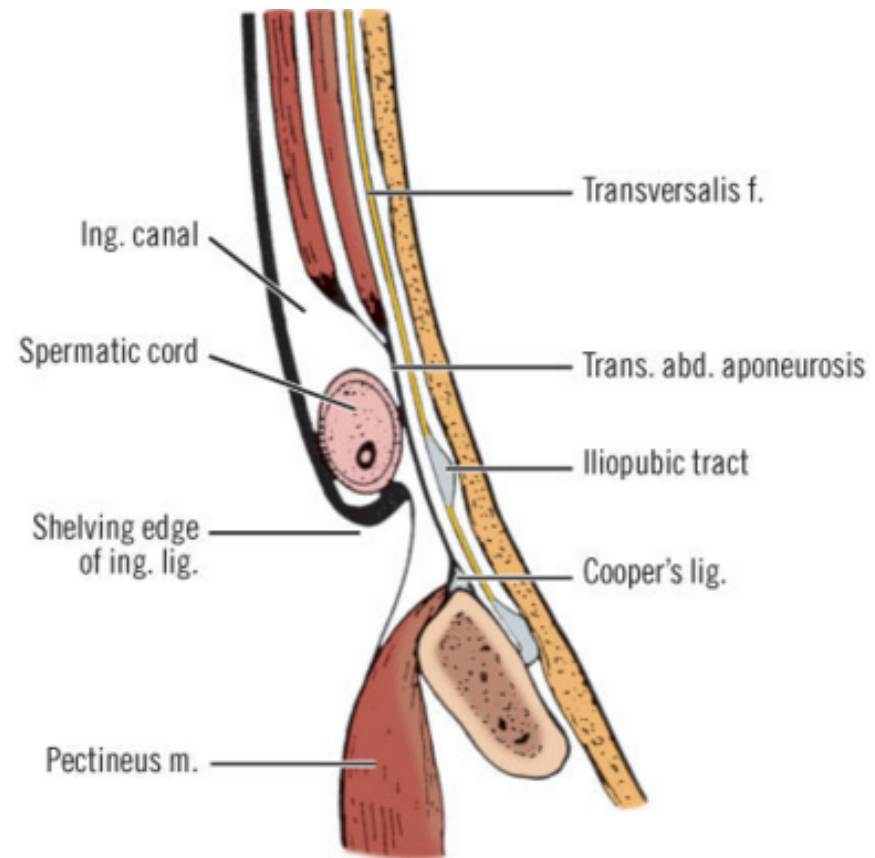
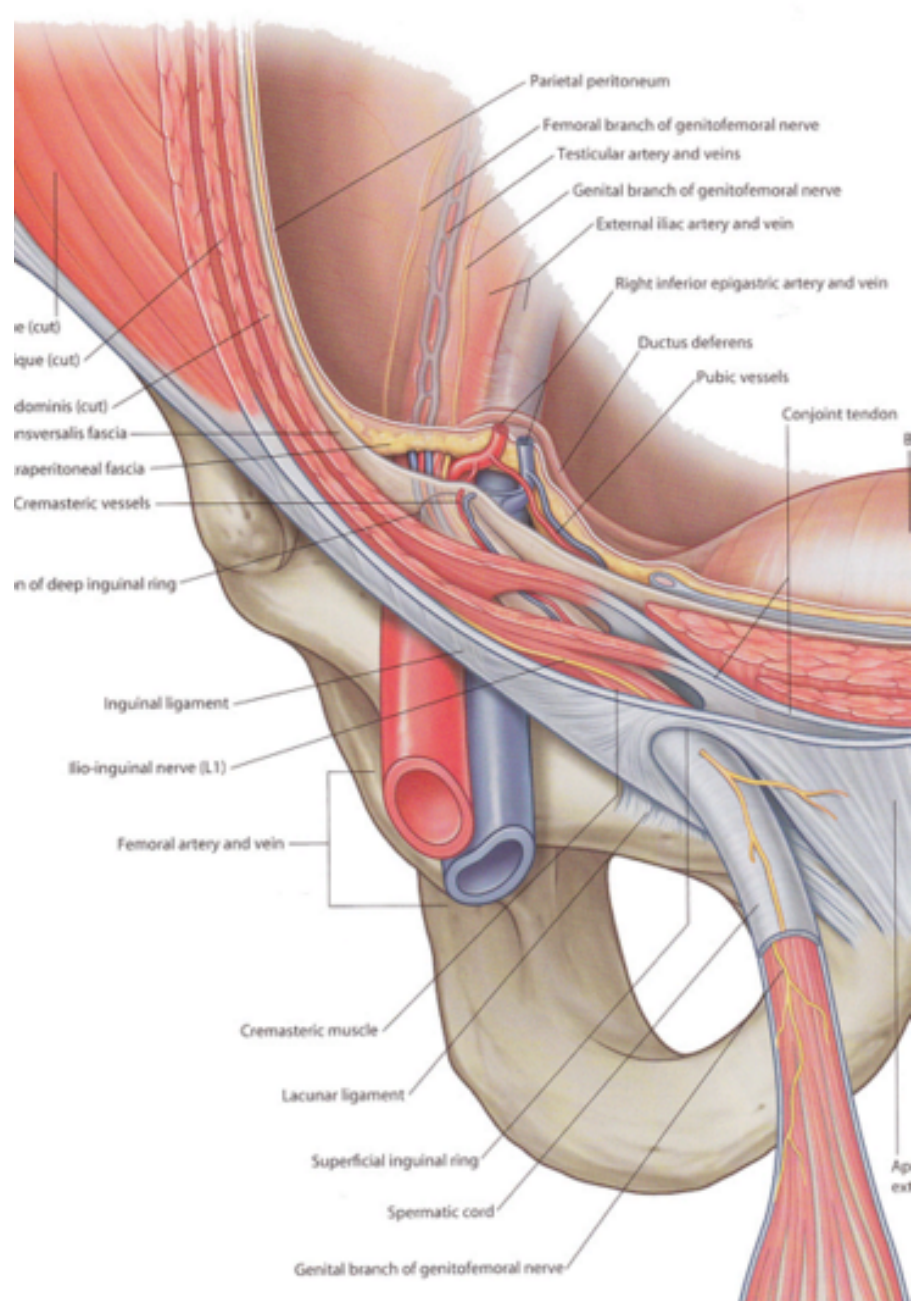
Action: compresses the abdominal viscera, tenses the abdominal wall

Transversus Abdominis Muscle

- The **lower margin** of the transversus abdominis arches along with the internal oblique muscle over the internal inguinal ring to form the **transversus abdominis aponeurotic arch**

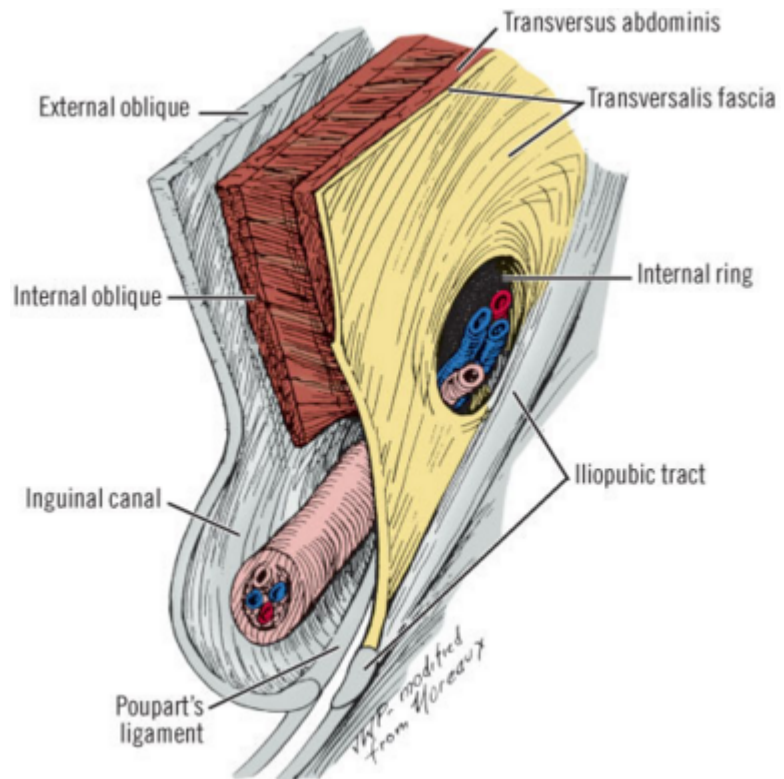
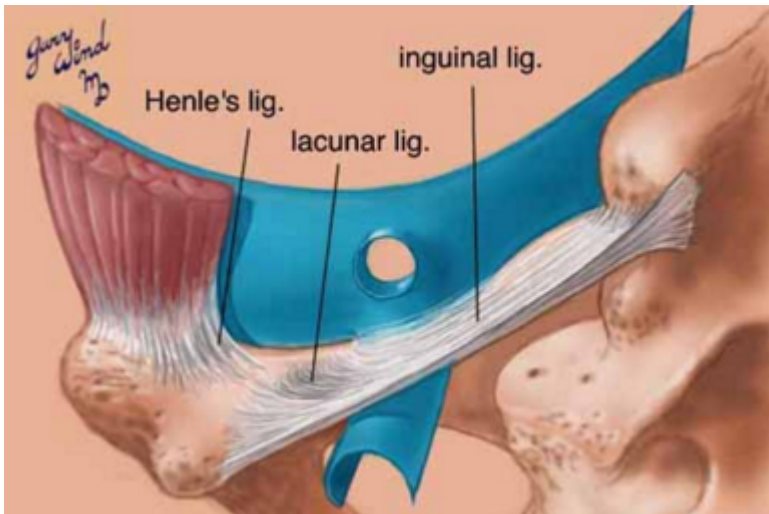
The transversalis fascia

- It is the connective tissue layer that underlies the abdominal wall musculature
- The transversalis fascia, sometimes referred to as the *endoabdominal fascia*, is a component of **the floor of the inguinal canal**



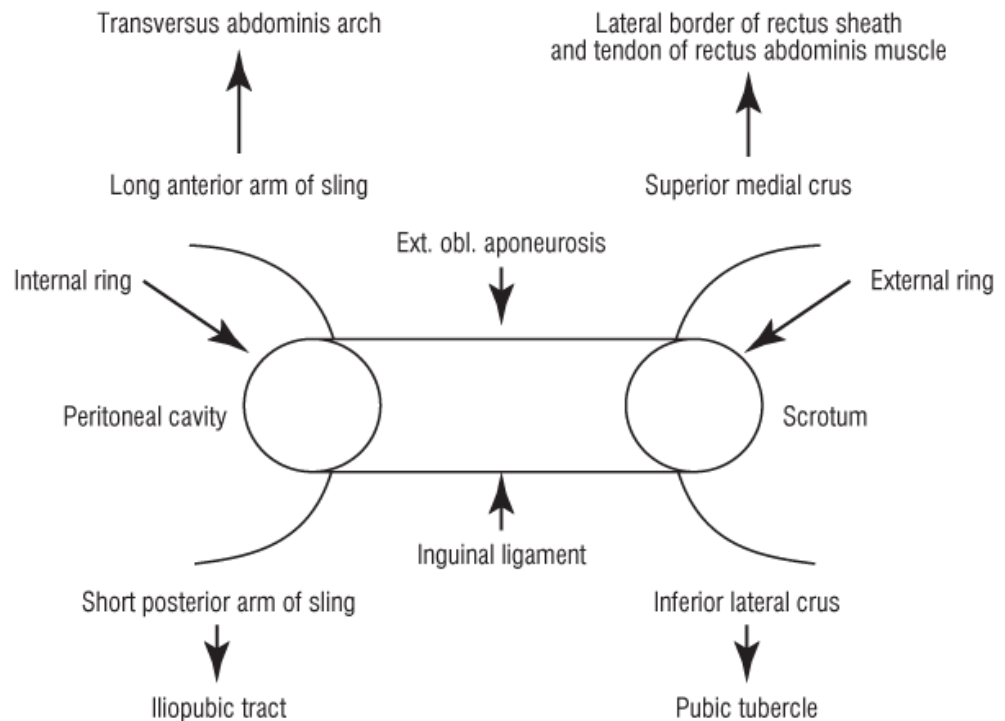
The iliopubic tract

- It is an **aponeurotic band** that is formed by the **transversalis fascia and transversus abdominis aponeurosis and fascia**
- the iliopubic tract is located **posterior to the inguinal ligament** and crosses over the femoral vessels and inserts on the anterior superior iliac spine and inner lip of the wing of the ilium



The iliopubic tract

- It is an **aponeurotic band** that is formed by the **transversalis fascia and transversus abdominis aponeurosis and fascia**
- the iliopubic tract is located **posterior to the inguinal ligament** and crosses over the femoral vessels and inserts on the anterior superior iliac spine and inner lip of the wing of the ilium



The spermatic cord

- is composed of the **cremasteric muscle fibers, testicular artery and accompanying veins, genital branch of the genitofemoral nerve, vas deferens, cremasteric vessels, lymphatics, and processus vaginalis**
- These structures enter the cord at the internal inguinal ring and vessels and vas deferens exit the external inguinal ring

The cremaster muscle

- It arises from the lowermost fibers of the **internal oblique muscle** and encompasses the spermatic cord in the inguinal canal
- The **cremasteric vessels** are branches of the **inferior epigastric vessels**
- These vessels supply the cremaster muscle and can be divided to expose the floor of the inguinal canal during hernia repair without damaging the testis

Table 9-6. the Spermatic Cord and Its Covering

| |
|---|
| Three fasciae: |
| External spermatic (from external oblique fascia) |
| Cremasteric (from internal oblique muscle and fascia) |
| Internal spermatic (from transversalis fascia) |
| Three arteries: |
| Testicular artery |
| Cremasteric artery |
| Deferential artery |
| Three veins: |
| Pampiniform plexus and testicular vein |
| Cremasteric vein |
| Deferential vein |
| Three nerves: |
| Genital branch of genitofemoral nerve |
| Ilioinguinal nerve |
| Sympathetic nerves (testicular plexus) |
| Lymphatics |

The inguinal canal

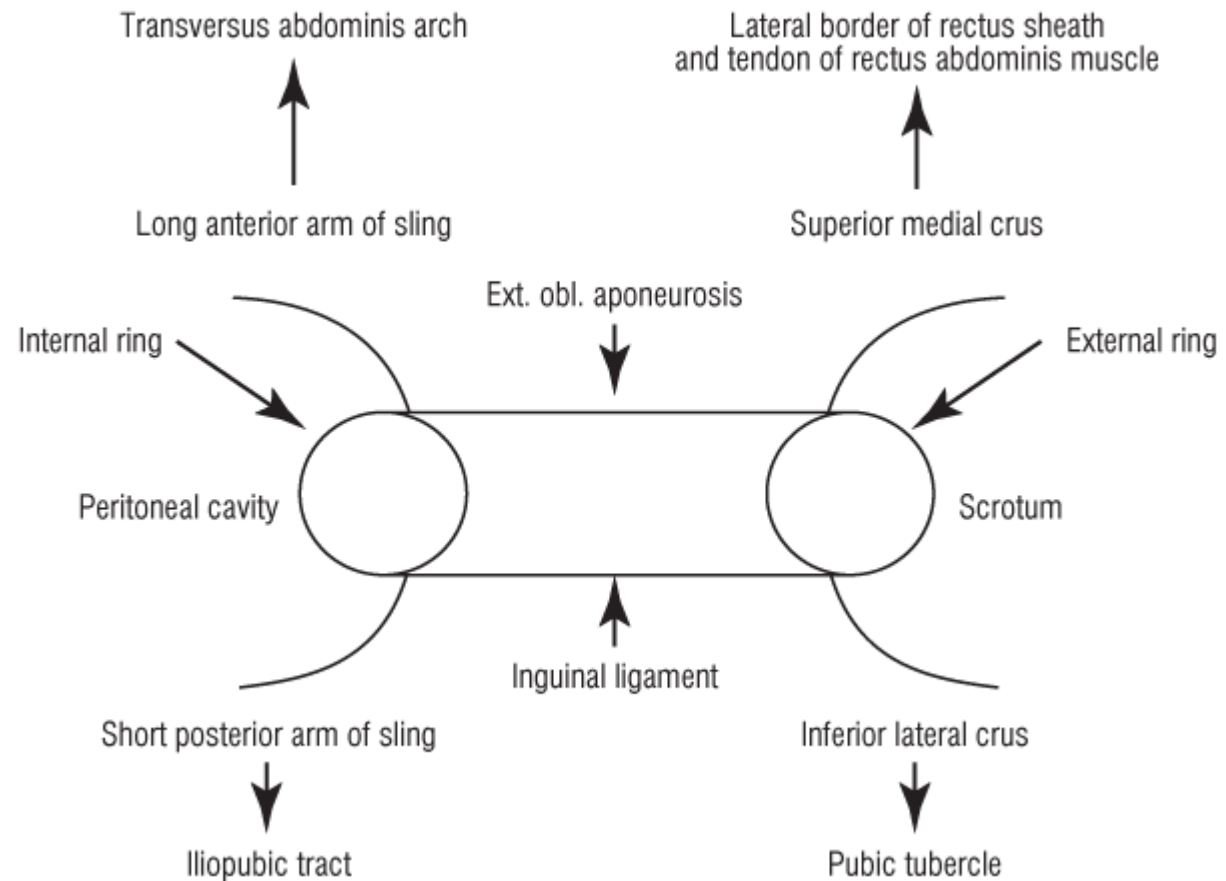
The anterior wall is formed by the **external oblique aponeurosis**

The cephalad wall of the inguinal canal is formed by the **internal oblique and transversus abdominis musculoaponeuroses**

The inferior wall of the inguinal canal is formed by the **inguinal ligament** and **lacunar ligament**

The posterior wall, or floor of the inguinal canal, is formed by the aponeurosis of the **transversus abdominis muscle** and **transversalis fascia**

Highly diagrammatic representation of the **inguinal canal**, presenting only the anterior and inferior formations and the internal and external rings

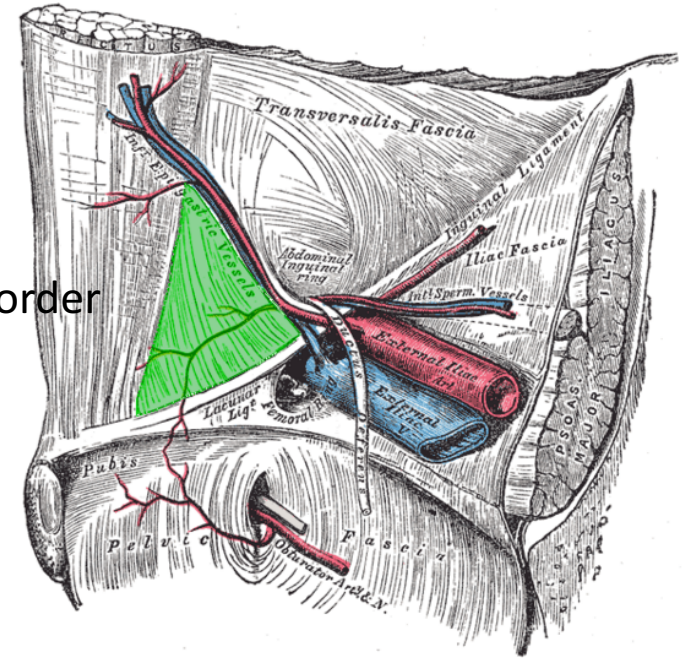


Hesselbach's triangle

It is the margins of the floor of the inguinal canal

The inferior epigastric vessels serve as its superolateral border

The rectus sheath is the medial border

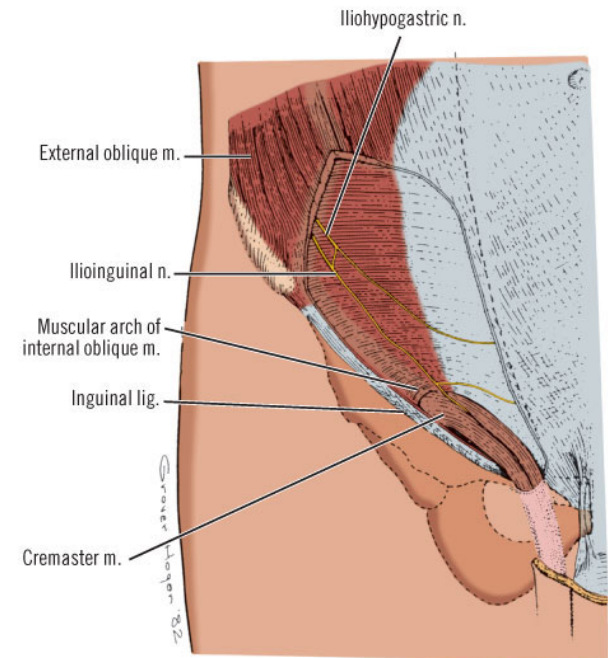


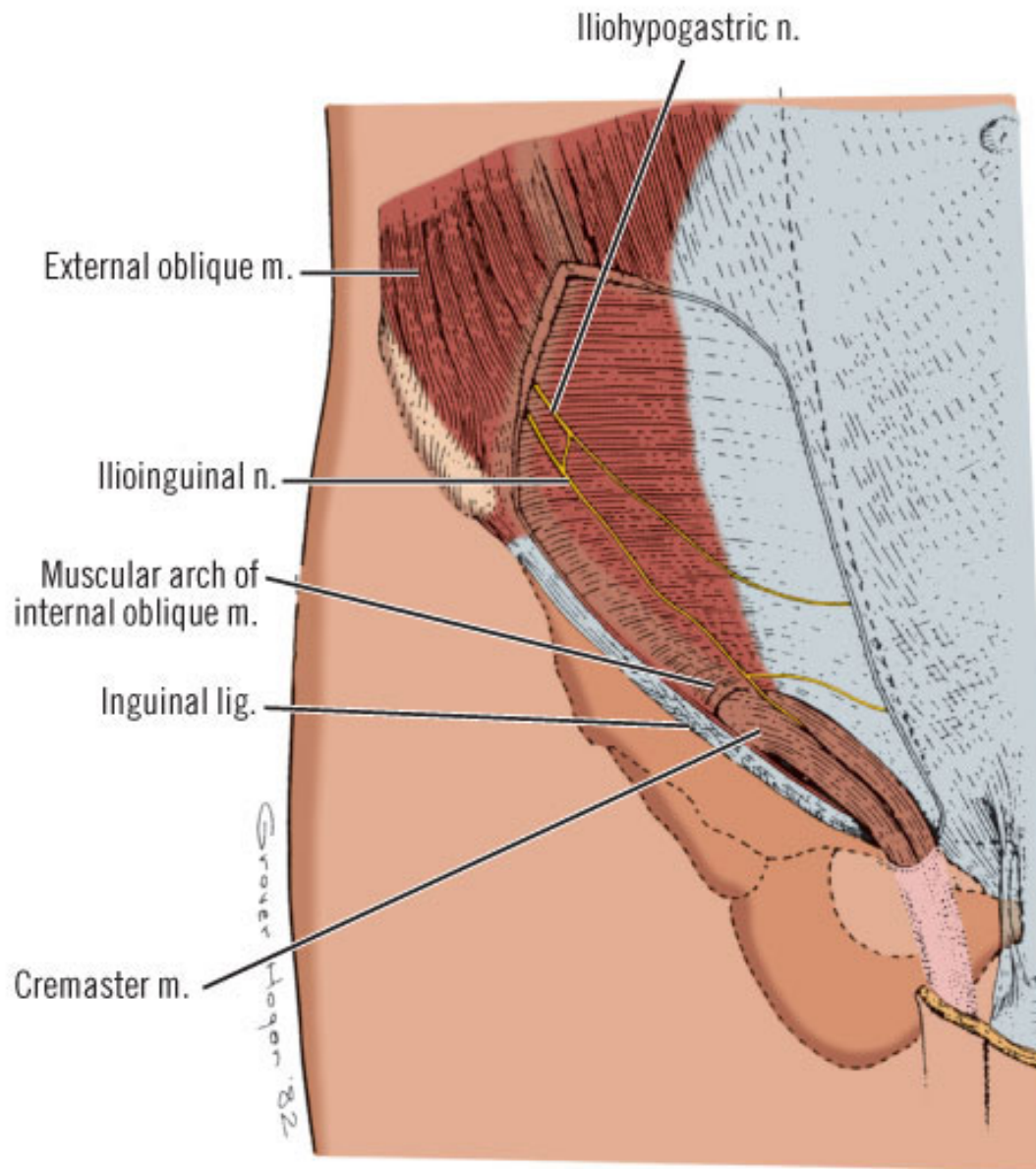
The inguinal ligament and pectineal ligament are the inferior border

Direct hernias occur within Hesselbach's triangle, whereas **indirect inguinal hernias arise lateral to the triangle**

Iliohypogastric and ilioinguinal nerves and genital branch of the genitofemoral nerve

- The **iliohypogastric and ilioinguinal** nerves provide **sensation to the skin of the groin, base of the penis, and ipsilateral upper medial thigh**
- The **iliohypogastric and ilioinguinal nerves** lie beneath the internal oblique muscle to a point just medial and superior to the anterior superior iliac spine, where they penetrate the internal oblique muscle and course beneath the external oblique aponeurosis



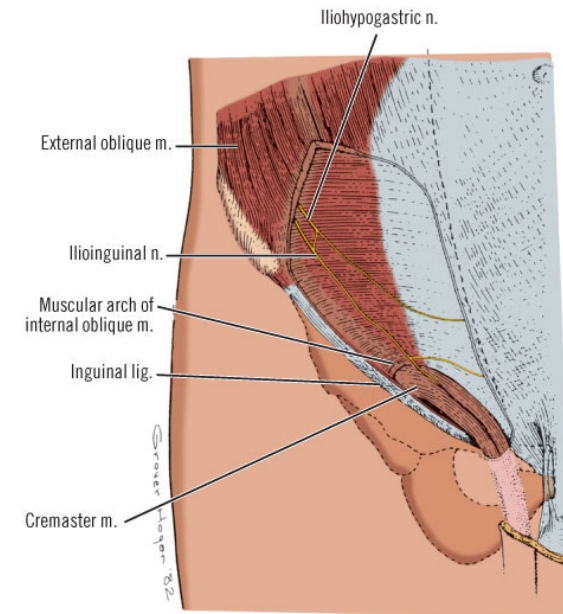


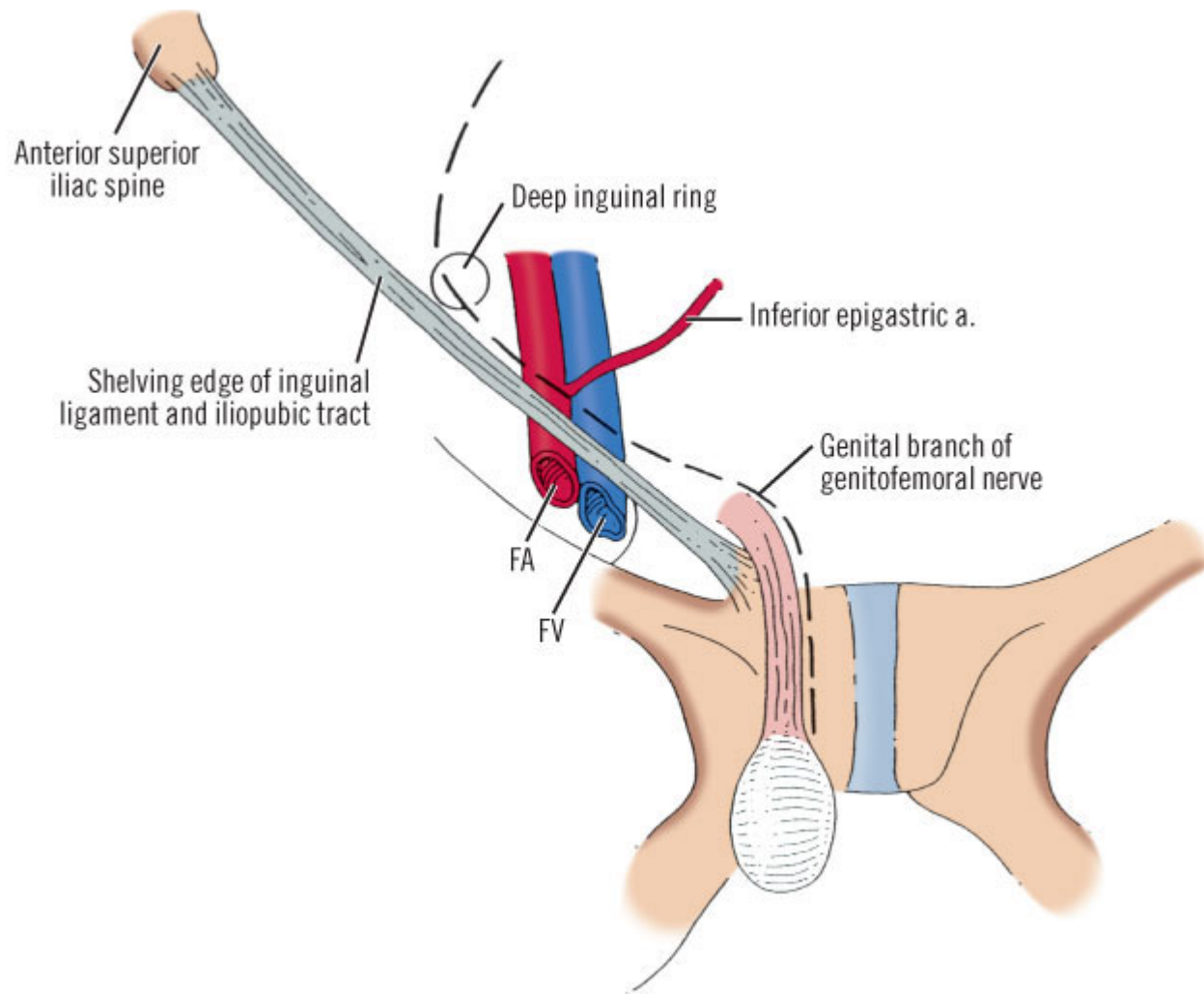
The iliohypogastric nerve runs on the anterior surface of the **internal oblique muscle and aponeurosis** medial and superior to the internal ring

- The **iliohypogastric nerve** may provide an **inguinal branch** that joins the ilioinguinal nerve

The ilioinguinal nerve runs **anterior to the spermatic cord** in the inguinal canal and **branches at the superficial inguinal ring.**

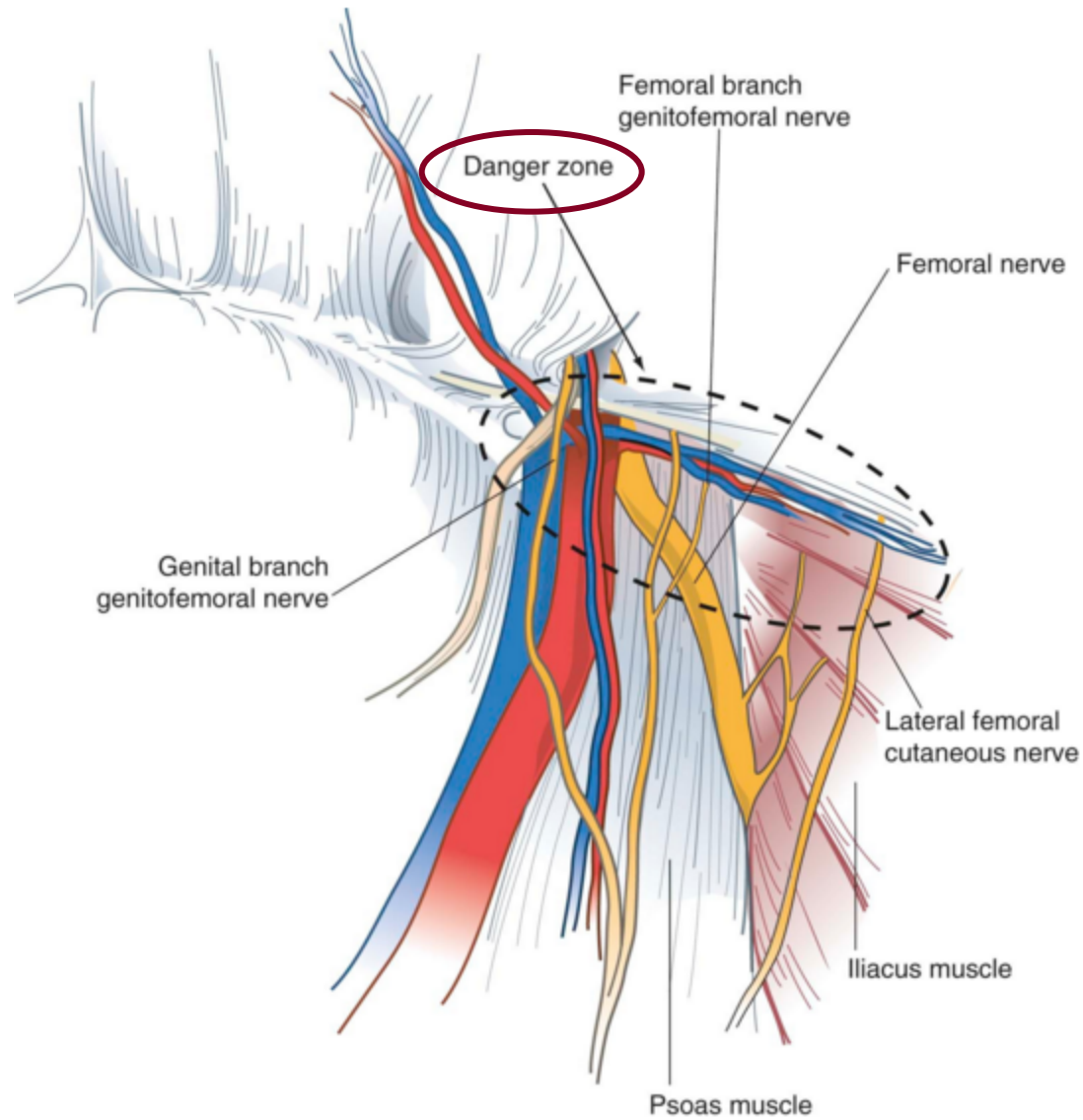
The genital branch of the genitofemoral nerve innervates the cremaster muscle and skin on the lateral side of the scrotum and labia. This nerve lies on the iliopubic tract





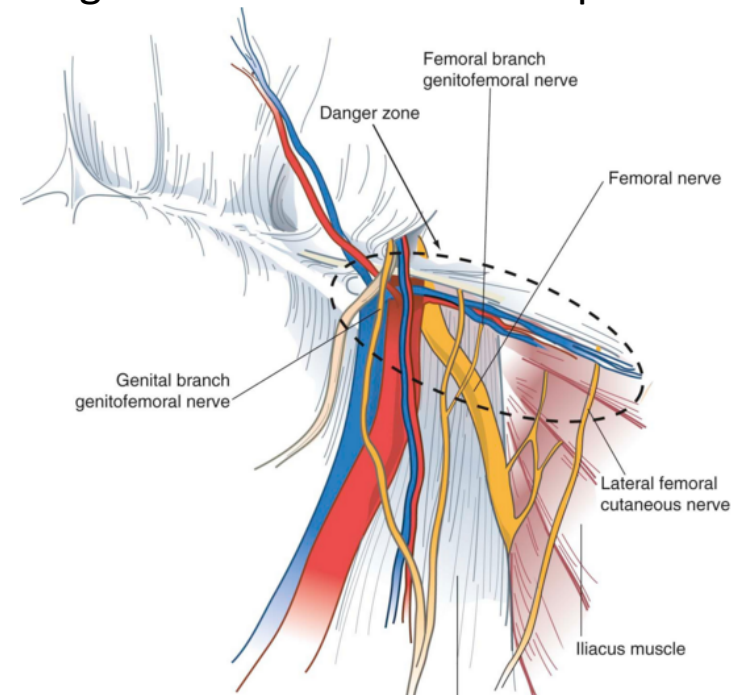
Pathway of **genital branch of genitofemoral nerve** from deep inguinal ring to medial side of spermatic cord (highly diagrammatic)

Danger zone



Preperitoneal Space

- It contains adipose tissue, lymphatics, blood vessels, and nerves such as **the lateral femoral cutaneous nerve** and **genitofemoral nerve**
- **The lateral femoral cutaneous nerve** originates as a root of L2 and L3 and is occasionally a direct branch of the femoral nerve. This nerve courses along the anterior surface of the iliac muscle beneath the iliac fascia and passes under or through the lateral attachment of the inguinal ligament at the anterior superior iliac spine.



The genitofemoral nerve

- It arises from the L2 or L1-L2 nerve roots
- It divides into **genital and femoral branches** on the anterior surface of the psoas muscle
- **The genital branch** enters the inguinal canal through the deep ring, whereas the **femoral branch** enters the femoral sheath lateral to the artery

The inferior epigastric artery and vein

- branches of the **external iliac vessels** and are important landmarks for laparoscopic hernia repair
- These course medial to the internal inguinal ring and eventually lie beneath the rectus abdominis muscle, immediately superficial to the transversalis fascia
- **The inferior epigastric vessels serve to define the types of inguinal hernia: Indirect inguinal hernias** occur lateral to the inferior epigastric vessels, whereas **direct hernias** occur medial to these vessels

The deep circumflex iliac artery and vein

- They are located **below the lateral portion of the iliopubic tract** in the preperitoneal space
- These vessels are branches of the inferior epigastric or external iliac artery and vein. **It is important to dissect only above the iliopubic tract during a laparoscopic hernia repair to avoid injury to these vessels**

The vas deferens

- courses through the preperitoneal space from caudad to cephalad and medial to lateral to join the spermatic cord at the deep inguinal ring

Femoral canal

- The boundaries of the femoral canal are the
 - **Iliopubic tract anteriorly**
 - **Cooper's ligament posteriorly**
 - **Femoral vein laterally**
- **The pubic tubercle forms the apex of the femoral canal triangle.** This canal usually contains connective tissue and lymphatic tissue. **A femoral hernia is medial to the femoral vessels**

DIAGNOSIS

- **A bulge** in the inguinal region is the main diagnostic finding in most groin hernias
- There may be associated **pain or vague discomfort** in the region, but groin hernias are usually not extremely painful unless incarceration or strangulation has occurred
- Occasionally **paresthesias** related to compression or irritation of the inguinal nerves by the hernia

Differential Diagnosis of Groin and Scrotal Masses

DIAGNOSIS

- The inguinal region: patient in the **supine and standing positions**
- The examiner **visually inspects and palpates** the inguinal region, looking for **asymmetry, bulges, or a mass**
- Having the patient cough or perform a **Valsalva maneuver** can facilitate identification of a hernia
- A **fingertip is placed into the external inguinal ring** by invaginating the scrotum to detect a small hernia. A bulge moving lateral to medial in the inguinal canal suggests an indirect hernia. If a bulge progresses from deep to superficial through the inguinal floor, a direct hernia is suspected
- A **bulge identified below the inguinal ligament is consistent with a femoral hernia.**

DIAGNOSI

- **Ultrasonography** also can aid in the diagnosis
- **High degree of sensitivity and specificity for ultrasound** in the detection of occult direct, indirect, and femoral hernias
- **Computed tomography (CT)** of the abdomen and pelvis may be useful for the diagnosis of **obscure and unusual hernias as well as atypical groin masses**

CLASSIFICATION

BOX 46-3

Nyhus Classification of Groin Hernia

TREATMENT

- **The natural history of a groin hernia is that of progressive enlargement and weakening, with a small potential for incarceration and strangulation**
- A strategy of **watchful waiting** is safe for older patients with asymptomatic or minimally symptomatic inguinal hernias
- Trusses:
 - Correct measurement and fitting are important. Hernia control has been reported in about 30% of patients. Complications associated with the use of a truss include testicular atrophy, ilioinguinal or femoral neuritis, and hernia incarceration
- Nonoperative management is not used for femoral hernias because of the high incidence of associated complications, particularly strangulation

--- BASICALLY, HERNIAS NEED SURGICAL TREATMENT ---

OPERATIVE REPAIRS

- **Tension-free repairs** are now standard and there are a variety of different types.
- Older tissue types of repair are rarely indicated, except for patients with simultaneous **contamination or concomitant bowel resection**, when placement of a mesh prosthesis may be contraindicated
- **Incision:** linear or slightly curvilinear incision above the inguinal ligament and a fingerbreadth below the internal inguinal ring
- The **internal inguinal ring** is located at the midpoint between the *anterior superior iliac spine* and *ipsilateral pubic tubercle*

- Dissection is continued through the subcutaneous tissues and Scarpa's fascia. The **external oblique fascia and external inguinal ring are identified**. The **external oblique fascia is incised** through the superficial inguinal ring to expose the inguinal canal
- The **genital branch of the genitofemoral nerve, as well as the ilioinguinal and iliohypogastric nerves**, are identified and avoided or mobilized to prevent transection and entrapment.
- The **spermatic cord is mobilized** at the pubic tubercle by a combination of blunt and sharp dissection
- **Hernia sac should be isolated and reduced in the abdomen**

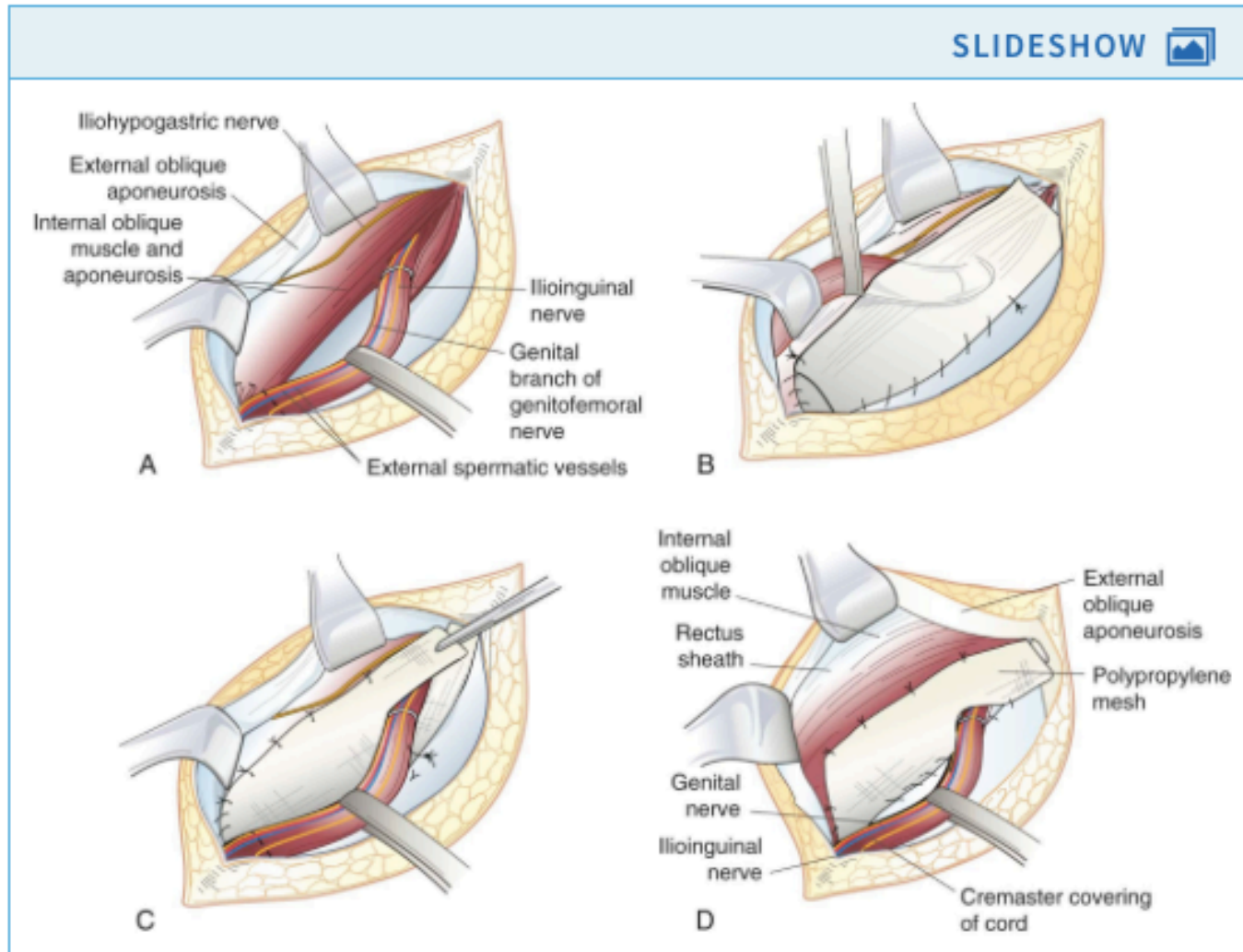
TISSUE REPAIR

Bassini, Shouldice, and McVay repairs

FIG 46.5

Tension-Free Anterior Inguinal Hernia Repair

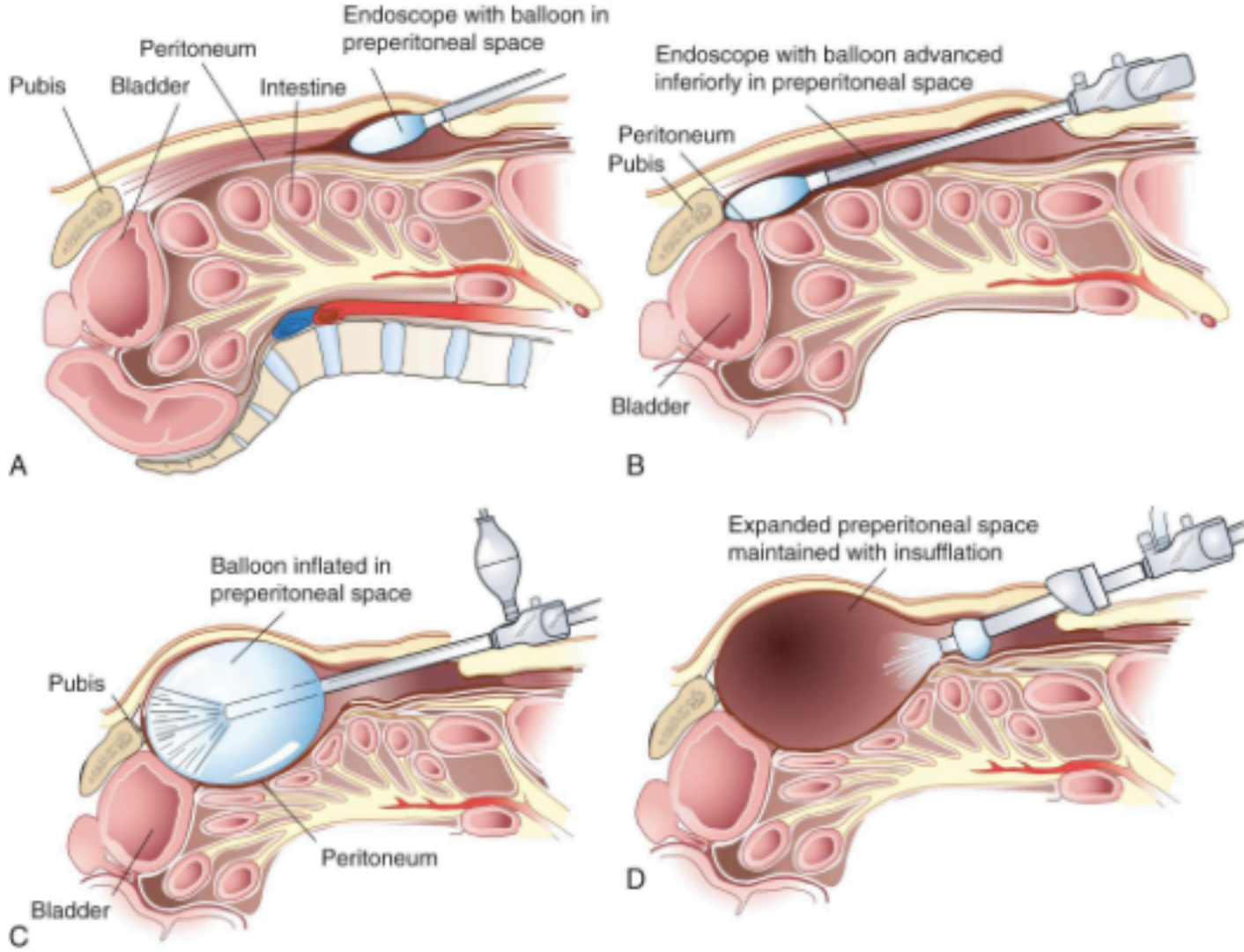
The tension-free repair = **Lichtenstein repair**: a piece of prosthetic nonabsorbable mesh is fashioned to fit the canal

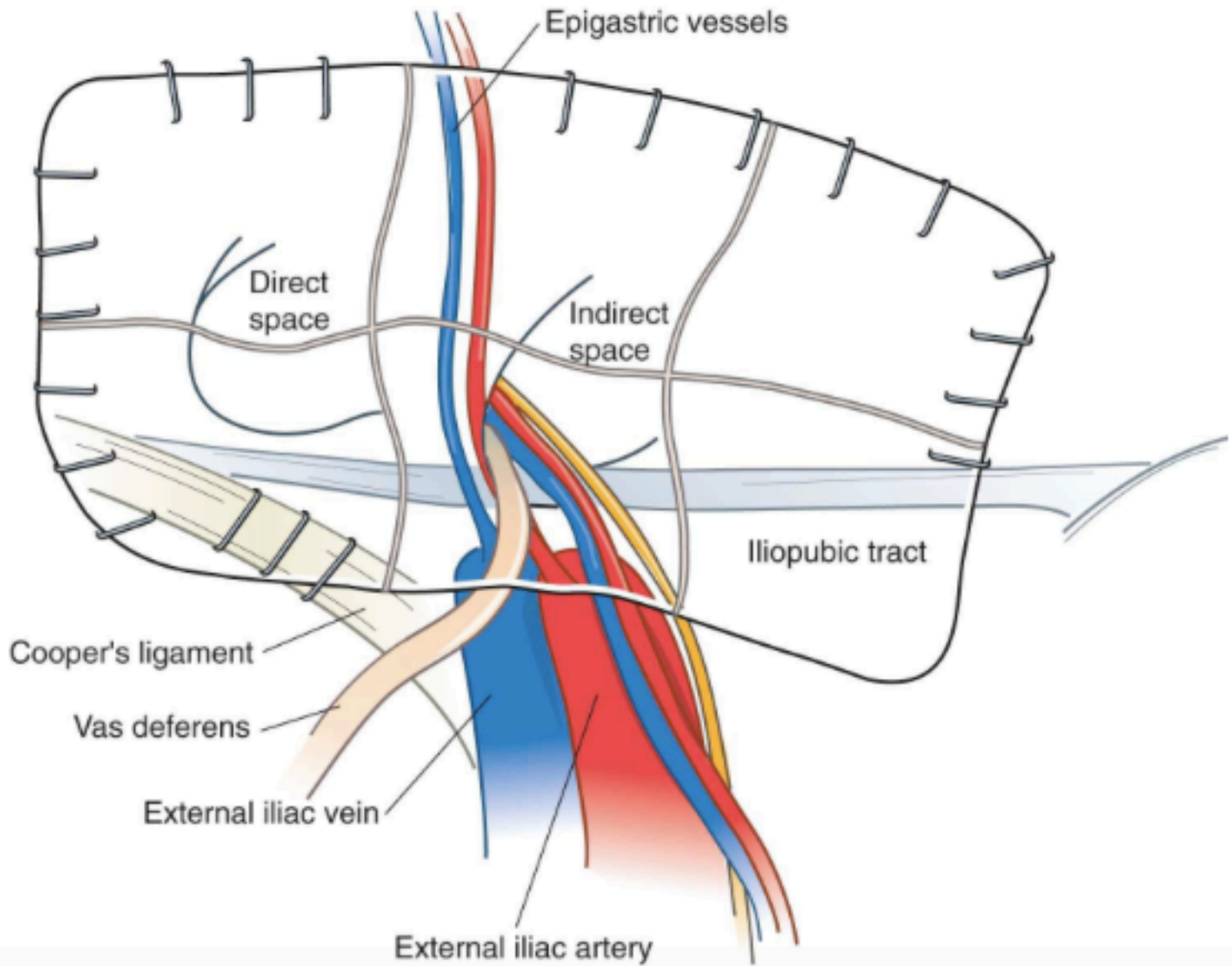


- This so-called **plug and patch repair**, an extension of Lichtenstein's original mesh repair, has now become the most commonly performed primary anterior inguinal hernia repair
- **The Stoppa-Rives repair**. It is particularly useful for large, recurrent, or bilateral hernias

LAPAROSCOPIC REPAIR

- Laparoscopic inguinal hernia repair is another method of **tension-free mesh repair**, based on a **preperitoneal approach**
- advantage of placing a **large piece of mesh behind the defect covering the myopectineal orifice**
- less pain, better visualization of anatomy, usefulness for fixing all inguinal hernia defects, and decreased surgical site infections
- longer operative times, technical challenges, risk of recurrence, and increased cost
- **advantages for patients with bilateral or recurrent hernias**
- totally extraperitoneal (**TEP**) and transabdominal preperitoneal (**TAPP**) approach. With the TAPP repair, the preperitoneal space is accessed after initially entering the peritoneal cavity





- **Tacks are not placed inferior to the iliopubic tract beyond the external iliac artery. Staples placed in this area may injure the femoral branch of the genitofemoral nerve or lateral femoral cutaneous nerve**
- Staples are also avoided in the so-called **triangle of doom**, bounded by the **ductus deferens medially** and **spermatic vessels laterally**, to avoid injury to the **external iliac vessels and femoral nerve.**
- As long as one can palpate the tip of the tacking device, these structures are not likely to be injured

RESULTS OF HERNIA REPAIR

- **Hernia recurrence** ranges from **1.7% to 10%**
- Tension-free repairs have a lower rate of recurrence than tissue repairs
- **50%** of recurrences are found **within 3 years** after primary repair
- **Laparoscopic repair** resulted in a more rapid return to normal activity and decreased persistent postoperative pain.
- **Open and laparoscopic mesh repairs had similar recurrence rates**

FEMORAL HERNIA

Femoral canal is bounded superiorly by the **iliopubic tract**, inferiorly by **Cooper's ligament**, laterally by the **femoral vein**, and medially by the junction of the **iliopubic tract and Cooper's ligament (lacunar ligament)**

Mass or bulge below the inguinal ligament

50% of **men with a femoral hernia** will have an associated direct inguinal hernia, whereas this relationship occurs in only 2% of women

It can be repaired using the **standard Cooper's ligament repair**, a **preperitoneal approach**, or a **laparoscopic approach**

- approximation of the iliopubic tract to Cooper's ligament or by placement of prosthetic mesh to obliterate the defect

- The incidence of **strangulation** in femoral hernias is high; therefore, all femoral hernias should be repaired
- When the incarcerated contents of a femoral hernia cannot be reduced, **dividing the lacunar ligament** can be helpful
- The occurrence of a femoral hernia after repair of an inguinal hernia has been reported to be 15 times the normal expected rate
- **Recurrence of femoral hernia after operation is only 2%**
- **Recurrent femoral hernia repairs have a rerecurrence rate of about 10%**

Sliding Hernia

A sliding hernia occurs when an internal organ comprises a portion of the wall of the hernia sac.

The most common viscus involved is the colon or urinary bladder.

Most sliding hernias are a variant of indirect inguinal hernias, although femoral and direct sliding hernias can occur.

The primary danger associated with a sliding hernia is the failure to recognize the visceral component of the hernia sac before injury to the bowel or bladder.

The sliding hernia contents are reduced into the peritoneal cavity, and any excess hernia sac is ligated and divided.

After reduction of the hernia, one of the techniques described earlier can be used for repair of the inguinal hernia.

Recurrent Hernia

The repair of recurrent inguinal hernias is challenging, and results are associated with a **higher incidence of secondary recurrence**. Recurrent hernias almost always require placement of prosthetic mesh for successful repair. Recurrences after anterior hernia repair using mesh are best managed by a laparoscopic or open posterior approach, with placement of a second prosthesis

Strangulated Hernia

Repair of a suspected strangulated hernia is most easily done using a preperitoneal approach. With this exposure, the hernia sac contents can be directly visualized and their **viability** assessed through a single incision. The constricting ring is identified and can be incised to reduce the entrapped viscus with minimal danger to the surrounding organs, blood vessels, and nerves. **If it is necessary to resect strangulated intestine**, the peritoneum can be opened and resection done without the need for a second incision.

Bilateral Hernias

- Simultaneous repair of bilateral hernias has a similar recurrence rate to unilateral repair, regardless of whether the open or laparoscopic technique is used

Complications

- Although the overall complication rate from hernia repair has been estimated to be approximately 10%, many of these complications are transient and can be easily addressed

Surgical Site Infection

- The risk for surgical site (wound) infection is **1% to 2% after open inguinal hernia repair** and less with laparoscopic repairs
- **These are clean operations**, and the risk for infection is primarily influenced by associated patient diseases
- **Not supported** the routine use of perioperative antimicrobial prophylaxis for inguinal hernia repair
- **Patients who have significant underlying disease, i.e. ASA3 score or more, receive perioperative antimicrobial prophylaxis with cefazolin, 1 to 2 g, given IV 30 to 60 minutes before the incision**
- **Clindamycin, 600 mg IV, can be used for patients allergic to penicillin**
- The placement of prosthetic mesh does not increase the risk for infection and does not affect the need for prophylaxis

Nerve Injuries and Chronic Pain Syndromes

- **Infrequent and underrecognized** complication of inguinal hernia repair
- Injury: traction, electrocautery, transection, and entrapment. The use of prosthetic mesh can result in dysesthesias, which are usually temporary
- The nerves most commonly affected during **open hernia repair** are the **ilioinguinal, genital branch of the genitofemoral, and iliohypogastric nerves**
- **During laparoscopic repair, the lateral femoral cutaneous and genitofemoral nerves** are most often affected
- **Transient neuralgias** can occur and are usually **self-limited** and resolve within a few weeks after surgery
- **Persistent neuralgias** usually result in **pain and hyperesthesia** in the area of distribution. Symptoms are often reproduced by palpation over the point of entrapment or hyperextension of the hip and **may be relieved by flexion of the thigh**

- **Transection of a sensory nerve** usually results in an area of numbness corresponding to the distribution of the involved nerve
- **Pain rates range from 29% to 76%**
- Strategies of routine nerve division in open surgery have not been associated with a reduction in chronic pain in mesh-based anterior repairs
- In contrast, routine ilioinguinal nerve division is associated with significantly more sensory disturbances
- Laparoscopic repair: significantly lower rates of chronic postoperative inguinal pain

- **Early symptoms are treated with anti-inflammatory agents, analgesics, and local anesthetic nerve blocks**
- **Patients with nerve entrapment syndromes are best treated by repeat exploration with neurectomy and mesh removal** through an anterior approach
- **Laparoscopic nerve injuries are minimized by not placing any tacks or staples below the lateral portion of the iliopubic tract.**
- If nerve entrapment occurs, patients **undergo reoperation** to remove the offending tack or staple

ISCHEMIC ORCHITIS AND TESTICULAR ATROPHY

- **Thrombosis** of the small veins of the pampiniform plexus within the spermatic cord
- This results in **venous congestion of the testis**, which **becomes swollen and tender 2 to 5 days after surgery**
- The process may continue for an additional **6 to 12 weeks** and usually results in **testicular atrophy**
- **Ischemic orchitis** also can be caused by **ligation** of the testicular artery. It is treated **with anti-inflammatory agents and analgesics**. **Orchiectomy is rarely necessary**
- **The incidence of ischemic orchitis can be minimized by avoiding unnecessary dissection within the spermatic cord**. The incidence increases with dissection of the distal portion of a large hernia sac

- **Testicular atrophy is a consequence of ischemic orchitis**
- **It is more common after repair of recurrent hernias**, particularly when an anterior approach is used
- **The incidence of ischemic orchitis increases by a factor of three or four with each subsequent hernia recurrence**

INJURY TO THE VAS DEFERENS AND VISCERA

- Injury to the vas deferens and intra-abdominal viscera is unusual
- Most of these injuries occur **in patients with sliding inguinal hernias** when there is failure to recognize the presence of intra-abdominal viscera in the hernia sac
- **With large hernias, the vas deferens can be displaced in an enlarged inguinal ring before its entry into the spermatic cord**
- In this situation, the vas deferens is identified and protected.

QUALITY OF LIFE

The major quality indicators: **postoperative pain and return to work**

Tension-free and laparoscopic mesh-based approaches have been demonstrated to be **less painful than nonmesh repairs**

Laparoscopic repairs have the least amount of postoperative pain and have been shown to provide a marginal **advantage in reducing time off work.**

VENTRAL HERNIA

- A ventral hernia is defined by a protrusion through the anterior abdominal wall fascia
- **Epigastric hernias** occur from the xyphoid process to the umbilicus, **umbilical hernias** occur at the umbilicus, and **hypogastric hernias** are rare spontaneous hernias that occur below the umbilicus in the midline
- Acquired hernias typically occur after surgical incisions and are therefore termed **incisional hernias**
- Although not a true hernia, **diastasis recti** can present as a midline bulge. In this condition, the linea alba is stretched, resulting in bulging at the medial margins of the rectus muscles. There is no fascial ring or hernia sac and, unless significantly symptomatic, surgical correction is avoided

- **incisional hernias: 15% to 20% of all abdominal wall hernias**
- **umbilical and epigastric hernias constitute 10% of hernias**
- **Patient-related factors** linked to ventral hernia formation include obesity, older age, male gender, sleep apnea, emphysema, and prostatism
- **Wound infection** has been linked to hernia formation
- **Incidence of ventral hernia formation** after various types of abdominal incision : risk is 10.5% for midline, 7.5% for transverse, and 2.5% for paramedian incisions

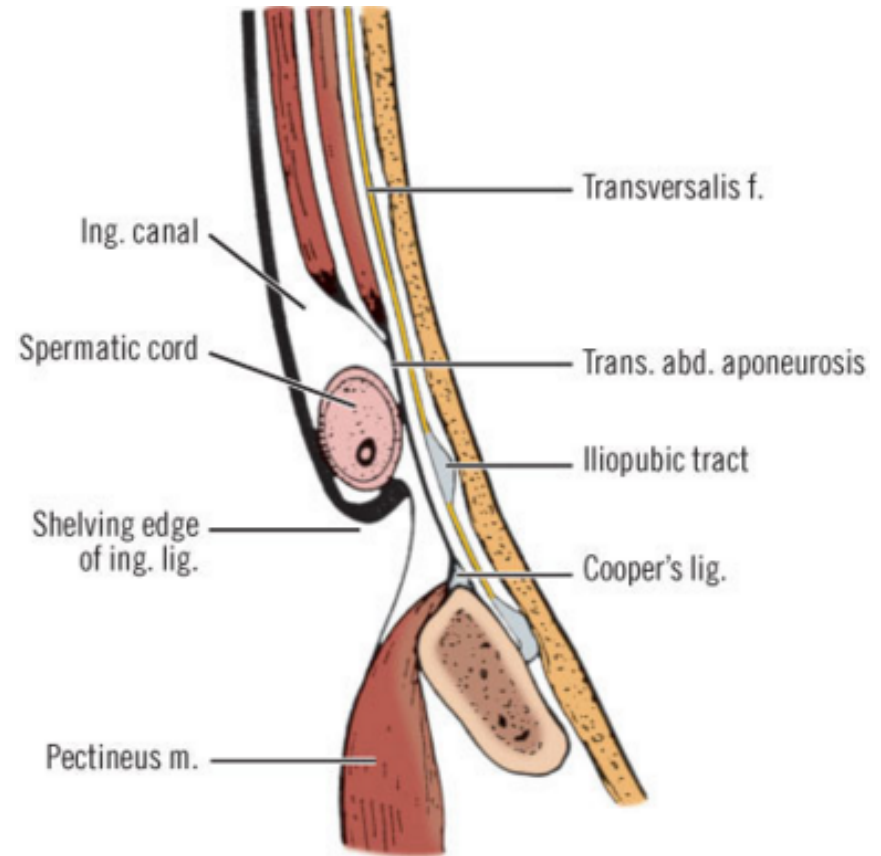
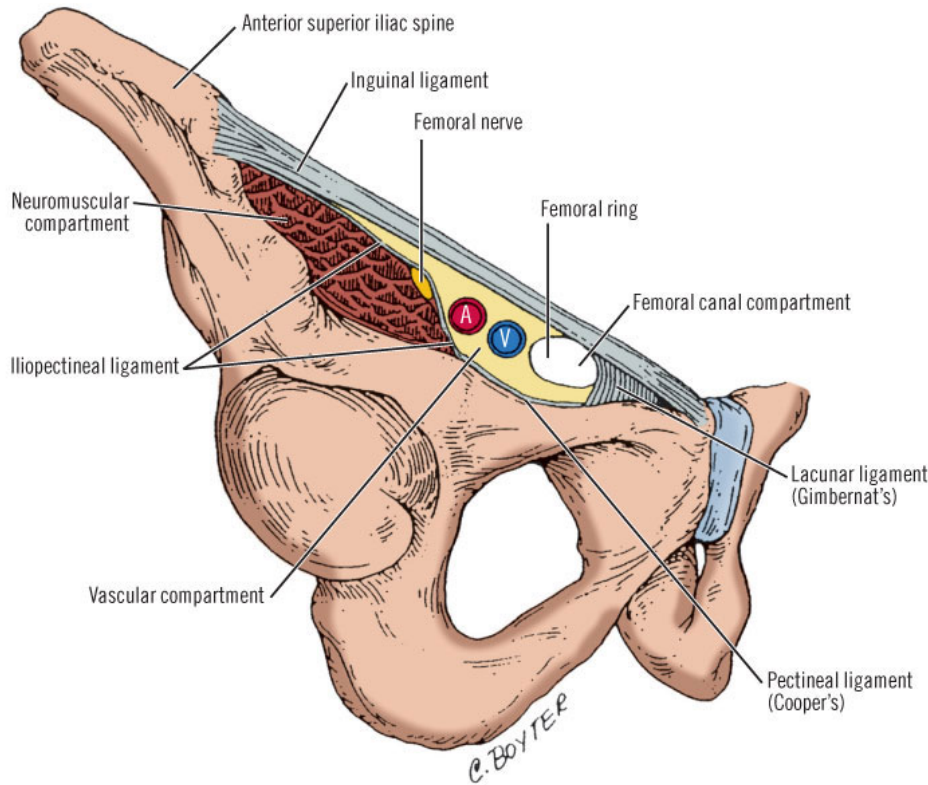


giuseppe.nigri@uniroma1.it









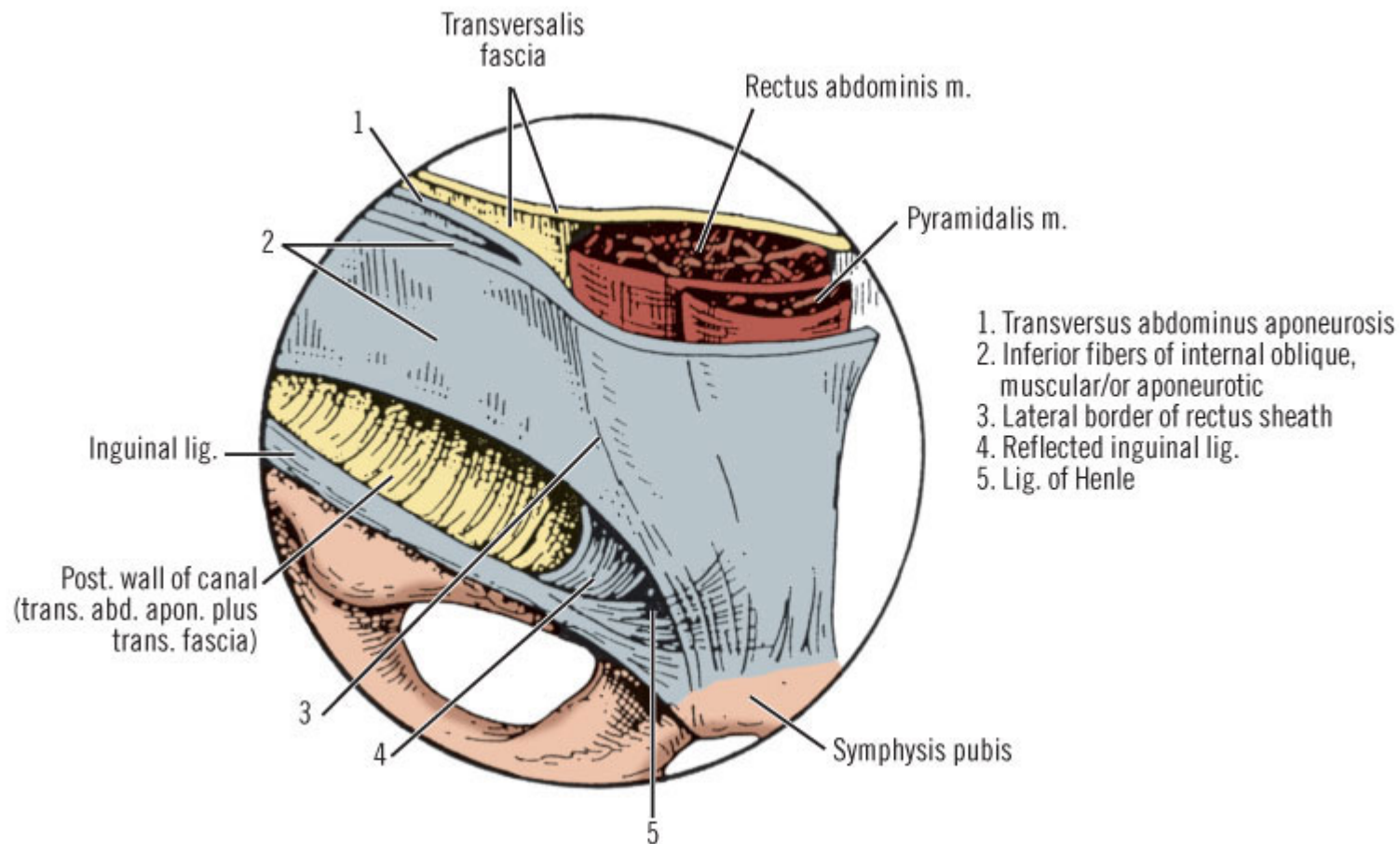
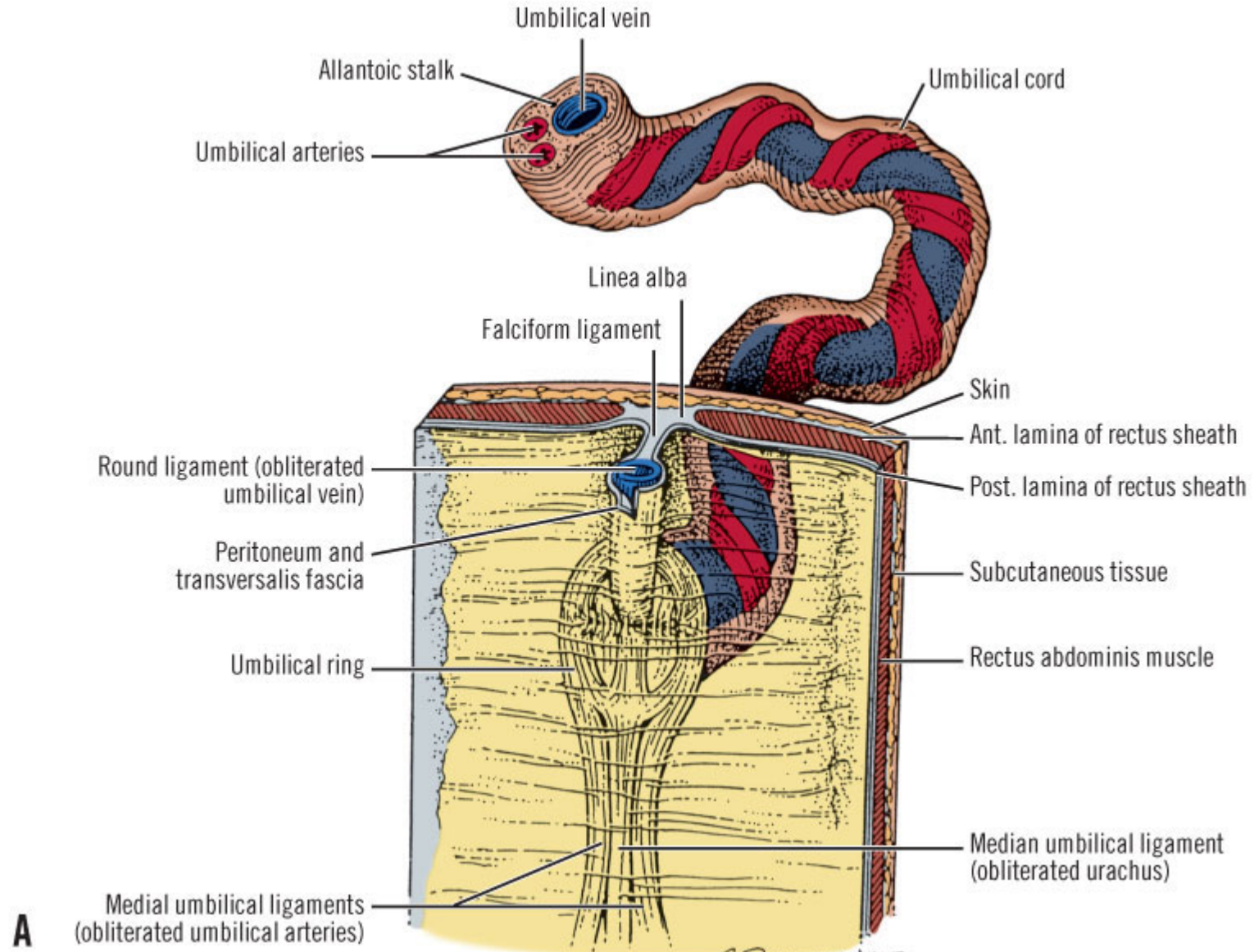
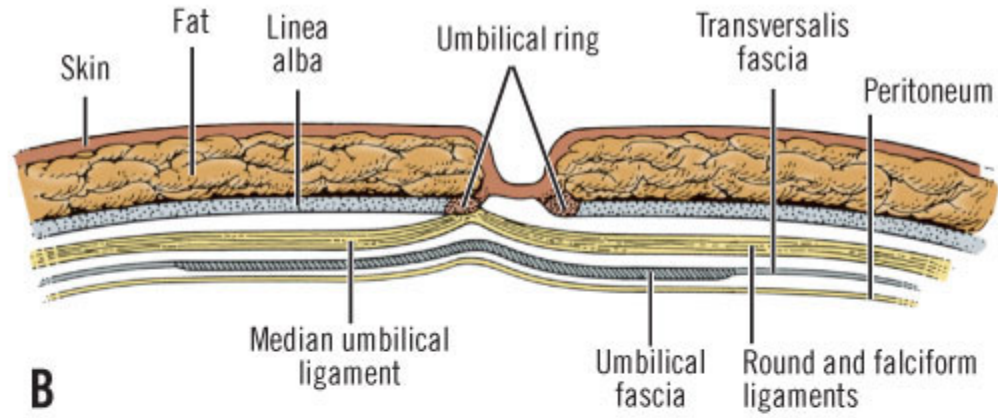


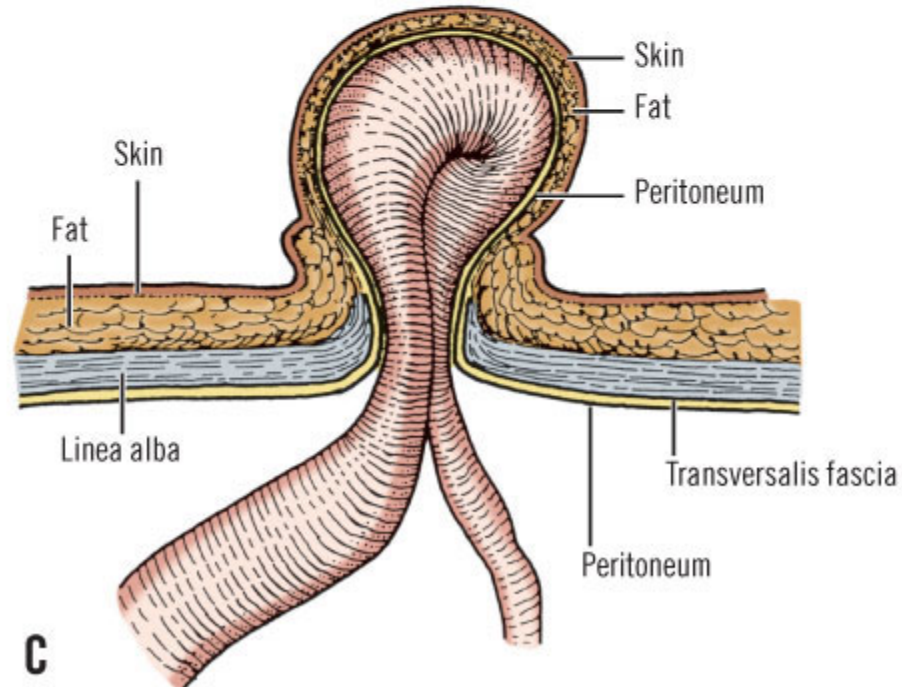
Table 9-6. the Spermatic Cord and Its Covering

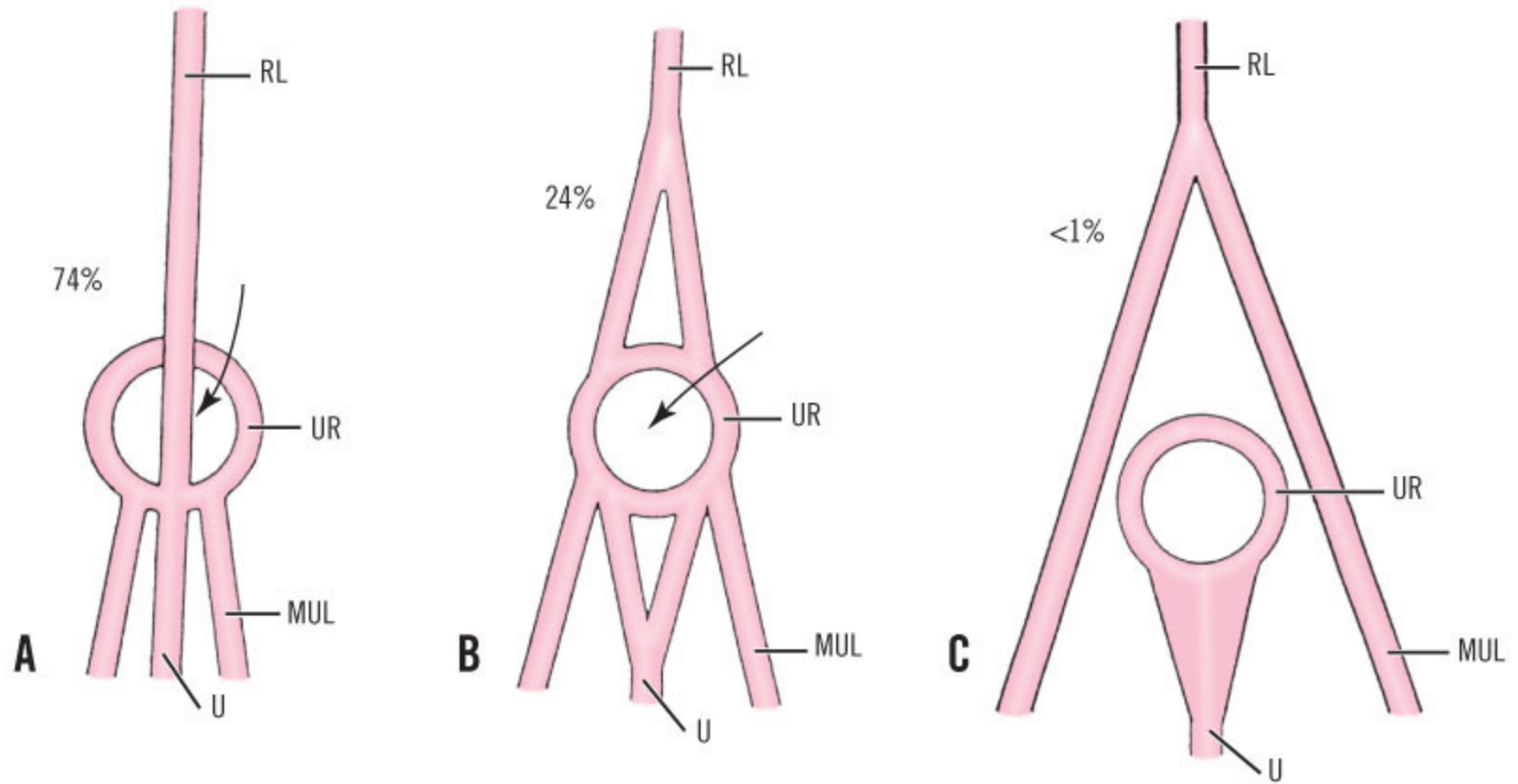
| |
|---|
| Three fasciae: |
| External spermatic (from external oblique fascia) |
| Cremasteric (from internal oblique muscle and fascia) |
| Internal spermatic (from transversalis fascia) |
| Three arteries: |
| Testicular artery |
| Cremasteric artery |
| Deferential artery |
| Three veins: |
| Pampiniform plexus and testicular vein |
| Cremasteric vein |
| Deferential vein |
| Three nerves: |
| Genital branch of genitofemoral nerve |
| Ilioinguinal nerve |
| Sympathetic nerves (testicular plexus) |
| Lymphatics |

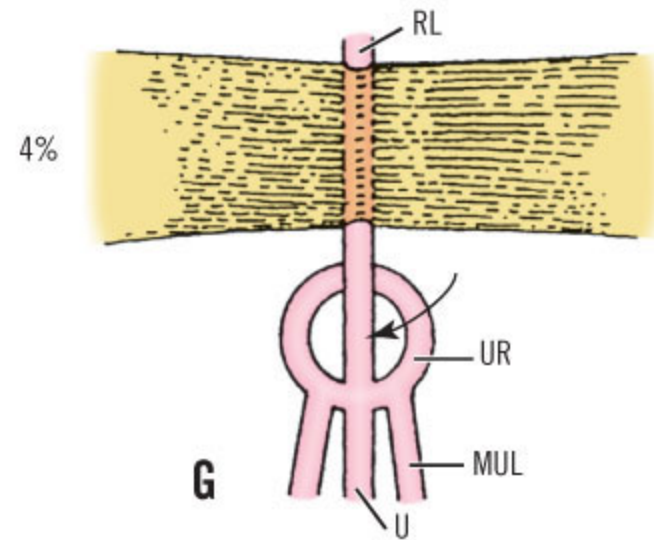
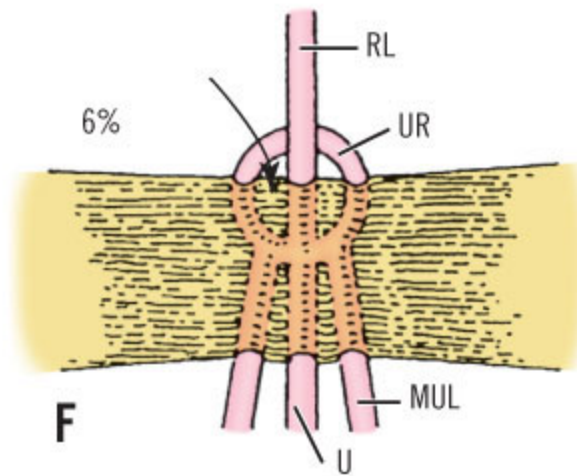
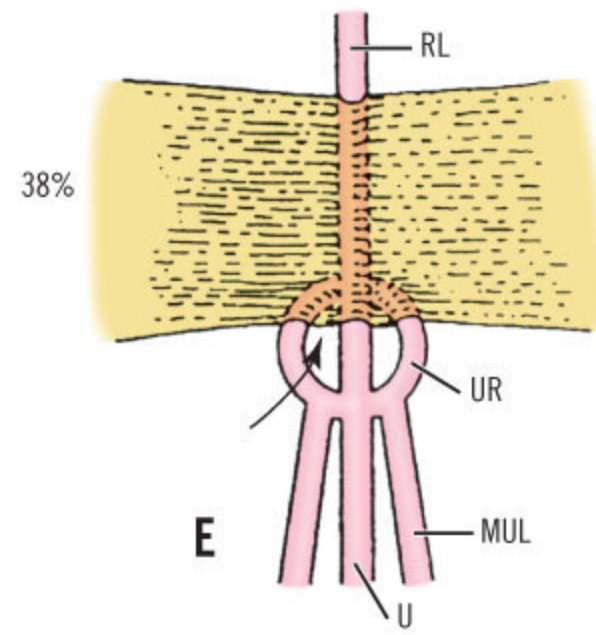
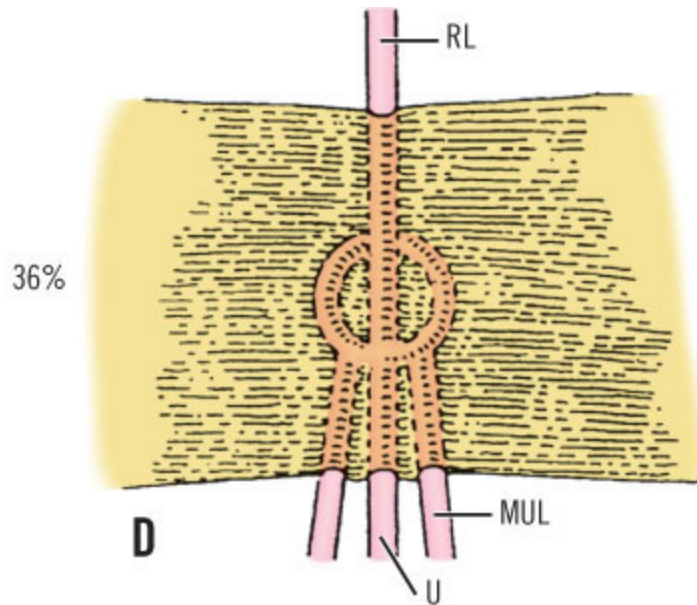


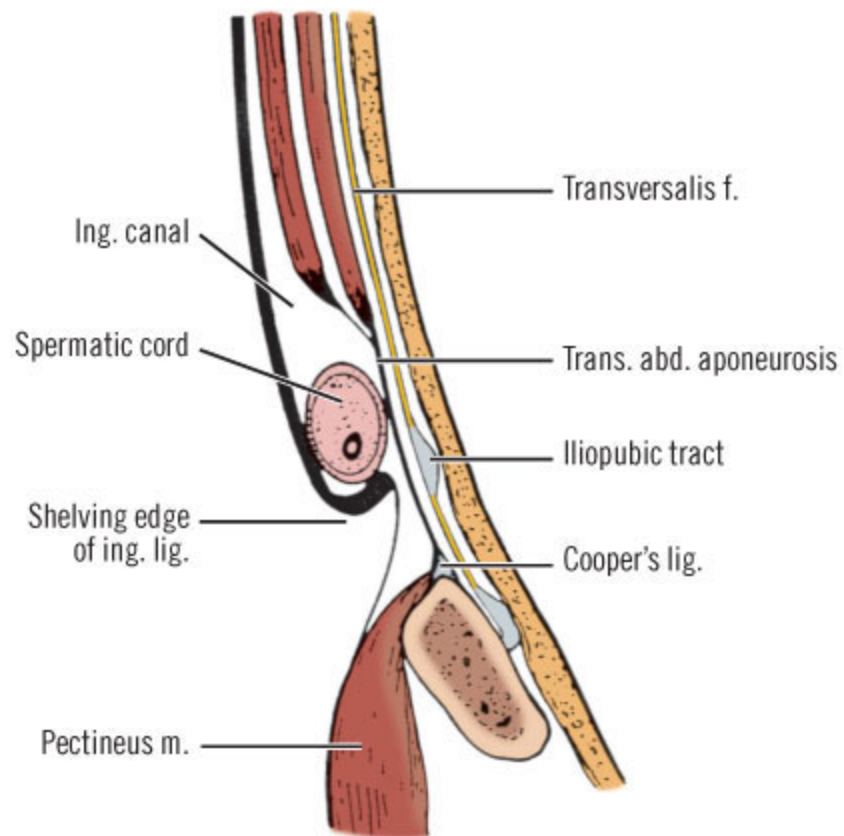


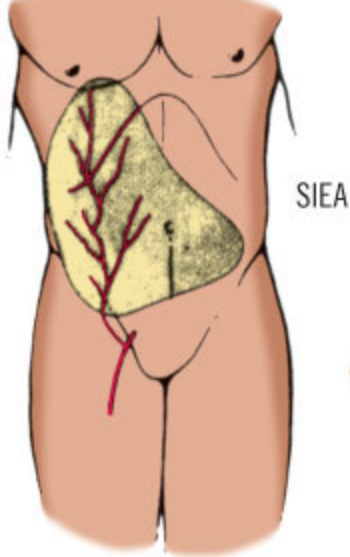
Copyright ©2006 by The McGraw-Hill Companies, Inc.
All rights reserved.



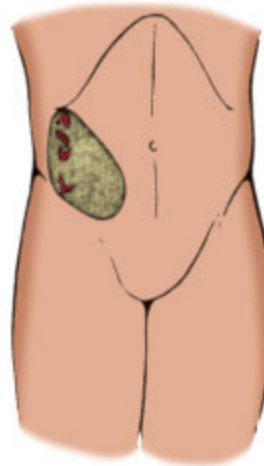




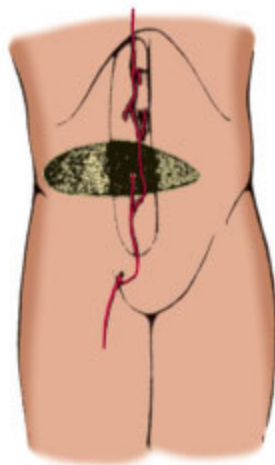




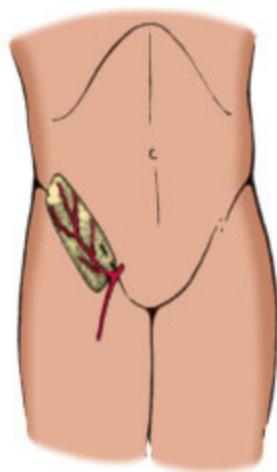
SIEA



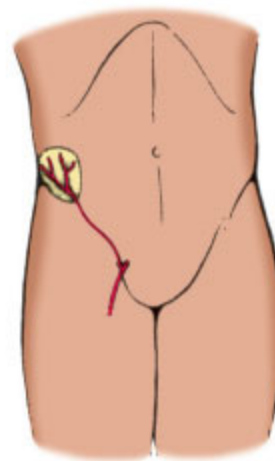
Skin territory of external oblique perforators (EOP)



Skin territories of vertically and horizontally oriented flaps of deep epigastric system



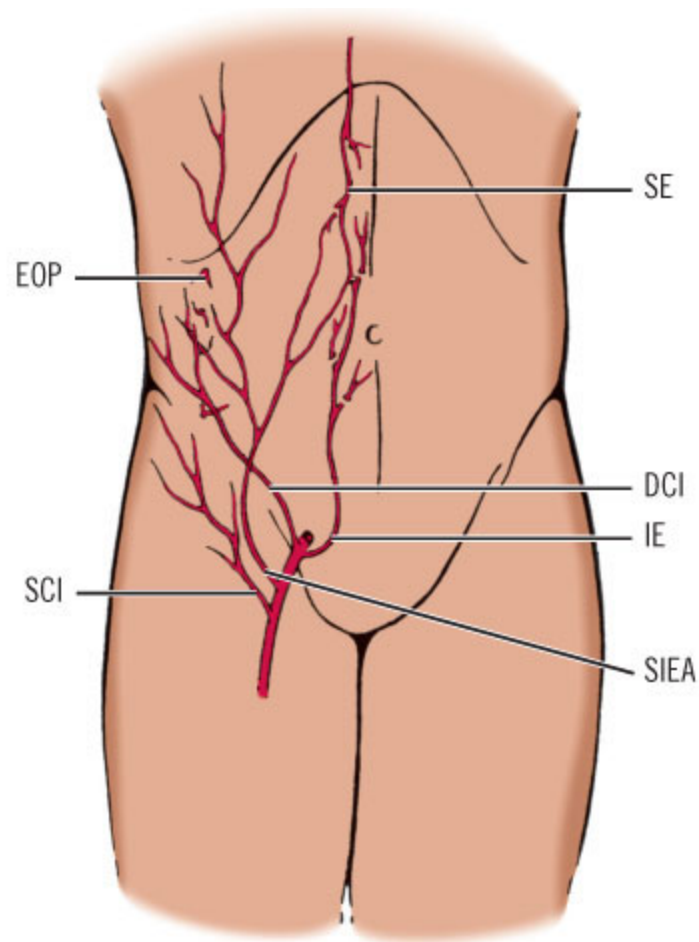
Skin territory of superficial circumflex iliac system (SCI)

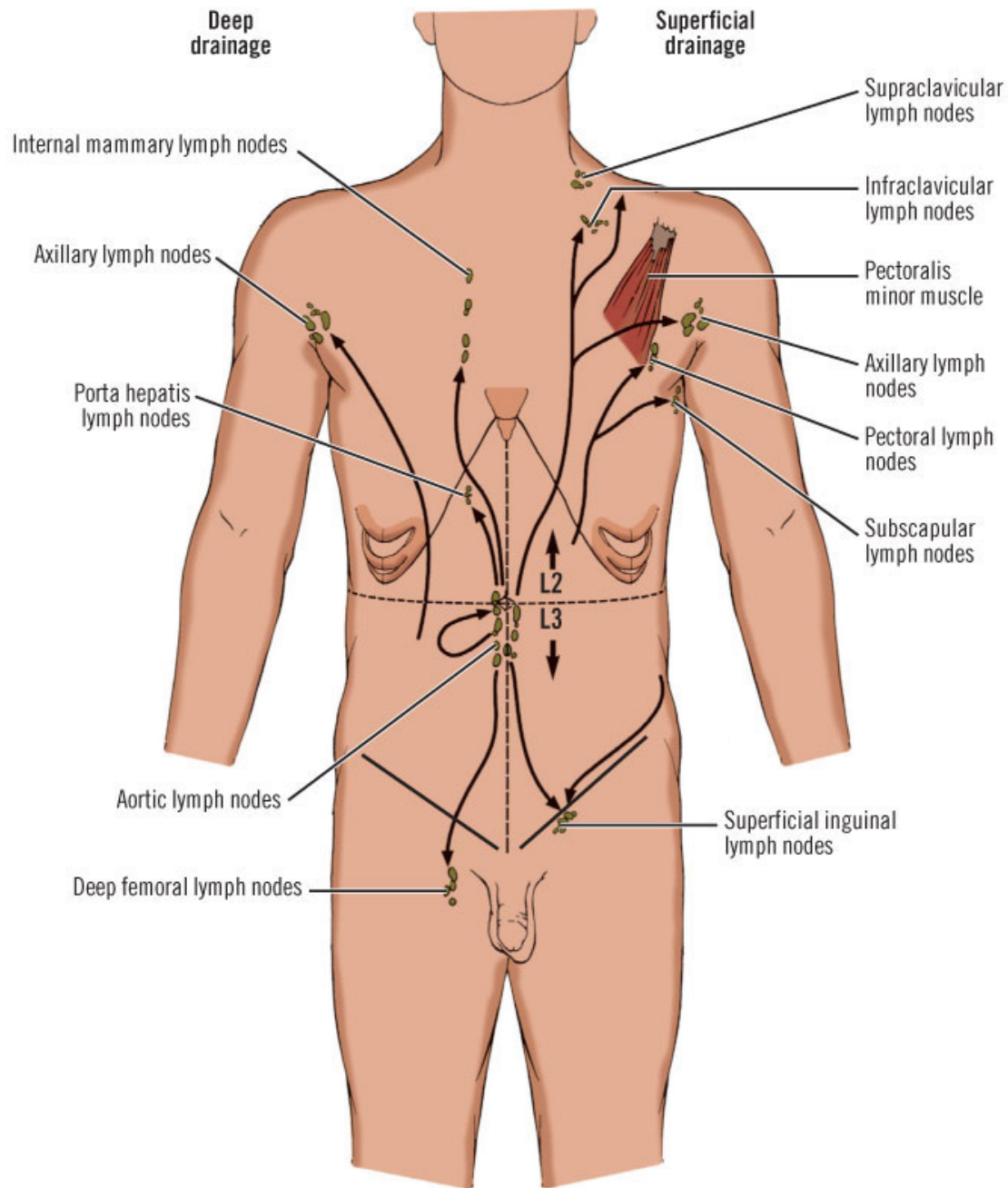


Skin territory of deep circumflex iliac system (DCI)

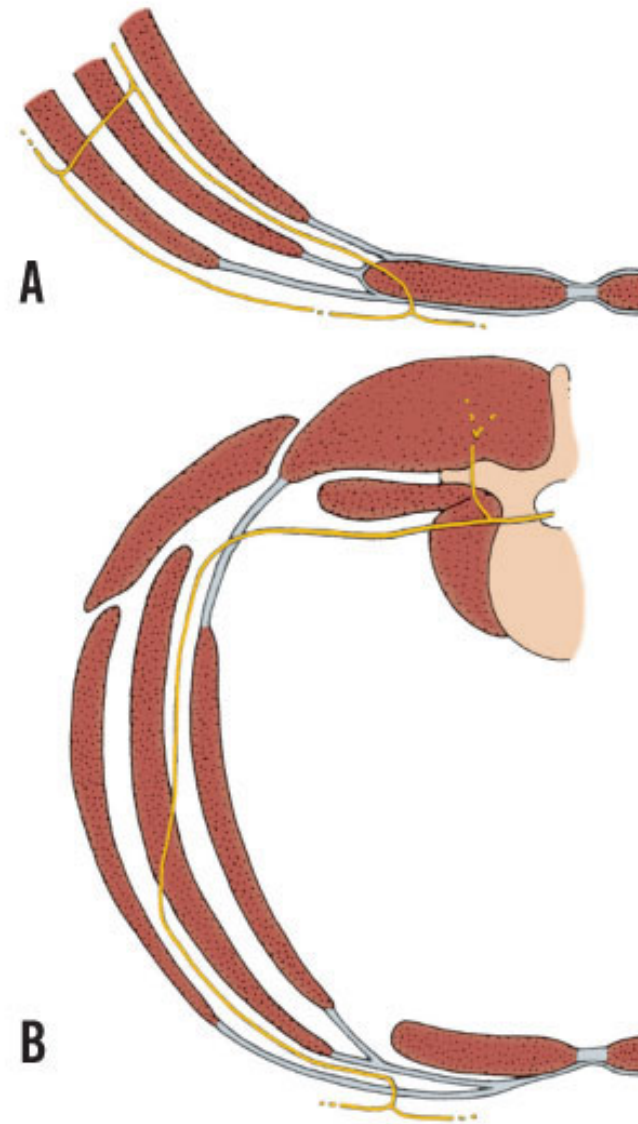
Copyright ©2006 by The McGraw-Hill Companies, Inc.
All rights reserved.

territories of vessels supplying anterior abdominal wall. *Above, left:* Skin territory of superficial inferior epigastric artery (SIEA). *Above, right:* Skin territory of external oblique perforators (EOP). *Center:* Skin territory of deep epigastric system. *Below, left:* Skin territory of superficial circumflex iliac system (SCI). *Below, right:* Skin territory of deep circumflex iliac system (DCI). (Modified from Hester TR Jr, Nahai F, Beegle PE, Bostwick J III. Blood supply of the abdomen revisited, with emphasis on the superficial inferior epigastric artery. *Plast Reconstruct Surg* 1984;74:657-666; with permission.)

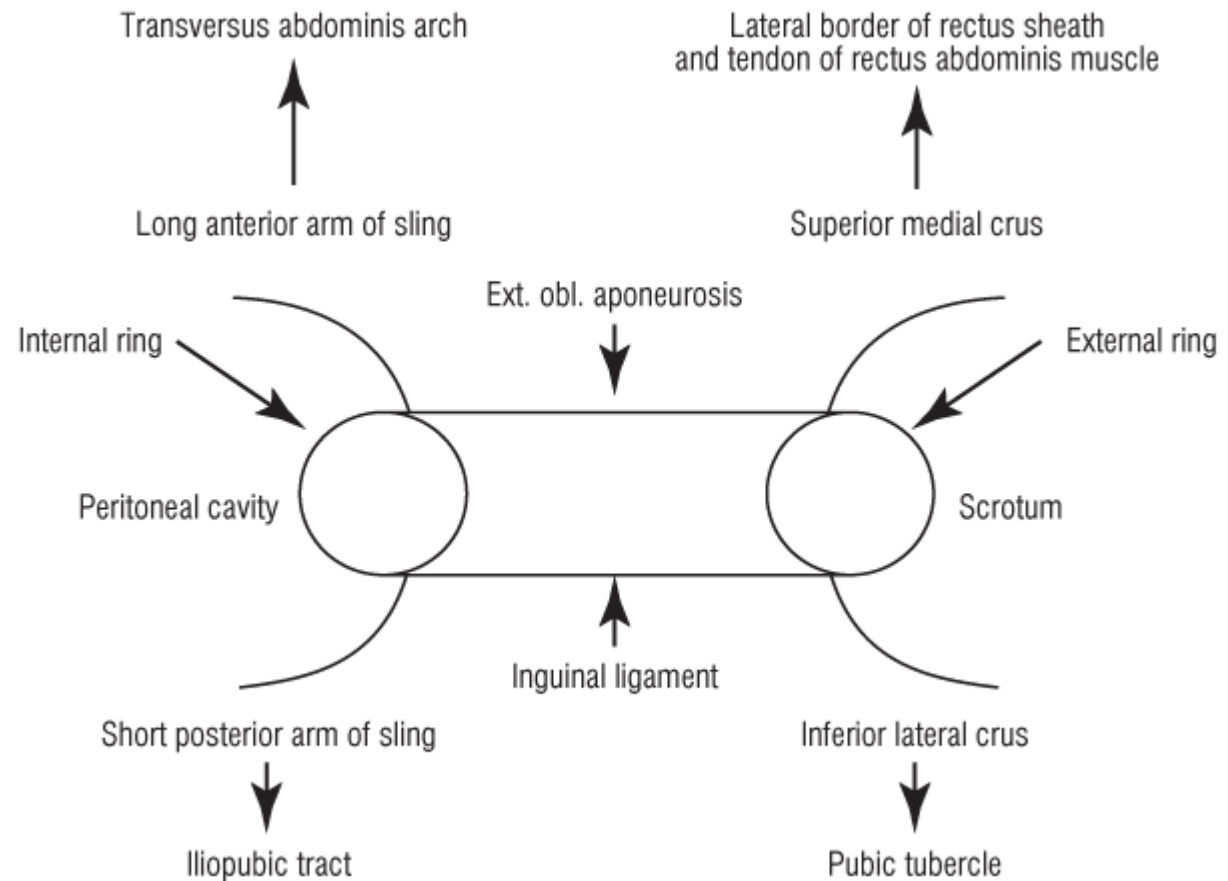


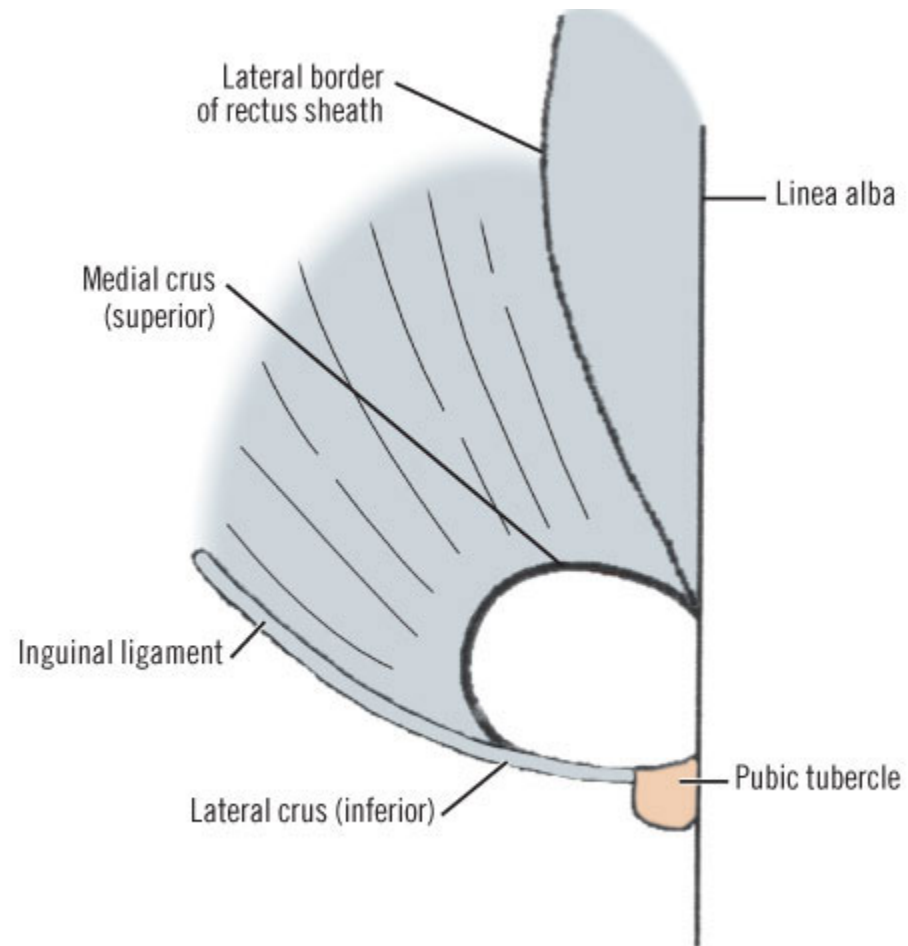


Course of anterior ramus of segmental nerves in anterior body wall. **A**, Seventh to twelfth thoracic nerves. **B**, First lumbar nerve

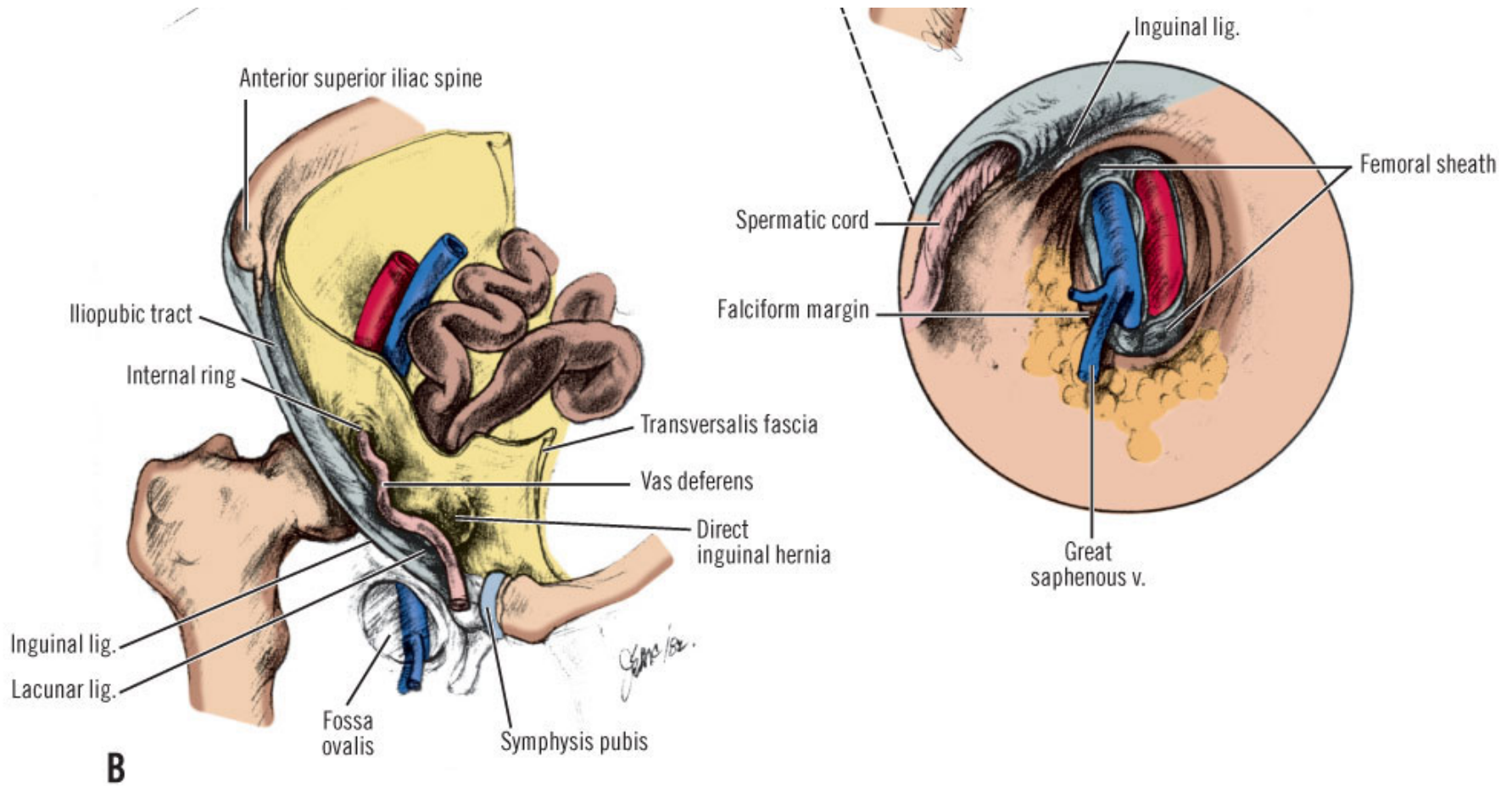


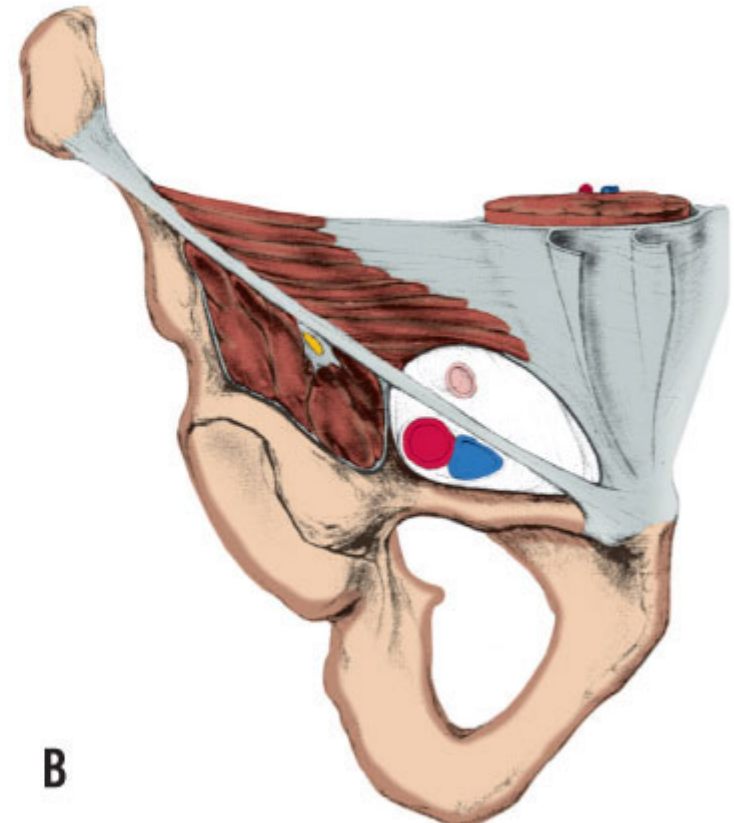
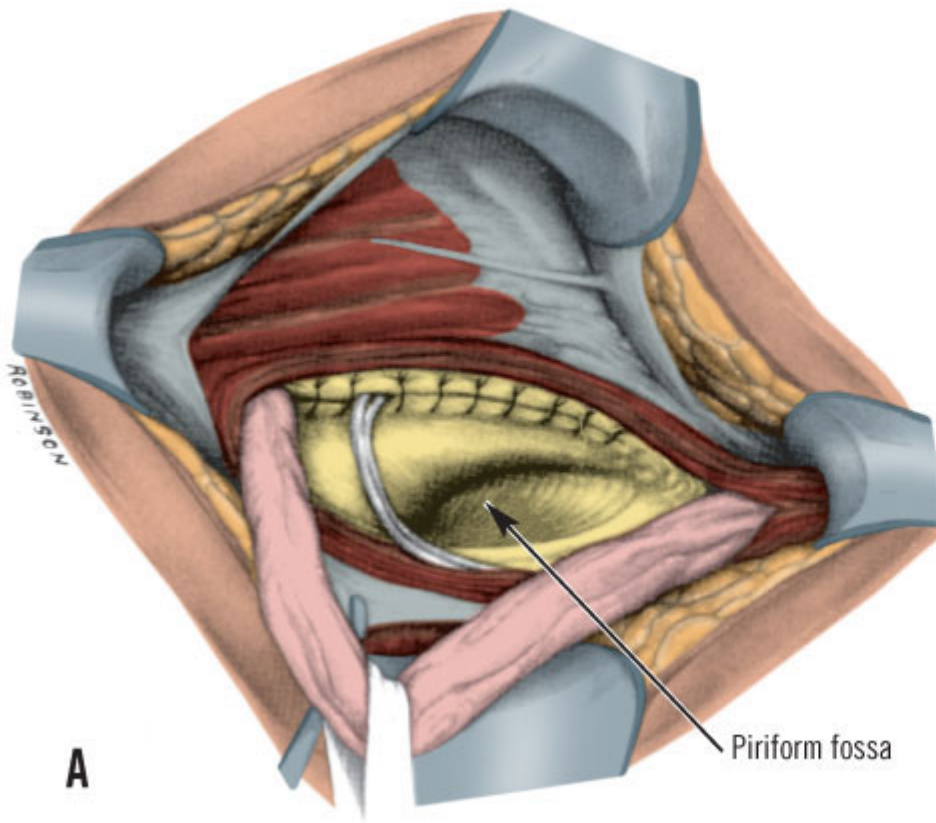
Highly diagrammatic representation of the inguinal canal, presenting only the anterior and inferior formations and the internal and external rings



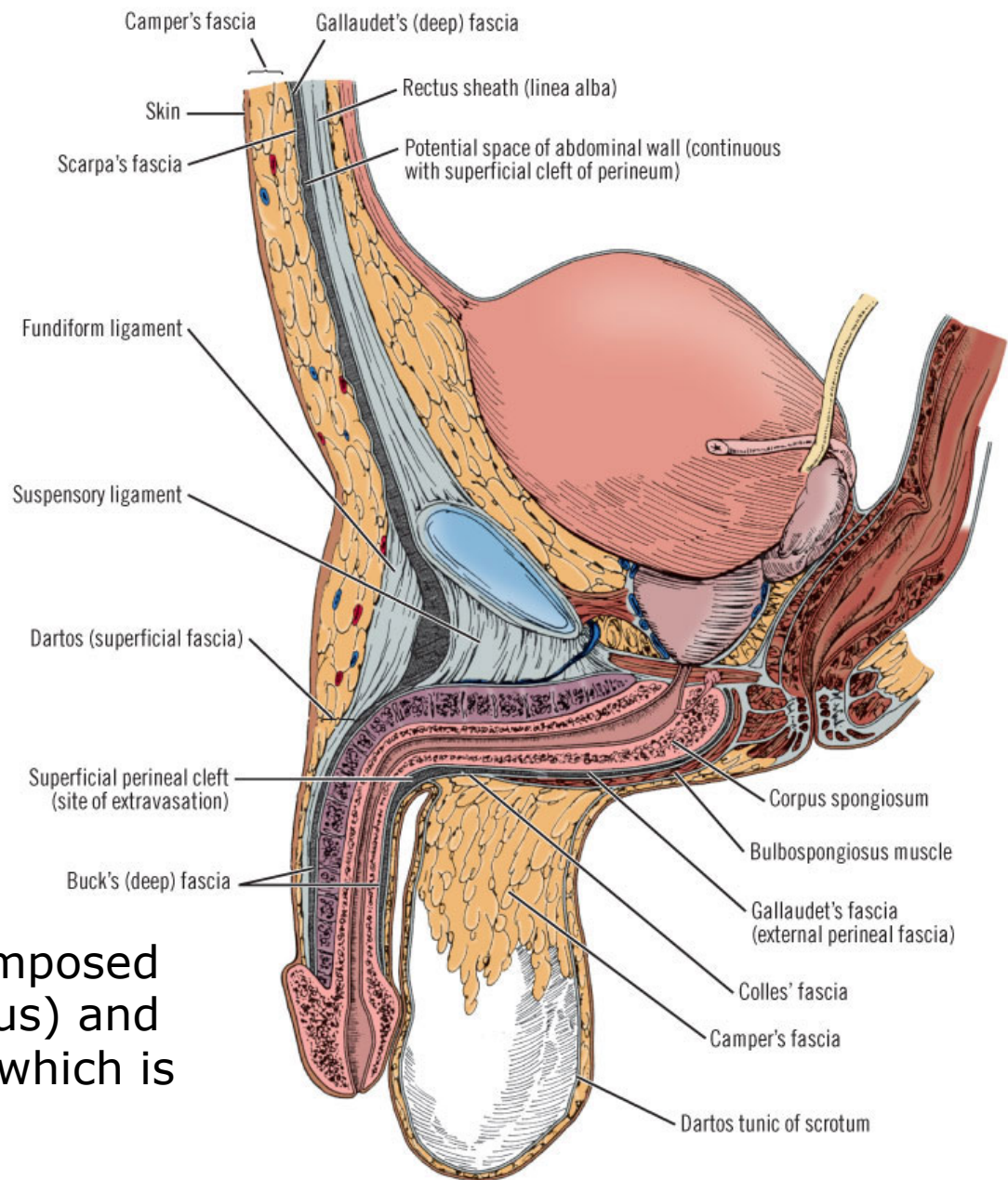


B, Direct inguinal hernia. Note iliopubic tract

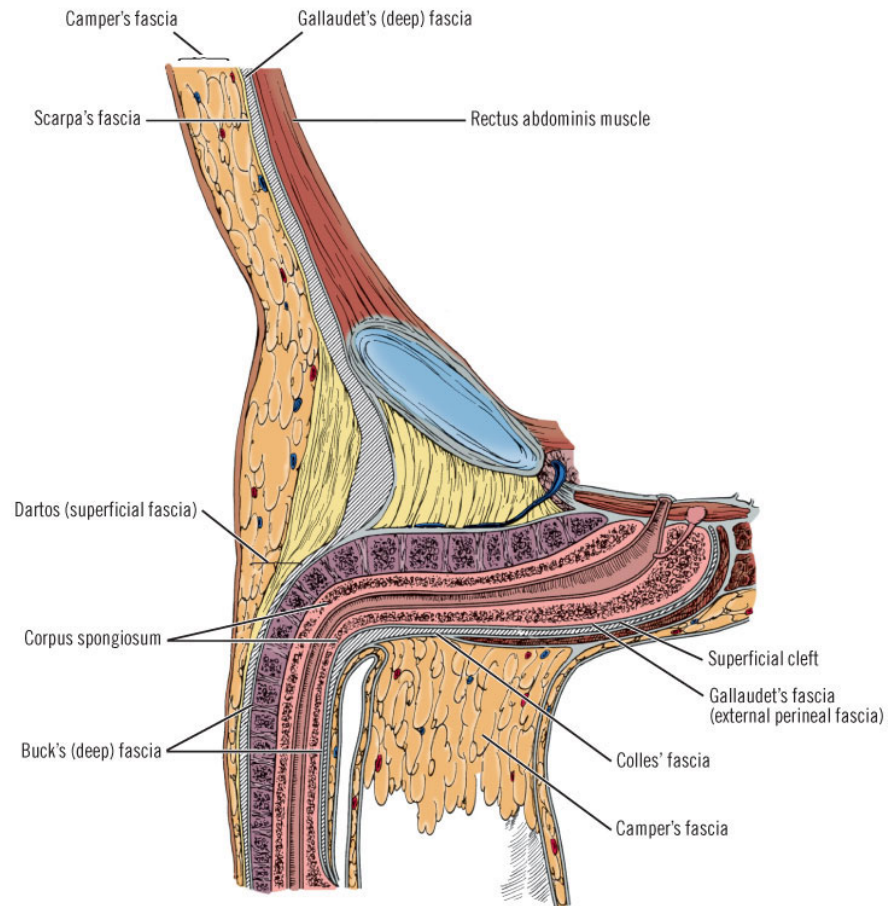
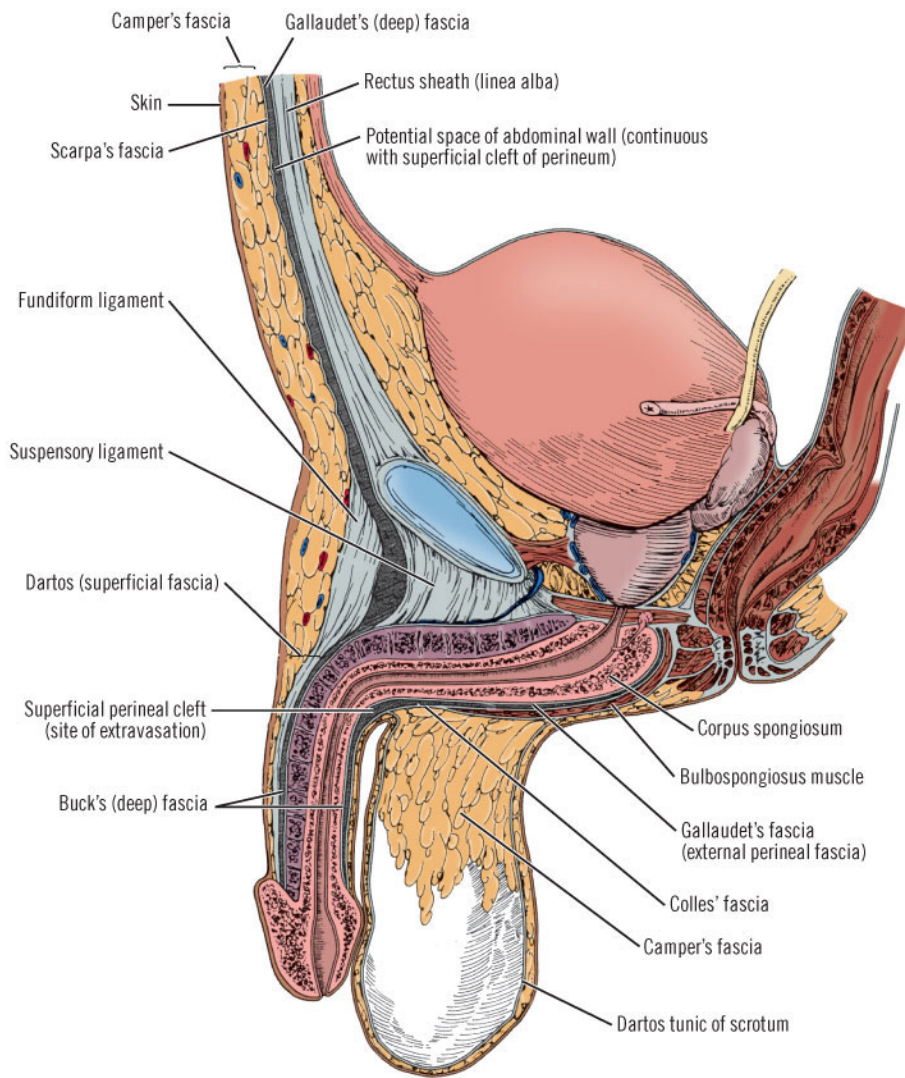




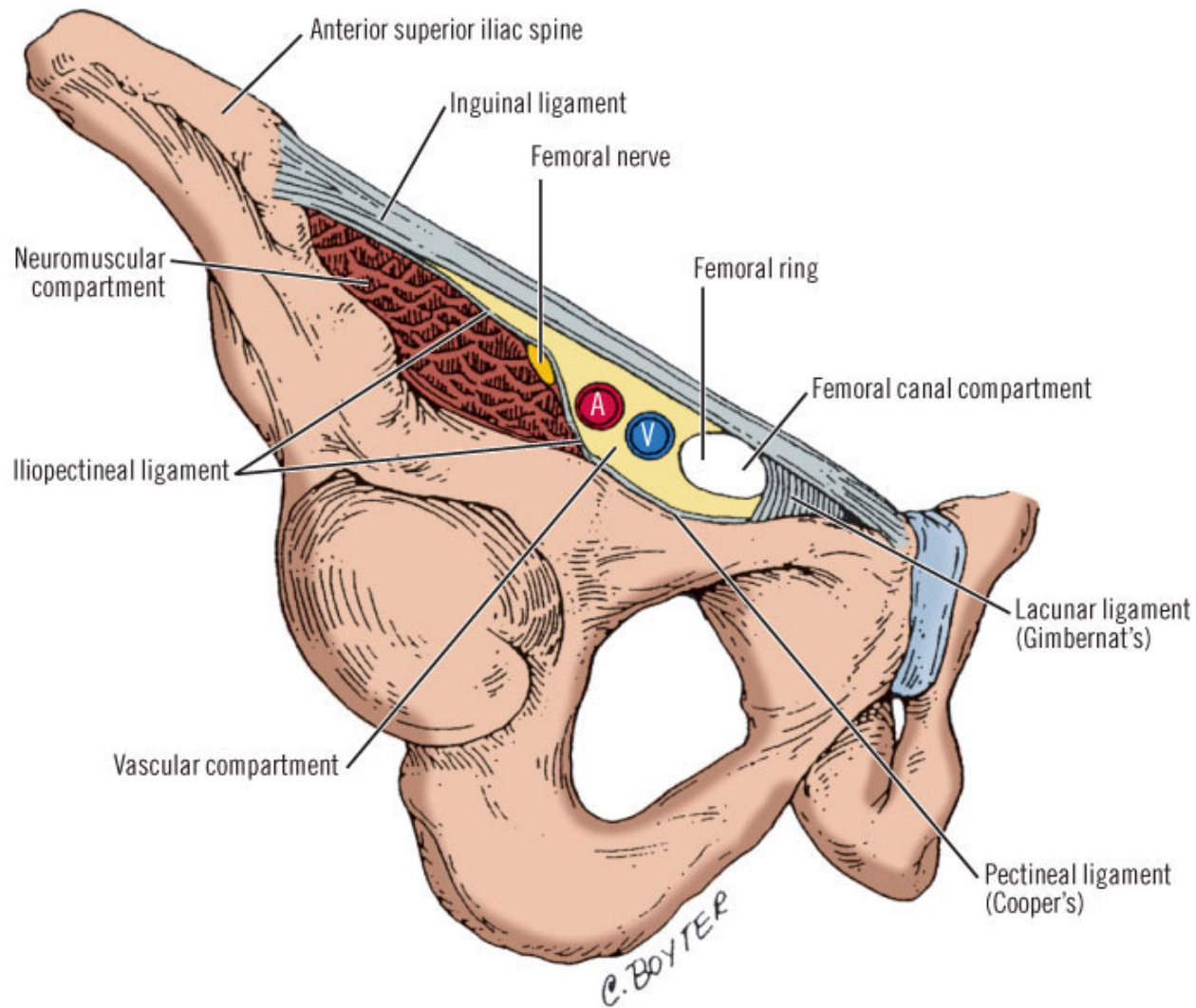
A, Posterior wall ("floor") and piriform fossa (*arrow*) of the inguinal canal. In this illustration the fascia of the posterior wall has been reconstructed by suturing the superior segment to the inferior segment (iliopubic tract). **B**, Anterior view of Fruchaud's myopectineal orifice.



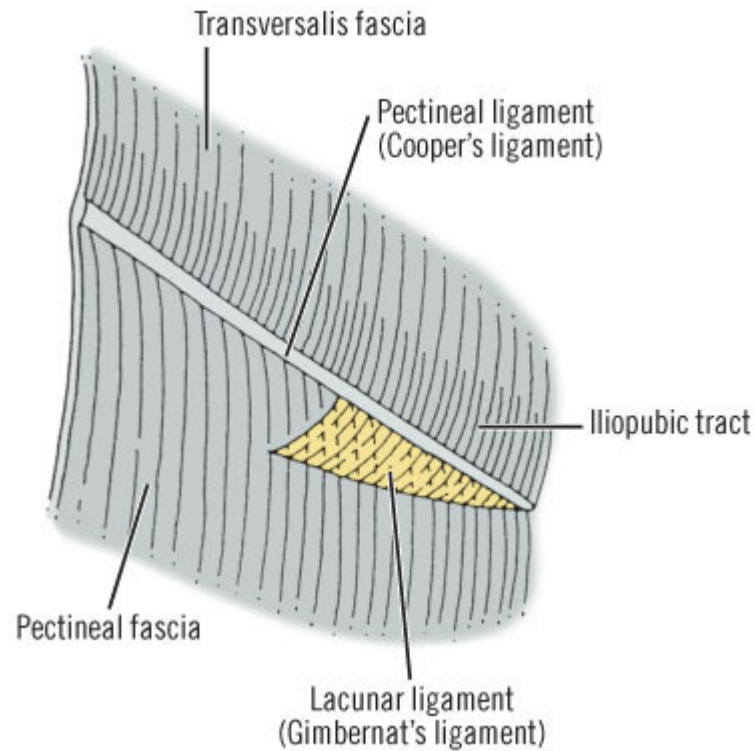
Superficial fascia (dartos): composed of Scarpa's fascia (membranous) and muscle, and Camper's fascia, which is fatty. Gallaudet's fascia is a continuation of Buck's fascia



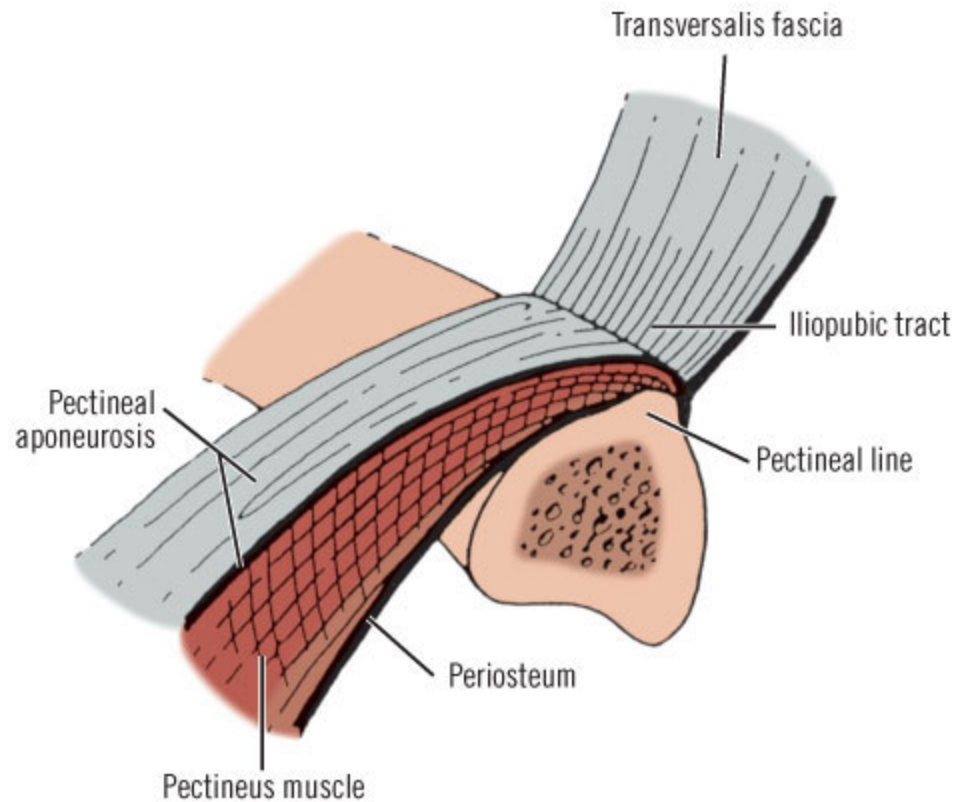
Superficial and deep fascia of the penis. Note the continuity between the elements of the superficial fascia (which form the superficial fascia of the penis), and also the continuity of the Gallaudet fascia of the abdominal wall with the deep (Buck's) fascia of the penis. The cleft between the superficial (Colles') fascia of the perineum and the deep (Gallaudet) fascia of the perineum is also shown



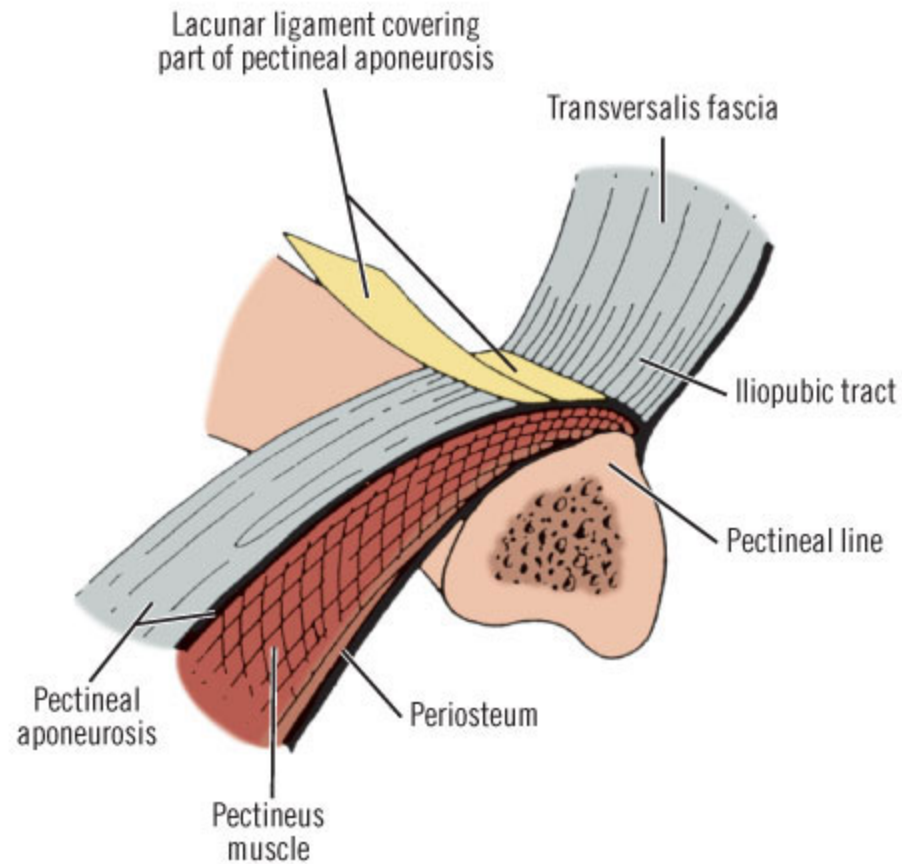
Inguinal ligament, lacunar ligament (Gimbernat's), pectineal ligament (Cooper's), neuromuscular compartment, vascular compartment, compartment of femoral canal.



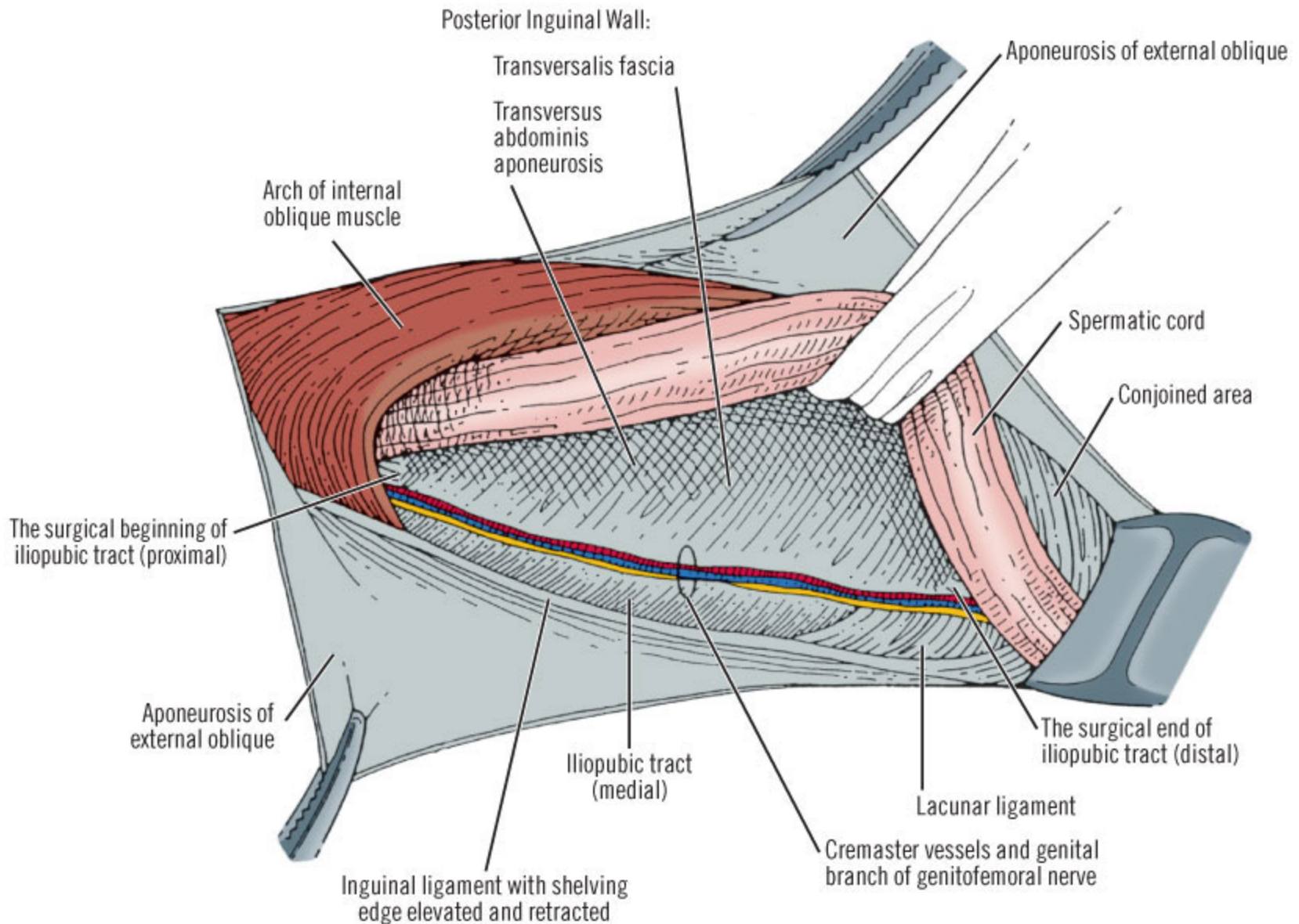
Some anatomic entities participating in formation of pectineal ligament (Cooper's) (highly diagrammatic)



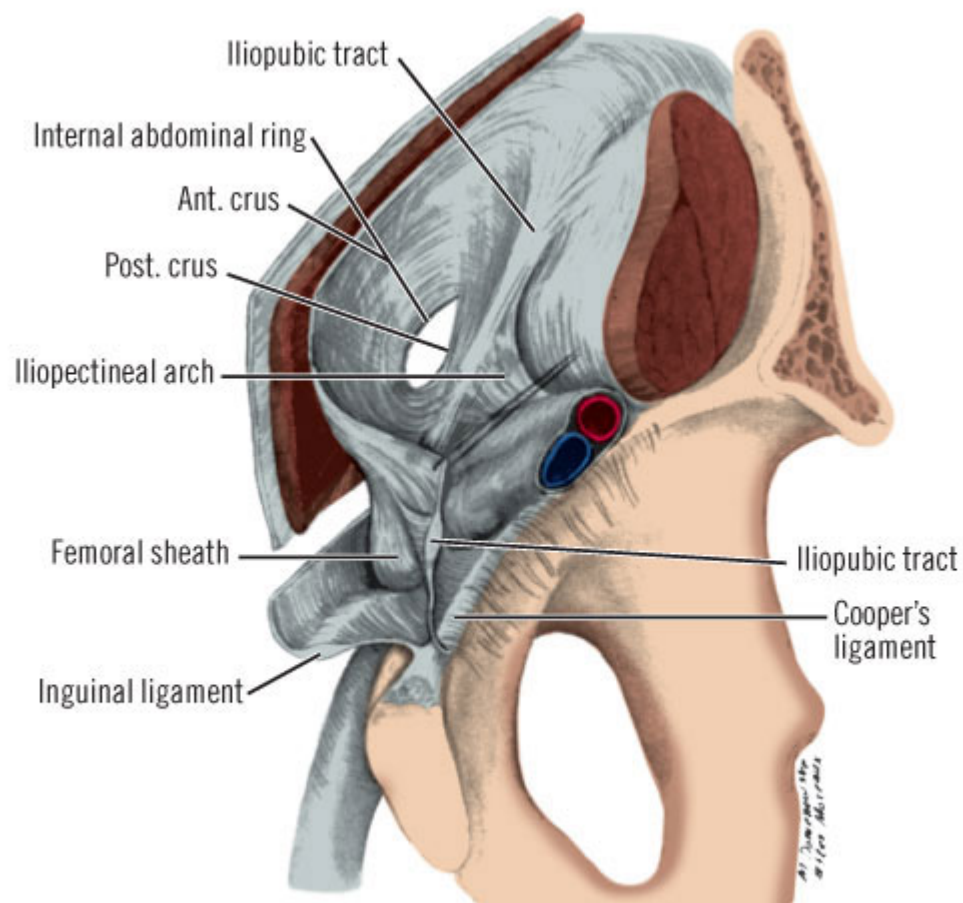
Insertion of iliopubic tract into ligament of Cooper and possible origin of pectineal aponeurosis (highly diagrammatic)



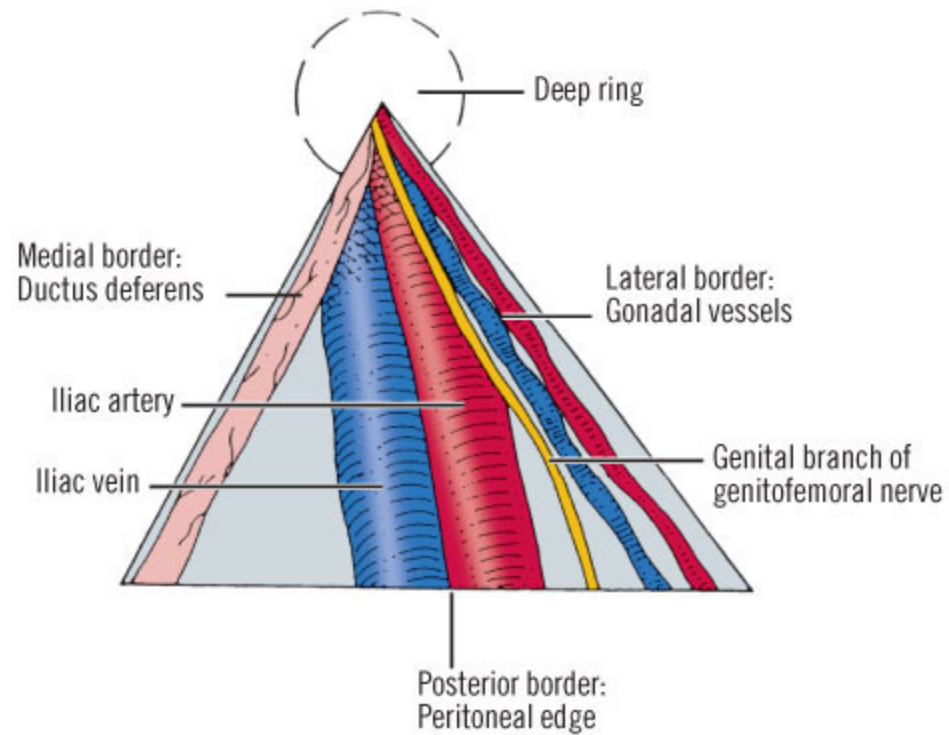
Lacunar ligament (Gimbernat's) partially covers pectineal aponeurosis (highly diagrammatic)



Iliopubic tract and its relations to genital branch of genitofemoral nerve. (Modified from Colborn GL, Skandalakis JE. Importance of the iliopubic, Cooper's and Gimbernat's ligaments



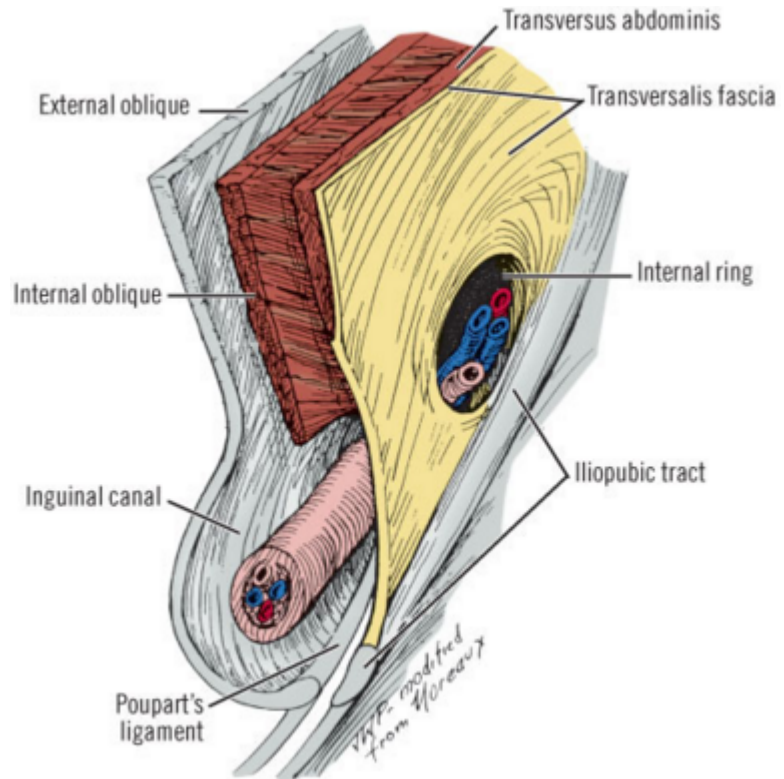
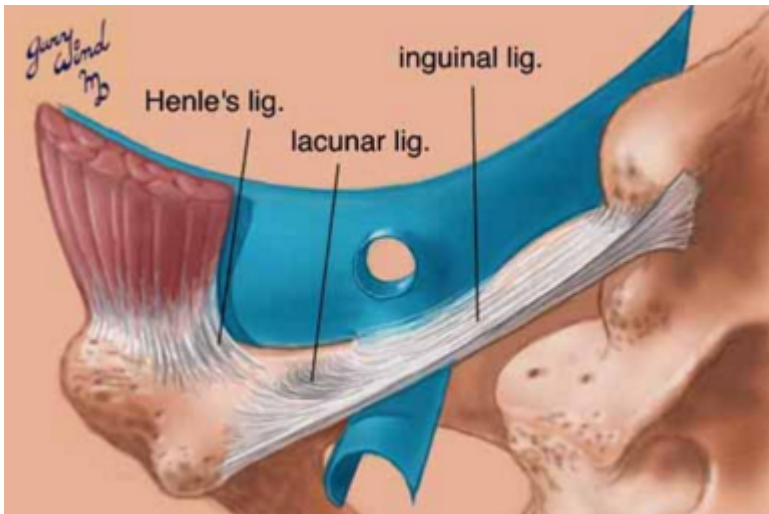
Iliopectineal arch





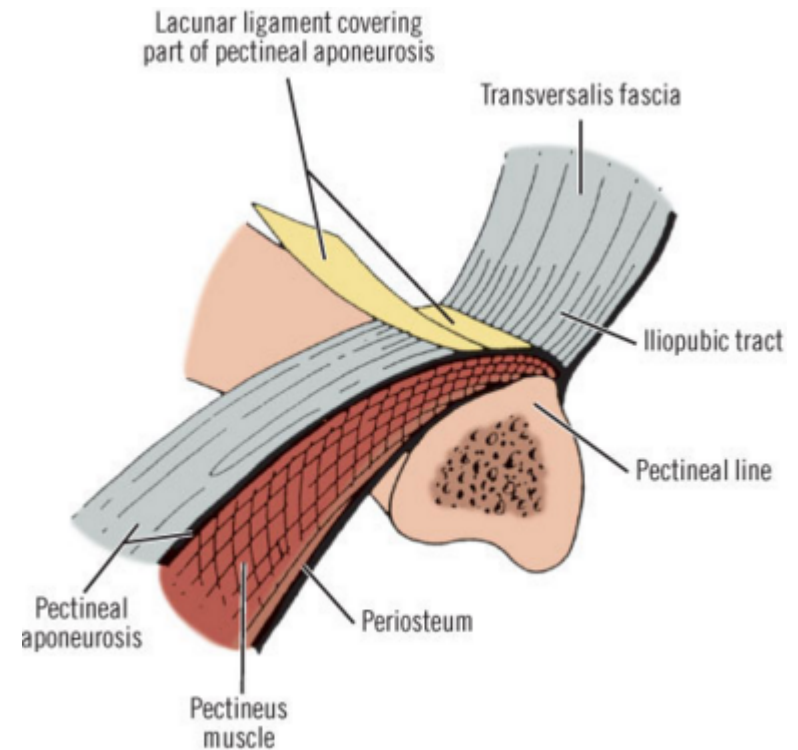
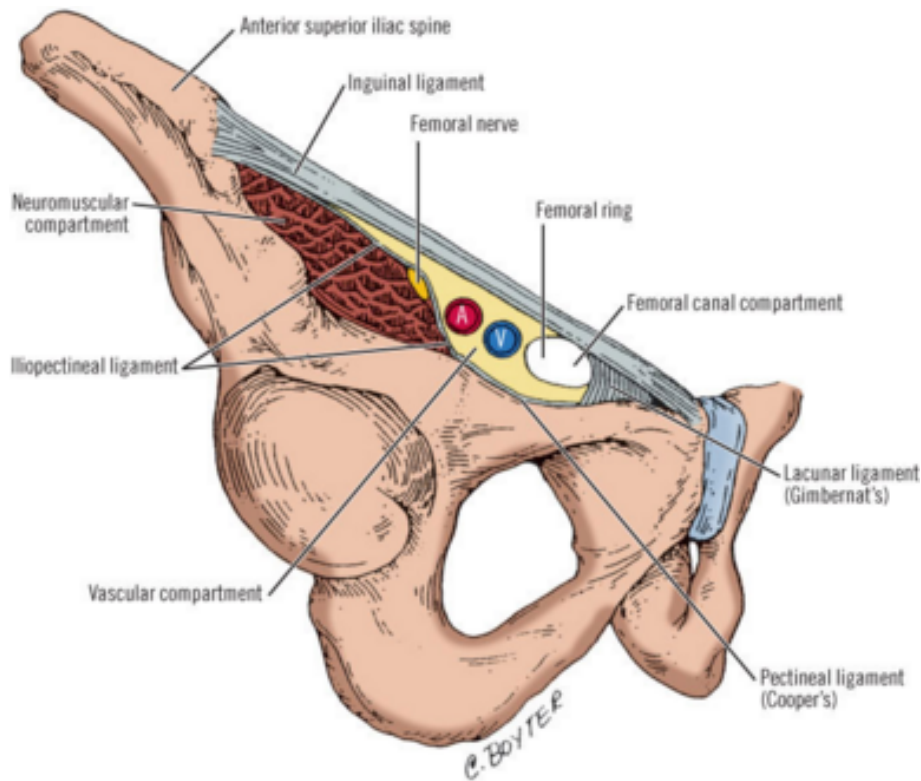
The iliopubic tract

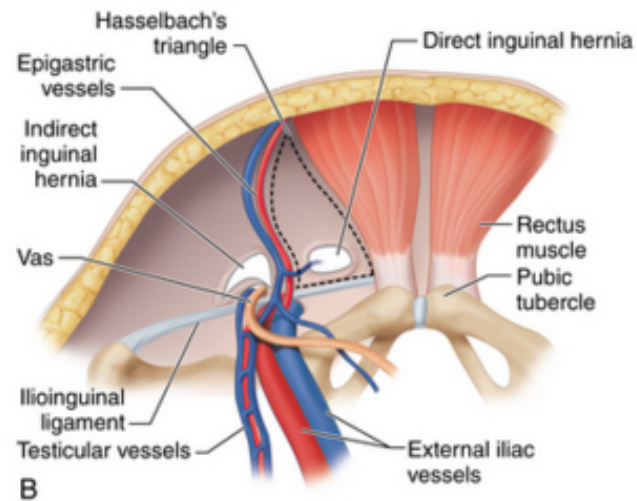
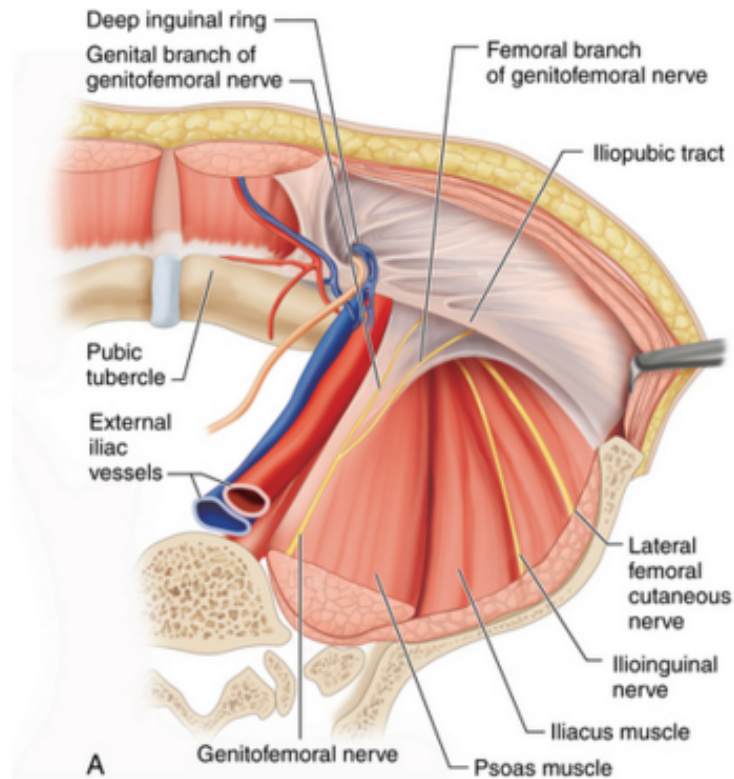
- It comprises the inferior margin of most anterior repairs
- The portion **lateral to the internal inguinal ring** serves as the inferior border below which **staples or tacks are not placed** during a laparoscopic repair because the femoral, lateral femoral cutaneous, and genitofemoral nerves are located inferior to the iliopubic tract



Pectineal (Cooper's) Ligament

- It is formed by the **periosteum and aponeurotic tissues along the superior ramus of the pubis**. It is posterior to the iliopubic tract and forms the **posterior border of the femoral canal**
- It is an important landmark for open and laparoscopic repairs and is a useful **anchoring structure**, particularly in laparoscopic repairs.





ANATOMY OF THE GROIN

Rectus Abdominis Muscle

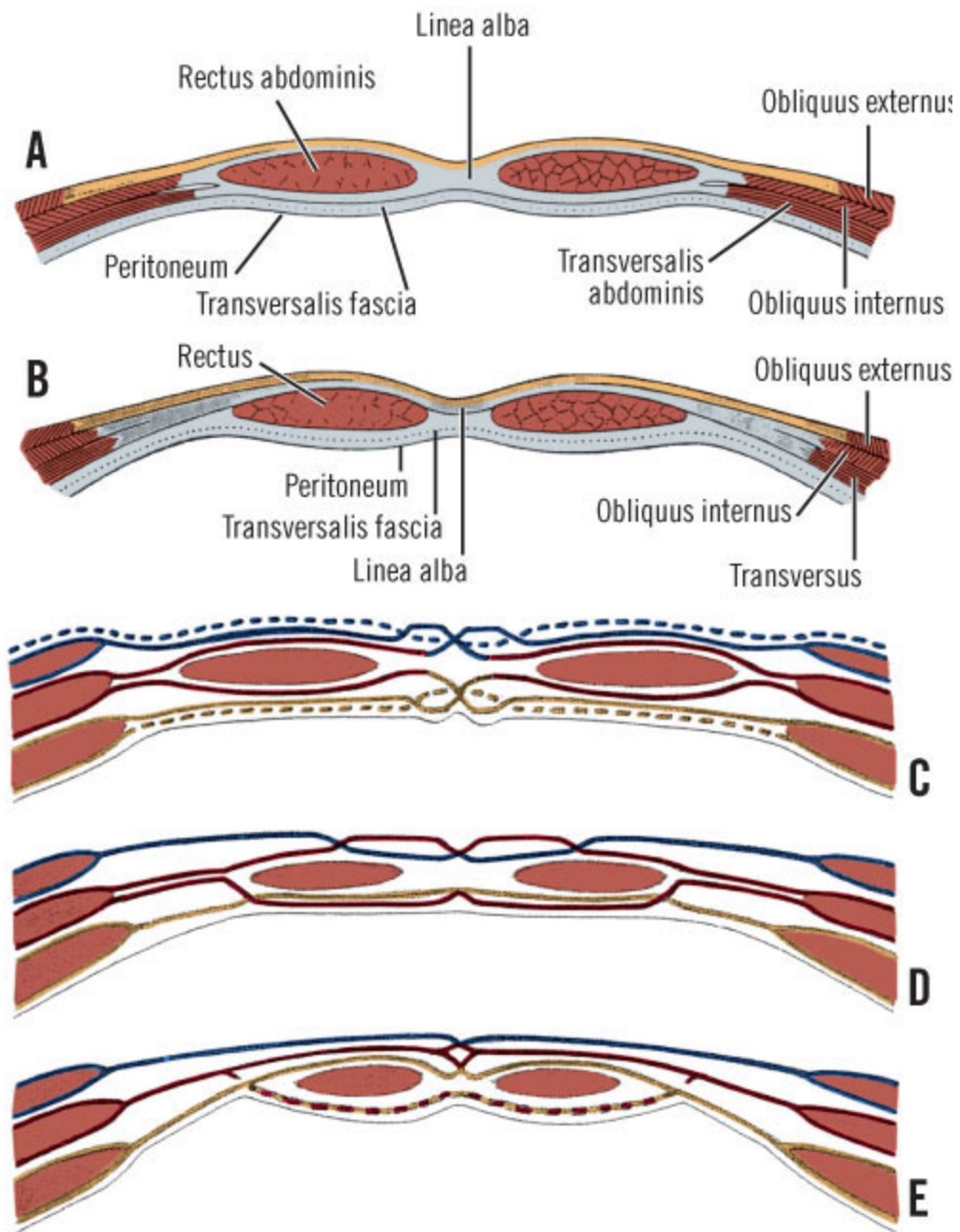
Origin: crest of the pubis and pubic tubercle, pubic symphysis,

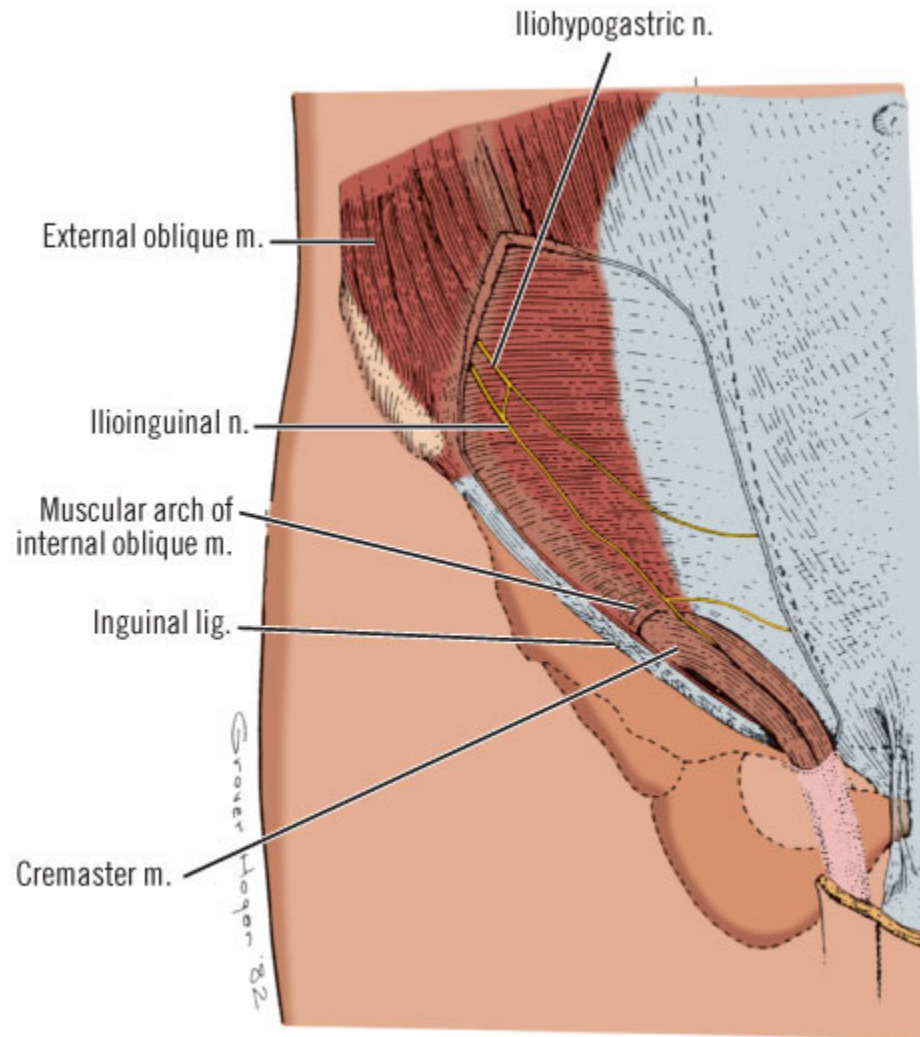
Insertion: pubis, 5-7 ribs, xiphoid process

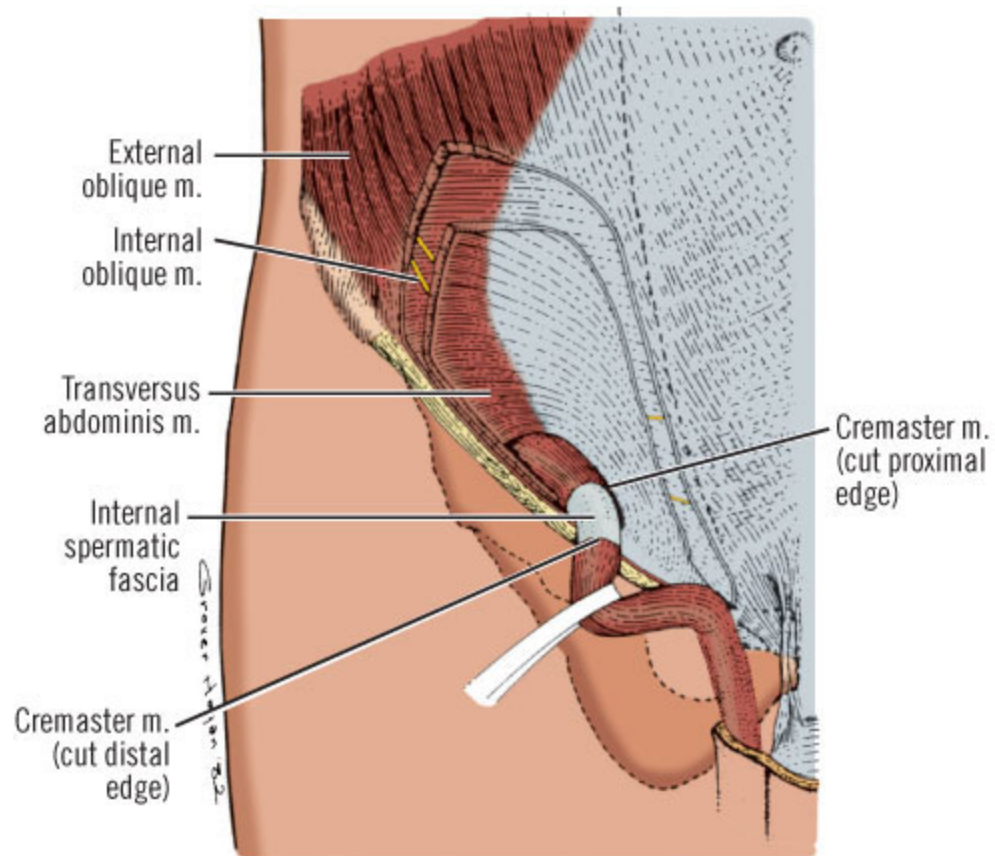
Innervation: spinal nerves T07-T12

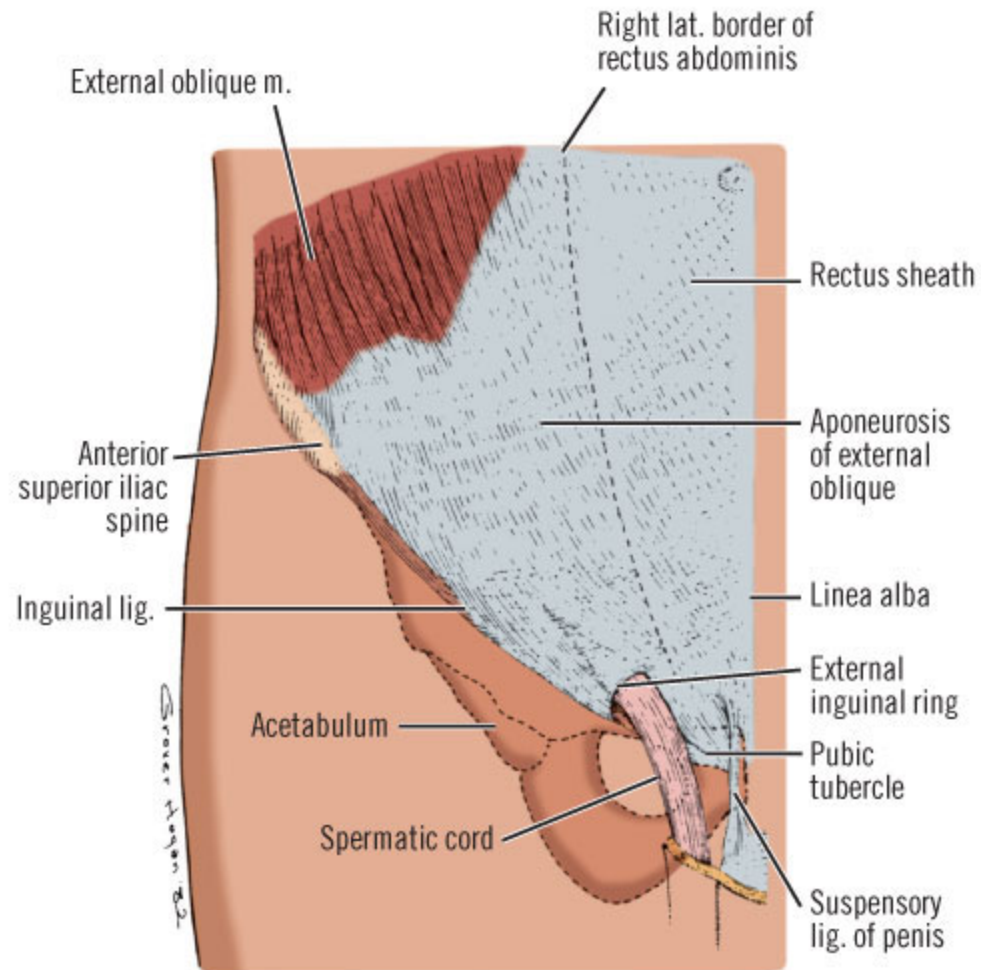
Blood Supply: inferior epigastric artery

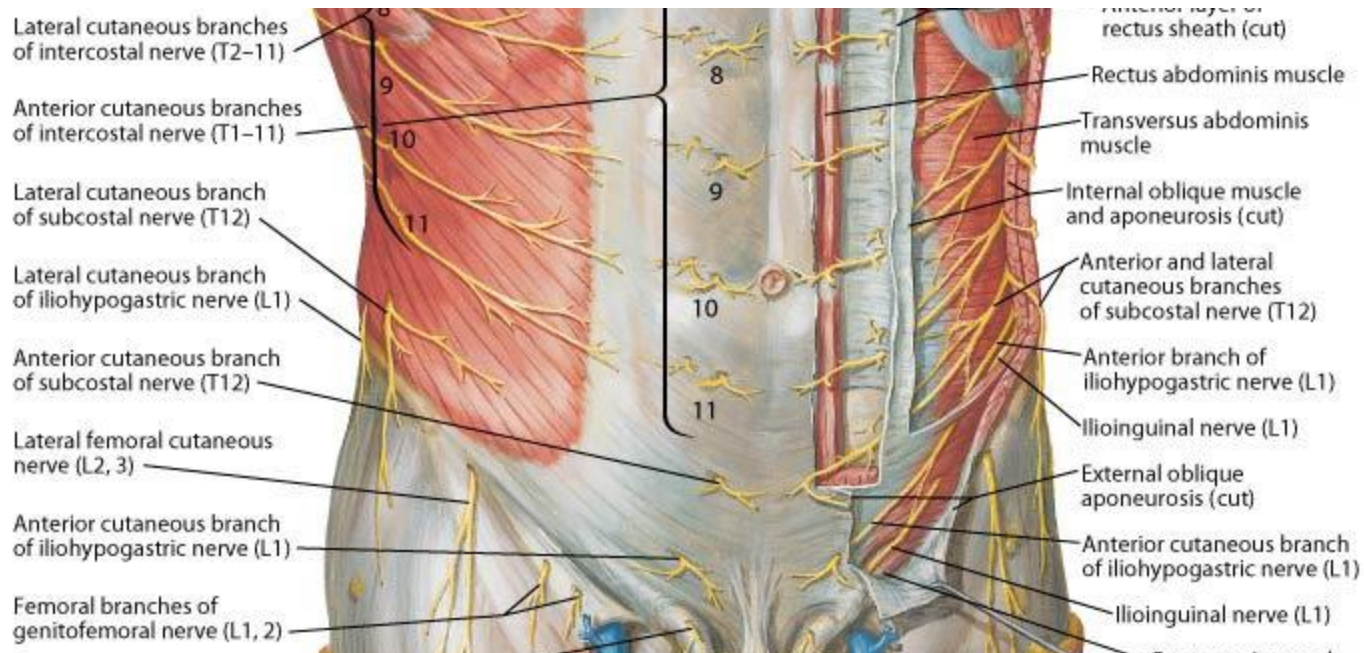
Action: flexes vertebral column, tenses abdominal wall, compresses abdominal viscera

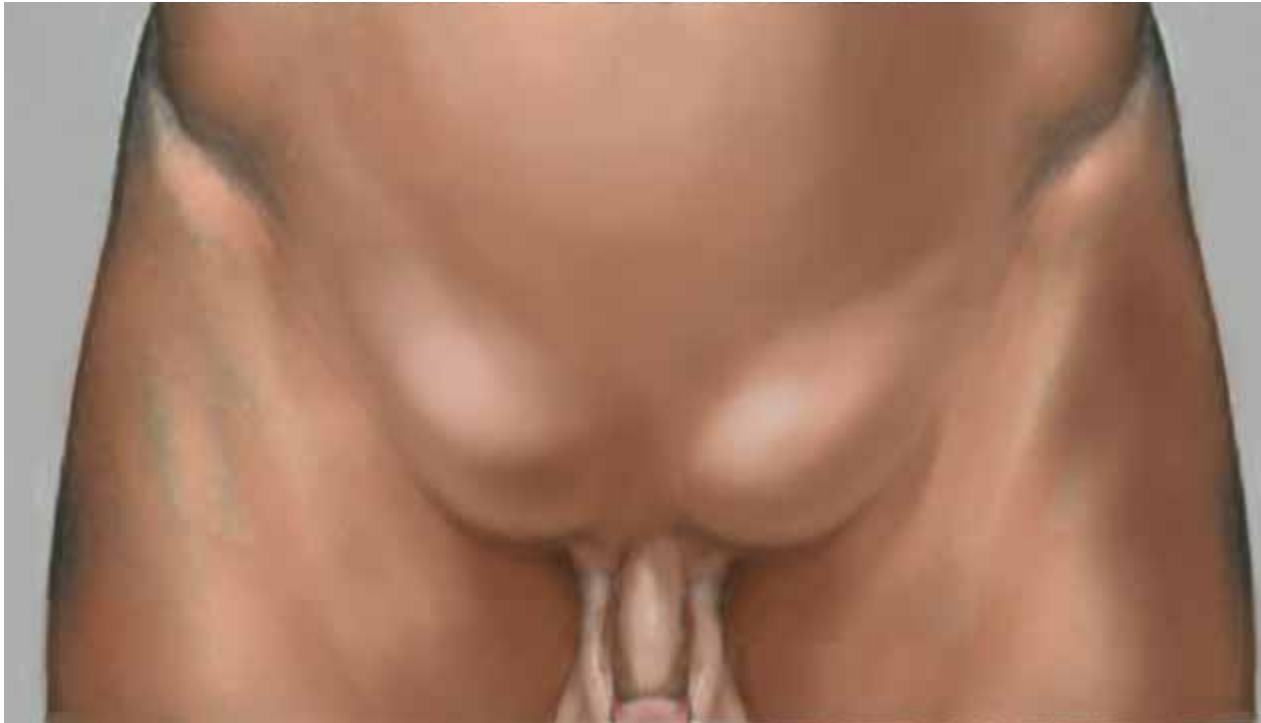

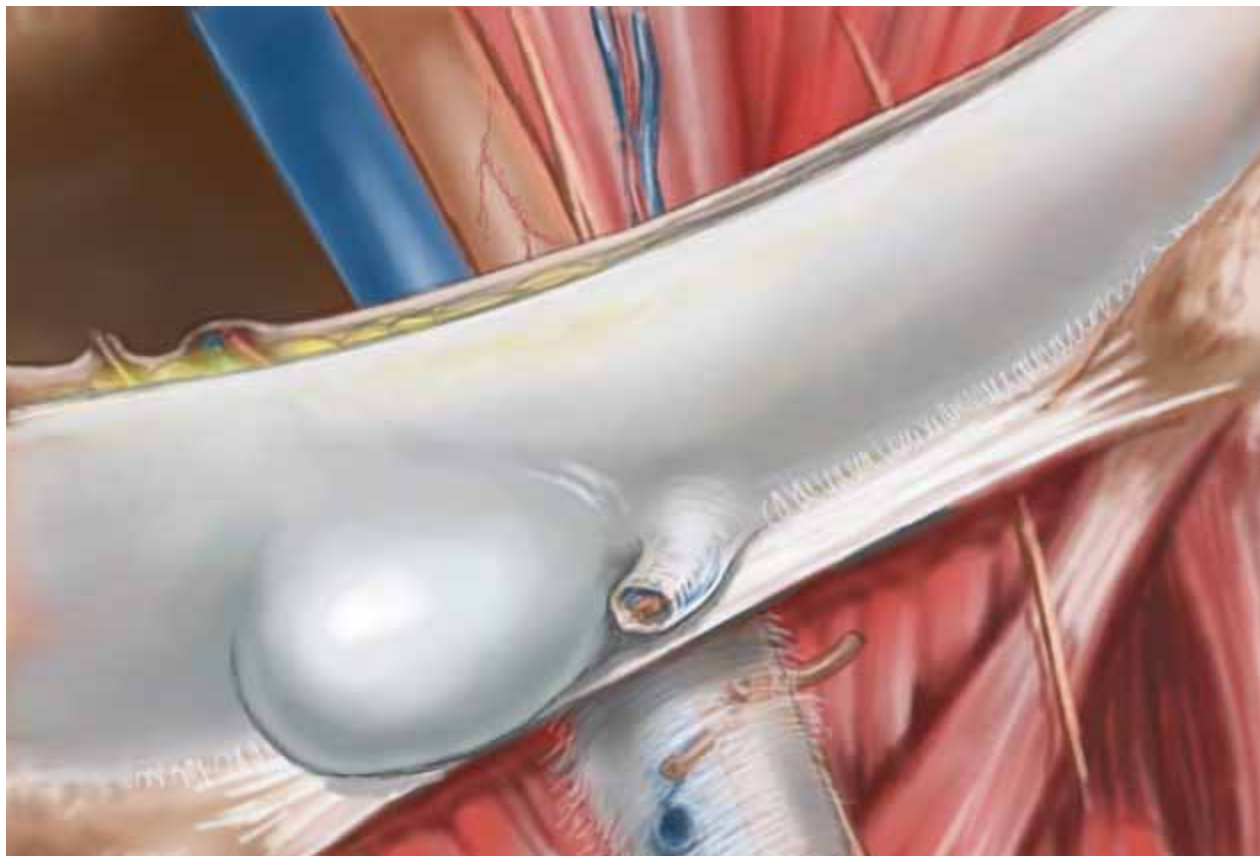


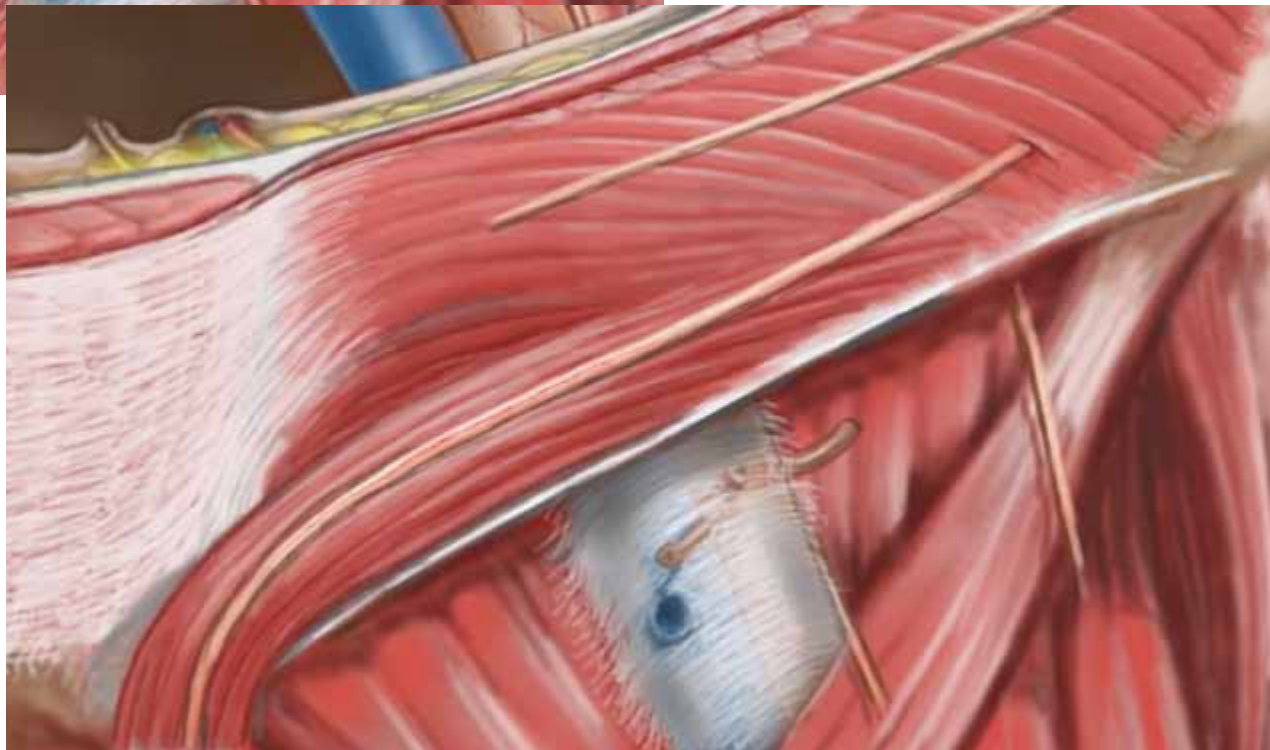
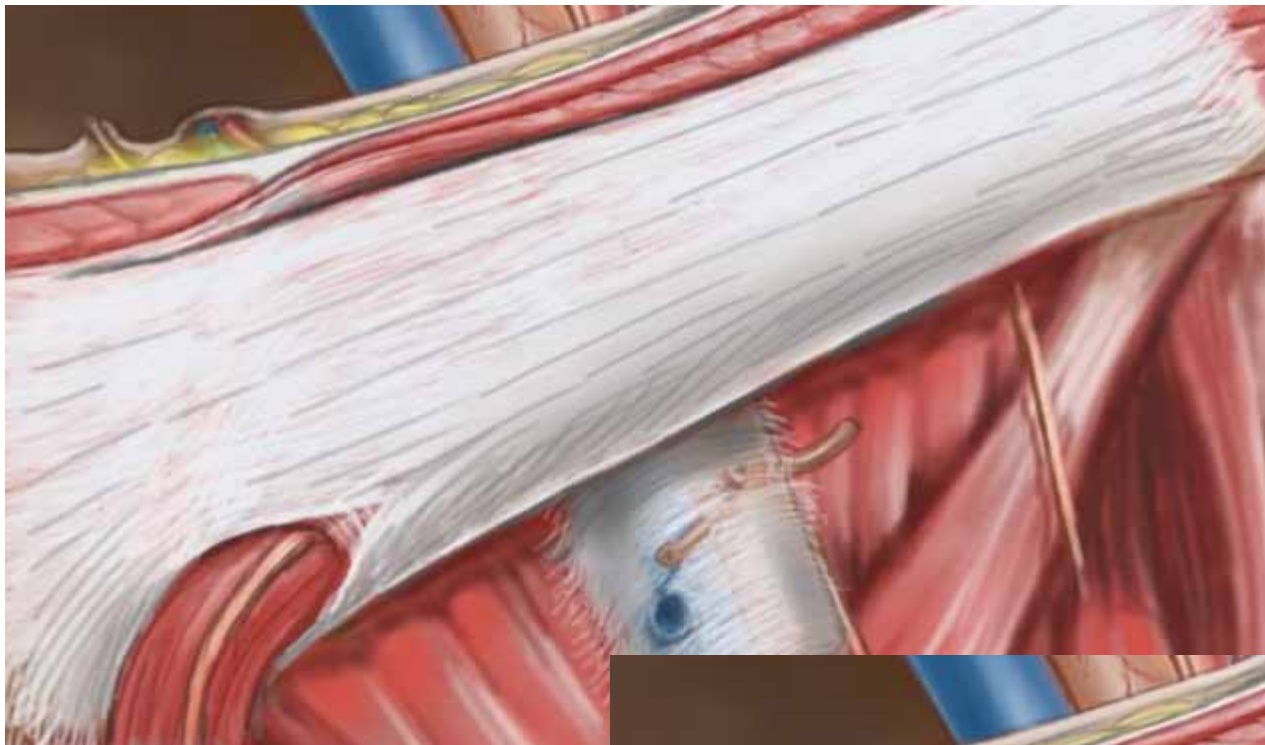


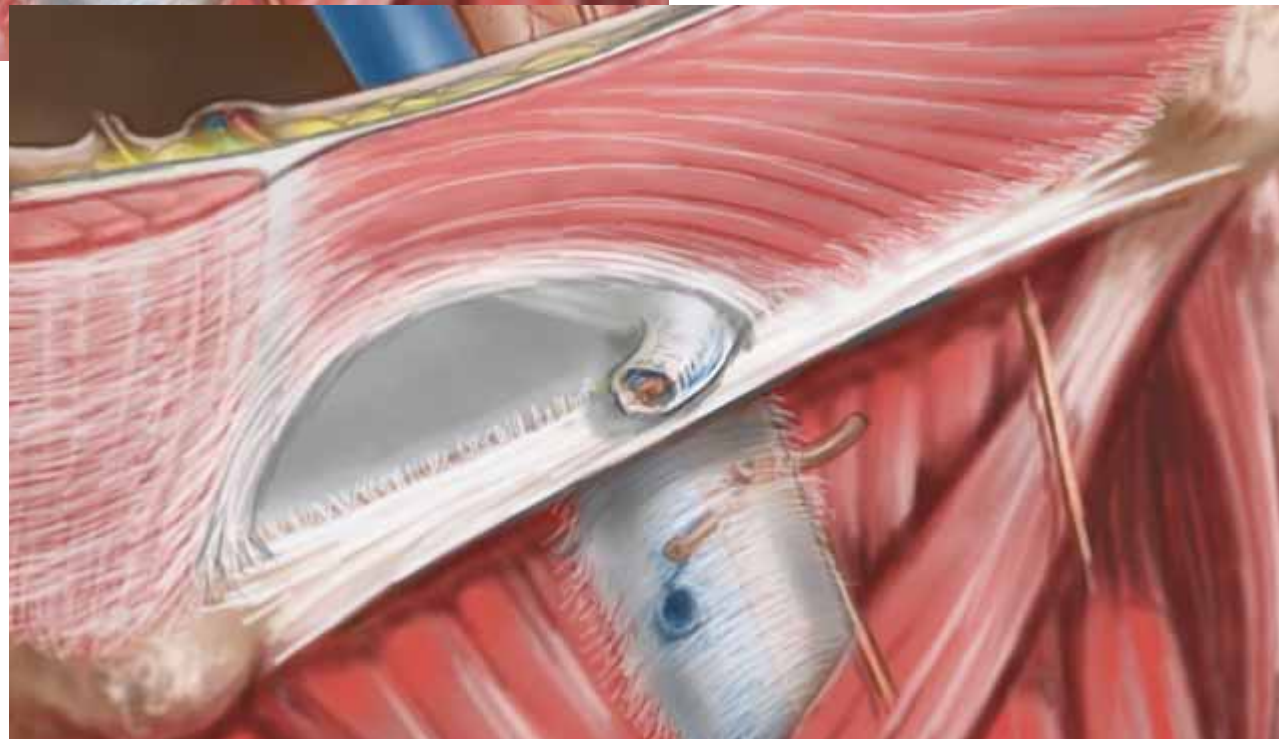
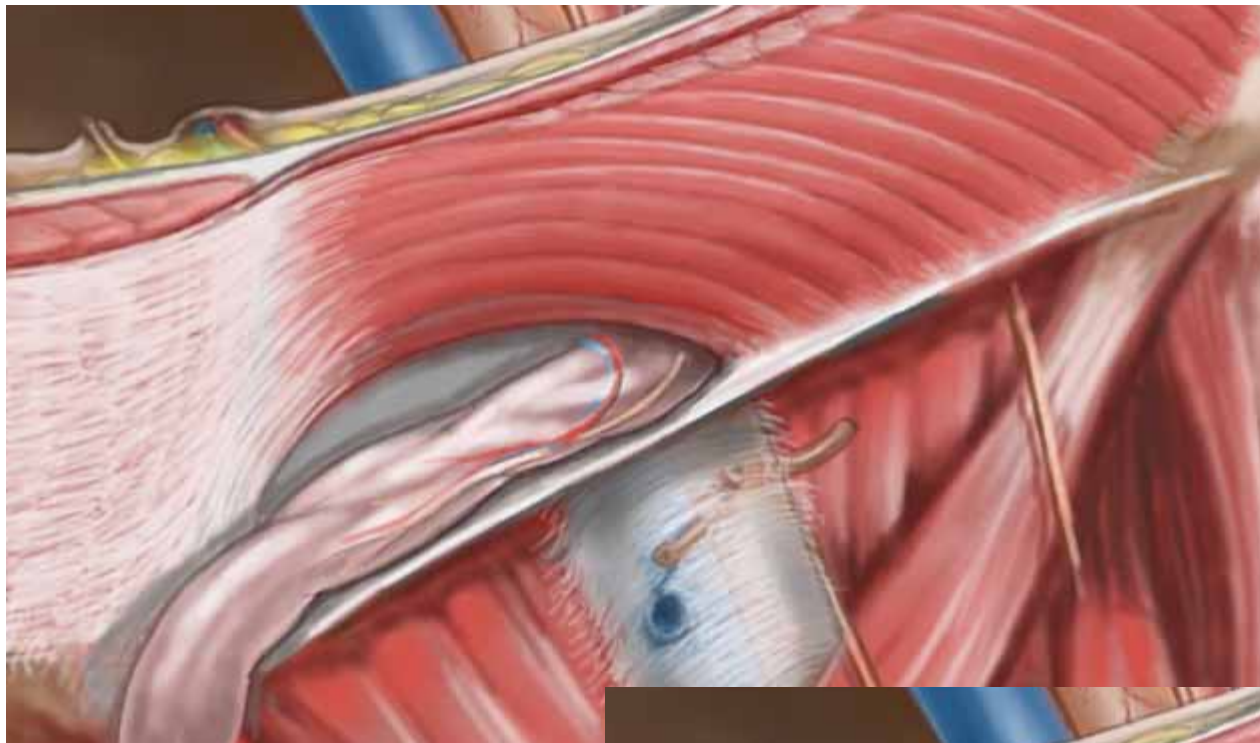














SAPIENZA
UNIVERSITÀ DI ROMA

giuseppe.nigri@uniroma1.it