

BRIEF REPORT

## Ebola Virus Transmission Initiated by Relapse of Systemic Ebola Virus Disease

P. Mbala-Kingebeni, C. Pratt, M. Mutafali-Ruffin, M.G. Pauthner, F. Bile, A. Nkuba-Ndaye, A. Black, E. Kinganda-Lusamaki, M. Faye, A. Aziza, M.M. Diagne, D. Mukadi, B. White, J. Hadfield, K. Gangavarapu, N. Bisento, D. Kazadi, B. Nsunda, M. Akonga, O. Tshiani, J. Misasi, A. Ploquin, V. Epaso, E. Sana-Paka, Y.T.T. N'kassar, F. Mambu, F. Edidi, M. Matondo, J. Bula Bula, B. Diallo, M. Keita, M.R.D. Belizaire, I.S. Fall, A. Yam, S. Mulangu, A.W. Rimion, E. Salfati, A. Torkamani, M.A. Suchard, I. Crozier, L. Hensley, A. Rambaut, O. Faye, A. Sall, N.J. Sullivan, T. Bedford, K.G. Andersen, M.R. Wiley, S. Ahuka-Mundeke, and J.-J. Muyembe Tamfum

SUMMARY

The authors' full names, academic degrees, and affiliations are listed in the Appendix. Address reprint requests to Dr. Mbala-Kingebeni at Institut National de Recherche Biomédicale, 5345, Ave. de la Democratie, B.P. 1187 Gombe, Kinshasa, Democratic Republic of Congo, or at mbalaplacide@gmail.com; or to Dr. Wiley at 984388 Nebraska Medical Center, Omaha, NE 68198-4388, or at mike.wiley@unmc.edu.

Dr. Mbala-Kingebeni, Ms. Pratt, and Drs. Mutafali-Ruffin, Pauthner, Bile, Nkuba-Ndaye, and Black and Drs. Sullivan, Bedford, Andersen, Wiley, Ahuka-Mundeke, and Muyembe Tamfum contributed equally to this article.

This is the *New England Journal of Medicine* version of record, which includes all *Journal* editing and enhancements. The Author Final Manuscript, which is the author's version after external peer review and before publication in the *Journal*, is available under a CC BY license at PMC7888312.

This article was updated on April 1, 2021, at NEJM.org.

N Engl J Med 2021;384:1240-7.

DOI: 10.1056/NEJMoa2024670

Copyright © 2021 Massachusetts Medical Society.

During the 2018–2020 Ebola virus disease (EVD) outbreak in North Kivu province in the Democratic Republic of Congo, EVD was diagnosed in a patient who had received the recombinant vesicular stomatitis virus–based vaccine expressing a ZEBOV glycoprotein (rVSV-ZEBOV) (Merck). His treatment included an Ebola virus (EBOV)–specific monoclonal antibody (mAb114), and he recovered within 14 days. However, 6 months later, he presented again with severe EVD-like illness and EBOV viremia, and he died. We initiated epidemiologic and genomic investigations that showed that the patient had had a relapse of acute EVD that led to a transmission chain resulting in 91 cases across six health zones over 4 months. (Funded by the Bill and Melinda Gates Foundation and others.)

**H**UMAN-TO-HUMAN TRANSMISSION OF EBOLA VIRUS (EBOV) TYPICALLY occurs through direct contact with infectious blood or bodily fluids (e.g., semen or breast milk).<sup>1</sup> EBOV persistence has been well documented in survivors of Ebola virus disease (EVD). Although secondary transmission through contact with infectious bodily fluids is relatively rare, it has been linked to flare-up events.<sup>2</sup> In two survivors of EVD, meningoencephalitis and uveitis syndromes have been associated with infectious EBOV in cerebrospinal fluid and aqueous humor, respectively; neither case led to further transmission.<sup>3,4</sup> Here, we report the relapse of acute EVD in a patient who was infected with the EBOV Ituri variant during the 2018–2020 North Kivu EVD outbreak in the Democratic Republic of Congo (DRC).<sup>5</sup> The relapse, which occurred 149 days after the patient was discharged from an Ebola treatment unit, sparked a transmission chain of 91 cases.

CASE REPORT

PATIENT HISTORY AND EPIDEMIOLOGIC FINDINGS

A 25-year-old man who worked as a motorcycle taxi driver presented to the Ebola treatment unit (ETU) in Mangina, DRC, on June 15, 2019, with a 2-day history of fever, nausea, vomiting, asthenia, anorexia, myalgia, and chest pain. Accord-

**Table 1. Diagnostic Test Results in Samples Obtained during the First and Second Episodes of EVD in the Patient in 2019.\***

Sample and Laboratory Identifiers†	Date Sample Collected	Sample Type	Glycoprotein Ct Value	Nucleoprotein Ct Value	Glycoprotein IgG EC <sub>50</sub> Titer	Virus Sequenced‡
Sample d1: MAN4194	June 15	Serum	32.5	29.9	Negative	Yes
MAN4337	June 18	Serum	Negative	41.7	—	—
MAN4434	June 20	Serum	41.3	39.2	—	—
MAN4524	June 22	Serum	Negative	38.5	—	—
MAN4694	June 25	Serum	Negative	38.0	—	—
MAN4796	June 27	Serum	Negative	Negative	—	—
Sample d14: MAN4907	June 29	Serum	Negative	Negative	1:77,579	—
Identifier unknown	Aug. 27	Semen	Negative	Negative	—	—
Sample d171: MAN12309	Dec. 3	Serum	33.3	30.1	1:164,609	Yes
Sample d173: MAN12369	Dec. 5	Oral swab	28.7	24.8	—	Yes

\* The glycoprotein and nucleoprotein targets of Ebola virus RNA were detected with the use of GeneXpert diagnostic quantitative reverse-transcriptase–polymerase-chain-reaction assays (Xpert Ebola Assay, Cepheid) and are expressed as cycle-threshold (Ct) values. Glycoprotein binding titers were assessed with the use of an enzyme-linked immunosorbent assay (Alpha Diagnostic International) with a readout for the anti-Ebola glycoprotein IgG EC<sub>50</sub> (the concentration at which there is a 50% decrease in antigen binding). EVD denotes Ebola virus disease.

† Sample identifiers were assigned only to the samples described in this article.

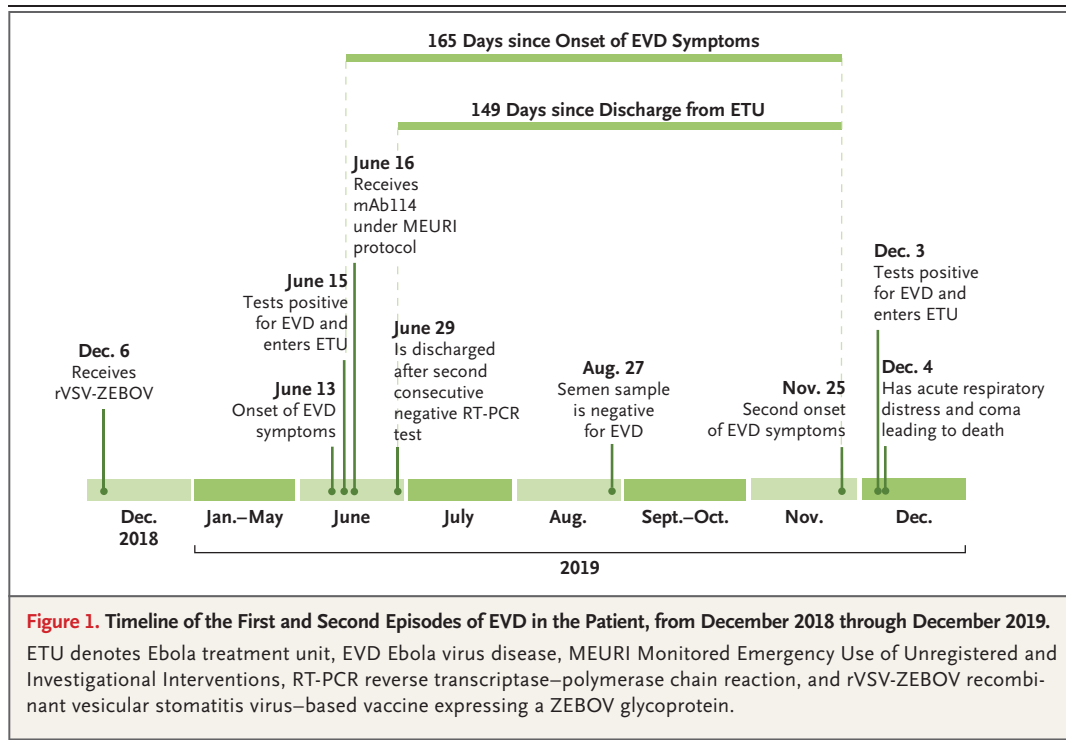
‡ Samples from which full viral genomes were determined are indicated.

ing to the patient's medical record, he had received the recombinant vesicular stomatitis virus–based vaccine expressing a ZEBOV glycoprotein (rVSV-ZEBOV)<sup>6</sup> (Merck, lot number WL00064825) 6 months previously (on December 6, 2018) because he was a contact of a person with confirmed EVD. Despite his previous vaccination, we detected EBOV RNA in the patient's serum with the use of the GeneXpert platform (Xpert Ebola Assay, Cepheid) (Table 1), and EVD was diagnosed.

We initiated treatment with the experimental mAb114 monoclonal antibody<sup>7</sup> on June 16, 2019, under the Monitored Emergency Use of Unregistered and Investigational Interventions protocol.<sup>8</sup> In addition, we provided standard supportive care that included an antibiotic agent (intravenous ceftriaxone), an antimalarial agent (artesunate–amodiaquine), a proton-pump inhibitor (omeprazole), and magnesium supplementation. The patient was discharged from the ETU on June 29 after two consecutive negative results on a polymerase-chain-reaction assay (Fig. 1 and Table 1). On August 27, a semen sample was collected as part of the national program to monitor EVD survivors, and the test result was negative for EBOV RNA (Table 1). The patient did not undergo follow-up for additional semen testing.

On November 25, 2019, a total of 149 days

after discharge from the ETU, headache, asthenia, myalgia, polyarthralgia, and anorexia developed in the patient. He was seen at a local health center, where he received unspecified treatment. On November 26, he had nausea, diarrhea, melena, jaundice, conjunctival injection, epistaxis, and abdominal, chest, and spinal pain. The patient consulted a traditional practitioner, was hospitalized for 2 days, and received unspecified treatment. After the symptoms increased in severity, community members alerted the EVD response team, and 8 days after the onset of illness (on December 3), the patient was transferred to the ETU in Mangina. He had transient loss of consciousness soon after arrival. Initial clinical examination revealed a bedridden patient with pale palpebral conjunctiva, icteric bulbar conjunctiva, a soft abdomen with epigastric tenderness, swelling of the left arm, and tender ecchymosis and bleeding at a venipuncture site. The vital signs on arrival included a heart rate of 91 beats per minute, respiratory rate of 26 breaths per minute, and blood pressure of 100/60 mm Hg; the oxygen saturation as measured by pulse oximetry was 99%. The results of rapid diagnostic tests to detect human immunodeficiency virus (HIV) infection (Determine, Abbott) and malaria were negative. A serum sample obtained on December 3 tested positive for EBOV RNA (Table 1),



and he received a diagnosis of EVD for the second time in 6 months.

The patient received antibiotics (ceftriaxone, metronidazole, and amoxicillin–clavulanate), an antimalarial agent (artesunate–amodiaquine), a proton-pump inhibitor (omeprazole), an antiemetic agent (ondasetron), and rehydration fluid. On December 4, 2019, his condition deteriorated, with loss of consciousness, gingivorrhagia, anemia, and dyspnea associated with painful hepatomegaly on palpation. Clinical laboratory tests revealed acute kidney injury, liver injury (elevated hepatic aminotransferase levels and hyperbilirubinemia), hyponatremia, severe hypoalbuminemia, and a markedly elevated C-reactive protein level; all these findings were consistent with multiorgan failure or dysfunction (Table S1 in the Supplementary Appendix, available with the full text of this article at NEJM.org).

The patient received oxygen and a blood transfusion. Despite this treatment, acute respiratory distress and coma developed, and the patient died. A postmortem oral swab obtained on December 5, 2019, was positive for EBOV RNA (Table 1).

An epidemiologic investigation was initiated. Contact tracers connected the patient to 29 per-

sons with EVD who had had exposure to the patient while he was symptomatic in the community or while he had visited local health clinics for treatment. An additional 62 cases resulted from onward transmission from these initial contacts. Overall, the cases spanned six health zones over 4 months.

**MOLECULAR AND SEROLOGIC INVESTIGATIONS**

We initiated a genomic investigation to support the epidemiologic findings and differentiate between relapse and reinfection in this patient (i.e., to differentiate between recurrence of the initial disease that had occurred in June 2019 and reinfection through an active transmission chain in November 2019). We sequenced serum samples obtained during the first infection on June 15 (sample d1) and during the second infection on December 3 (sample d171), as well as a postmortem oral swab (sample d173). We also sequenced diagnostic samples obtained from 72 epidemiologically linked cases (Table S2). Our comparison of these samples with previously sequenced samples from the North Kivu outbreak revealed that all our patient’s samples (samples d1, d171, and d173) and those from the 72 epidemiologi-

cally linked cases shared a unique mutation in the glycoprotein (G6800A/E258K) that separated these sequences from other sequences in the outbreak (Fig. S1A). The samples obtained during the second infection (samples d171 and d173) and those from the 72 epidemiologically linked cases shared two unique mutations (T5578C non-coding and glycoprotein A6867G/E280G) that genetically linked the cluster and indicated that the sample d1 sequence was ancestral to the relapse cluster (Fig. 2A and Fig. S1B).

We performed a Bayesian phylodynamic analysis to reconstruct a time-resolved phylogeny with the use of all the North Kivu outbreak EBOV genomes with at least 95% coverage (Fig. 2B). We determined the overall rate of evolution for the EBOV Ituri variant in the ongoing North Kivu outbreak to be  $0.8 \times 10^{-3}$  substitutions per genomic site per year (95% highest posterior density interval,  $0.7 \times 10^{-3}$  to  $0.9 \times 10^{-3}$ ), which is consistent with the rates observed during the 2013–2016 West African epidemic.<sup>9</sup> The branch leading to sample d171 had a reduced rate of  $0.2 \times 10^{-3}$  substitutions per genomic site per year (95% highest posterior density interval,  $0.1 \times 10^{-3}$  to  $0.3 \times 10^{-3}$ ) (Fig. 2B and Fig. S2). This slowing of the molecular clock was consistent with persistent EBOV infection.<sup>10–13</sup> The median estimated time to the most recent common ancestor (TMRCA) of all relapse clade genomes was November 7, 2019 (95% highest posterior density interval, October 15 to November 24), which is consistent with recurrence of symptoms in the patient on November 25 and with onward transmission shortly after. Taken together, our phylogenetic and epidemiologic data show that the patient's second EVD episode was the result of EVD relapse from his initial EBOV infection and was not due to reinfection.

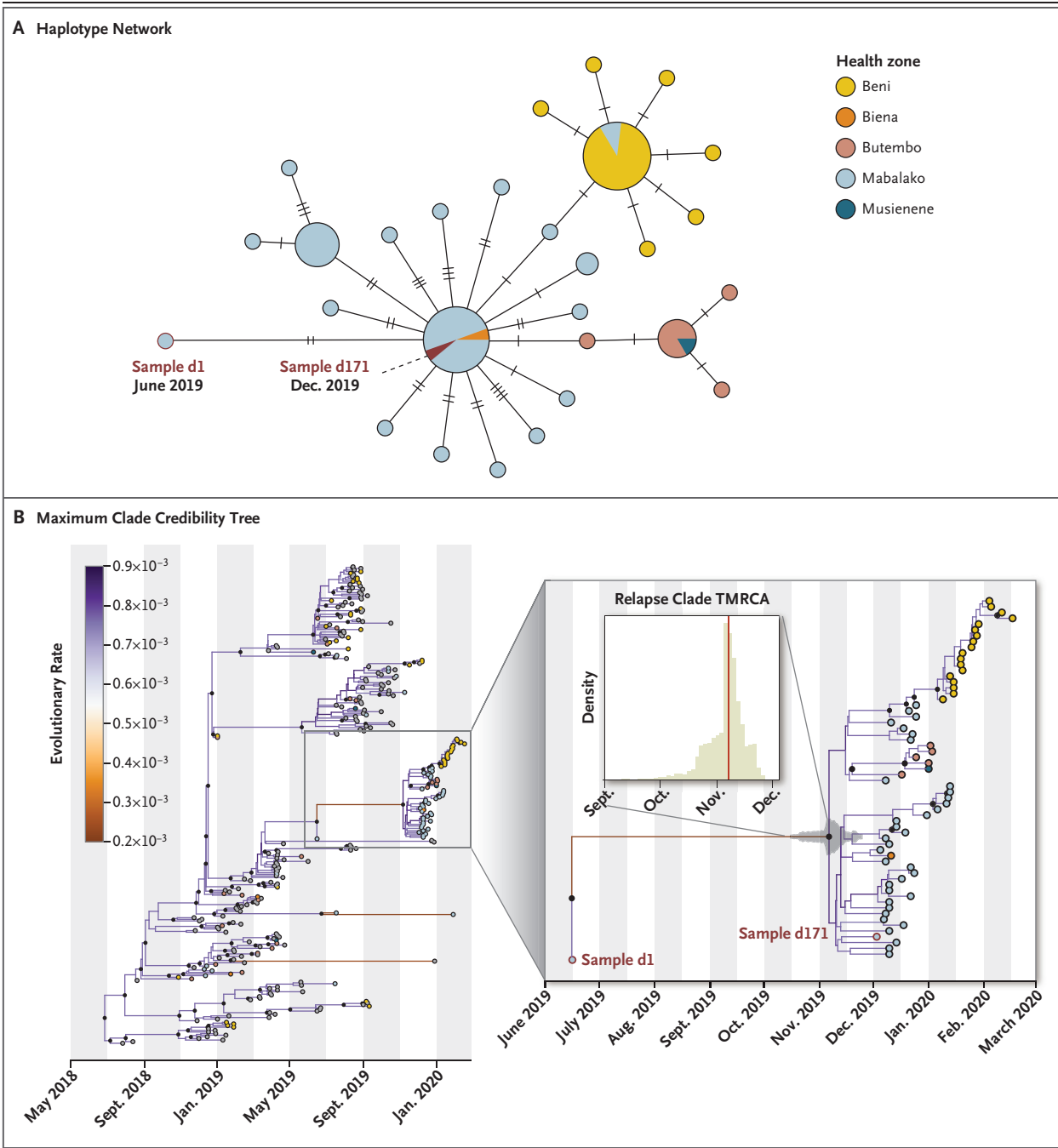
To investigate the potential failure of vaccine protection at the patient's initial clinical presentation and relapse, we assayed the patient's samples for anti-EBOV glycoprotein IgG antibody titers. We were unable to detect anti-EBOV glycoprotein IgG in sample d1, but we detected high titers in a sample obtained 14 days later (in sample d14) and in a sample obtained 8 days after the onset of relapse-associated illness (sample d171) (Table 1 and Fig. S3). On the basis of the half-life of mAb114 (approximately 24 days),<sup>14</sup> the sample d14 results partially indicated detec-

tion of residual mAb114. However, more than 99% of mAb114 would have been cleared when sample d171 was obtained. The higher titer in sample d171 probably resulted from recall antibody responses to the recurring infection, primary antibody responses to the recurring infection, or both, in the patient. Thus, the relapse is not explained by a failed antibody response, and some other immune deficit (acquired or primary immune deficiency) may have played a role. Given the patient's negative HIV test, we investigated the possibility of primary immune deficiencies to explain the patient's course of disease and vaccine failure. We sequenced the patient's exome, but no variants that were known to or likely to cause primary immune deficiencies were detected (Table S3 and Fig. S4).

Although the location of the mutations (G6800A/E258K and A6867G/E280G) in the viral envelope glycoprotein are distant from the mAb114 binding site,<sup>7</sup> it is reasonable to consider whether these mutations resulted from viral escape from mAb114 treatment. To test for this possibility, we evaluated the ability of mAb114 to neutralize viruses bearing the mutant glycoproteins (Table 1 and Fig. S5). The data showed nearly identical neutralization by mAb114 of both wild-type Ituri and the glycoprotein variant detected in our patient's viral genomes; thus, in vitro, the glycoprotein variation was independent of mAb114 selective pressures.

## DISCUSSION

We describe a case of acute EVD relapse that has led to human-to-human transmission. We were able to sequence EBOV genomes in samples obtained during the patient's first EVD episode (sample d1) and second EVD episode (sample d171), and we found that they differed by only two mutations. These findings indicate a relapse of the initial EBOV infection. Our time-aware phylodynamic analysis showed that between samples d1 and d171, the virus evolved at a rate that was one quarter of that in the overall outbreak; this finding indicates relapse from a persistent EBOV infection. The median TMRCA for the relapse clade of November 7, 2019, is an estimate of the earliest time point when the virus probably exited persistence and resumed a normal rate of replication. If we assume a presymptom-



atic incubation period of 2 to 21 days, this date is consistent with the recurrence of EVD symptoms on November 25 reported by the patient.

Although the underlying mechanism of relapse associated with EBOV persistence in convalescent patients remains unclear, three patients with documented cases of relapse (including the

patient reported here) all received antibody-based therapy as part of the treatment for the initial infection. The Pamoja Tulinde Maisha (PALM [“Together Save Lives” in the Kiswahili language]) randomized, controlled trial showed the benefits of monoclonal antibody-based therapy.<sup>15</sup> Questions remain as to whether passive

**Figure 2 (facing page). Epidemiologic and Phylogenetic Analysis of the Case of Relapse and Linked Cases.**

We initiated investigations that showed that the patient had had a relapse of acute Ebola virus disease (EVD) that led to a transmission chain resulting in 91 cases across six health zones in the Democratic Republic of Congo (DRC). Panel A shows a haplotype network of the case of EVD relapse and 72 epidemiologically linked cases across five of the six health zones for which we had obtained sequence data from samples. The size of the circles is proportional to the number of cases, and the hatch marks indicate the number of substitutions along each edge. Panel B shows a maximum clade credibility tree with a two-rate clock model in which branches indicating persistent infection were allowed to have a rate of evolution that was different than that in the rest of the tree. The tree was estimated with the use of 297 sequenced isolates with greater than 95% coverage from the current North Kivu EVD outbreak in the DRC; these isolates were differentiated according to health zone. The branch colors indicate the evolutionary rate in substitutions per genomic site per year. Black circles indicate internal nodes of the tree with a posterior probability of greater than 50%. An enlarged view of the time tree shows the first episode (sample d1) and second episode (sample d171) of EVD in the patient with relapse, as well as 61 viral genomes sampled from epidemiologically linked cases. The 95% highest posterior density of the estimated time to the most recent common ancestor (TMRCA) for the relapse clade is shown. The median TMRCA was estimated to be November 7, 2019 (95% highest posterior density interval, October 15 to November 24). The evolutionary rate between samples d1 and d171 is four times lower than that in the overall outbreak. Data are from Nextstrain (<https://nextstrain.org/community/inrb-drc/ebola-nord-kivu>) and were released on the National Center for Biotechnology Information GenBank database.

immunotherapy could, in rare instances, be associated with viral relapse, as has been historically documented in patients with Argentine hemorrhagic fever treated with convalescent plasma.<sup>16</sup> Two previous patients with EVD relapse were repatriated persons who had severe EVD and received aggressive supportive care along with convalescent plasma and experimental therapeutic agents.<sup>3,17,18</sup> Both patients recovered, and during convalescence, organ-specific inflammatory syndromes (uveitis and meningoencephalitis) developed that warranted additional treatment.<sup>3,4</sup>

The major and very consequential distinction between our patient and previous patients with relapse is the extent of onward transmission. Our patient was symptomatic in the community for 8 days and visited two health care centers.

Precautions were not taken to prevent the spread of infection, and there were 29 directly linked cases of EVD. This case report provides an unfortunate proof-of-principle that survivors of EVD with relapse syndromes, like patients with acute EVD, can transmit EBOV.

To investigate why the patient was not protected from infection after his vaccination in December 2018, we tested a serum sample obtained during his initial EVD episode in June 2019 for anti-EBOV glycoprotein IgG titers, but we detected none (Table 1). Given that we found no signs of immune deficiencies, this probably was an incidence of temporal or complete vaccine failure. This finding is in line with those of other studies showing that up to 10% of patients with EVD had been fully vaccinated for at least 10 days before admission to the ETU.<sup>15</sup> In addition, serologic data from the Partnership for Research on Ebola Virus in Liberia (PREVAIL) trials involving more than 700 participants who had received rVSV-ZEBOV showed that in approximately 20% of vaccinated persons, positive Ebola IgG binding titers did not develop 1 month after vaccination.<sup>19,20</sup> Combined, these findings arouse concerns about the true effectiveness of rVSV-ZEBOV, which has been estimated to be 100% in the Guinean “Ebola ça suffit!” trial<sup>21</sup> and 97.5% in the preliminary report by the World Health Organization on the use of this vaccine in the DRC.<sup>22</sup>

An alternative hypothesis for the patient’s lack of protection during relapse, despite his anamnestic response, is potential viral escape during persistence. The E280G glycoprotein mutation that developed during EBOV persistence may have allowed a replication advantage or immune escape, but our data show that the mutated glycoproteins retained sensitivity to the treatment antibody mAb114. Alternatively, the mutation may simply be coincidental, and viral persistence may have arisen with infection of an immunoprivileged compartment. The other noted mutation in this patient was in a noncoding region, and little is known about the effect of an intragenic region on gene expression in EBOV. Furthermore, our patient did not have overt evidence of chronic diseases associated with immunosuppression, and our whole-exome sequencing analysis did not reveal genomic variants that are known to or likely to cause primary immune

deficiencies, although primary immunodeficiency cannot be fully ruled out.

During the North Kivu outbreak in the DRC, the provision of effective therapeutic agents for EVD and supportive care have helped more than 1000 patients to leave ETUs as survivors (who are aptly called “vainqueurs” or *victors*, in French).<sup>15</sup> Despite the positive effect these countermeasures may have had on individual lives, the overall case fatality rate of approximately 66% is similar to those observed during previous outbreaks.<sup>23</sup> This high case fatality rate can be partially attributed to the fact that the outbreak occurred in a conflict zone, with frequent disruptions to all aspects of the outbreak response.<sup>24,25</sup> This case report shows the need for continued monitoring of vaccine and therapeutic interventions and the power of having locally available genomic capabilities to support the outbreak response. Relapse of EVD appears to be a rare event; however, relapse, like sexual transmission, should be recognized as a mechanism for onward transmission from persons with persistent infections. More

data are needed to understand the mechanism and risk factors of EVD relapse in order to prevent future transmission events and protect patients as well as their families and communities.

The content of this article does not necessarily reflect the views or policies of the Department of Health and Human Services, the U.S. Government, or the institutions or companies affiliated with the authors, nor does mention of trade names, commercial products, or organizations imply endorsement by the U.S. Government.

Supported by a grant for sequencing activities (INV-004176, to Ms. Pratt) from the Bill and Melinda Gates Foundation, a grant (DGE-1256082, to Dr. Black) from the National Science Foundation Graduate Research Fellowship Program, Pew Biomedical Scholarships to Drs. Bedford and Andersen, grants (NIH R35 GM119774-01, to Dr. Bedford and NIH U19AI135995, U01AI1151812, and UL1TR002550, to Dr. Andersen) from the National Institutes of Health (NIH), a contract (75N91019D00024, task order no. 75N91019F00130, to Dr. Crozier) from the National Cancer Institute, a grant (NIH/CRDF Global FOGX-190402-1, to Dr. Bedford) for computational infrastructure and in-country training from the Fogarty International Center of the NIH, and a grant (INV-003565, to Dr. Bedford) from the Bill and Melinda Gates Foundation.

Disclosure forms provided by the authors are available with the full text of this article at NEJM.org.

A data sharing statement provided by the authors is available with the full text of this article at NEJM.org.

We thank Lillian K. Jensen for her support with graphic design.

#### APPENDIX

The authors' full names and academic degrees are as follows: Placide Mbala-Kingebeni, M.D., Ph.D., Catherine Pratt, M.Sc., Mbusa Mutafali-Ruffin, M.D., Matthias G. Pauthner, Ph.D., Faustin Bile, M.D., Antoine Nkuba-Ndaye, M.D., Allison Black, Ph.D., Eddy Kinganda-Lusamaki, M.D., Martin Faye, Ph.D., Amuri Aziza, M.Sc., Moussa M. Diagne, Ph.D., Daniel Mukadi, M.D., Bailey White, B.Sc., James Hadfield, Ph.D., Karthik Gangavarapu, B.Pharm., Nella Bisento, M.Sc., Donatien Kazadi, M.D., Bibiche Nsunda, B.Sc., Marceline Akonga, B.Sc., Olivier Tshiani, M.D., John Misasi, M.D., Aurelie Ploquin, Ph.D., Victor Epaso, M.D., Emilia Sana-Paka, M.D., Yannick Tutu Tshia N'kasar, M.D., Fabrice Mambu, M.D., Francois Edidi, M.D., Meris Matondo, M.D., Junior Bula Bula, M.D., Boubacar Diallo, M.D., Mory Keita, M.D., Marie R.D. Belizaire, M.D., Ibrahima S. Fall, Ph.D., Abdoulaye Yam, M.D., Sabue Mulangu, M.D., Anne W. Rimion, Ph.D., M.P.H., Elias Salfati, Ph.D., Ali Torkamani, Ph.D., Marc A. Suchard, M.D., Ph.D., Ian Crozier, M.D., Lisa Hensley, Ph.D., Andrew Rambaut, Ph.D., Ousmane Faye, Ph.D., Amadou Sall, Ph.D., Nancy J. Sullivan, Ph.D., Trevor Bedford, Ph.D., Kristian G. Andersen, Ph.D., Michael R. Wiley, Ph.D., Steve Ahuka-Mundeye, M.D., Ph.D., and Jean-Jacques Muyembe Tamfum, M.D., Ph.D.

The authors' affiliations are as follows: the Institut National de Recherche Biomédicale (P.M.-K., A.N.-N., E.K.-L., A.A., D.M., N.B., D.K., B.N., M.A., O.T., S.M., S.A.-M., J.-J.M.T.), the University of Kinshasa (P.M.-K., A.N.-N., F.M., F.E., M.M., J.B.B., S.A.-M., J.-J.M.T.), and Ministère de la Santé (F.B., V.E., E.S.-P., Y.T.T.N.) — all in Kinshasa, Democratic Republic of Congo; the University of Nebraska Medical Center, Omaha (C.P., B.W., M.R.W.); International Medical Corps (M.M.-R.) and the University of California, Los Angeles (A.W.R., M.A.S.), Los Angeles, and the Scripps Research Institute, La Jolla (M.G.P., K.G., E.S., A.T., K.G.A.) — all in California; the Fred Hutchinson Cancer Research Center, Seattle (A.B., J.H., T.B.); the Institut Pasteur de Dakar, Dakar, Senegal (M.F., M.M.D., O.F., A.S.); the Vaccine Research Center, National Institutes of Health, Bethesda (J.M., A.P., N.J.S.), and the Clinical Monitoring Research Program Directorate, Frederick National Laboratory for Cancer Research (I.C.), and the Integrated Research Facility at Fort Detrick, National Institutes of Health (L.H.), Frederick — all in Maryland; the World Health Organization, Geneva (B.D., M.K., M.R.D.B., I.S.F., A.Y.); and the University of Edinburgh, Edinburgh, United Kingdom (A.R.).

#### REFERENCES

- Dowell SF, Mukunu R, Ksiazek TG, Khan AS, Rollin PE, Peters CJ. Transmission of Ebola hemorrhagic fever: a study of risk factors in family members, Kikwit, Democratic Republic of the Congo, 1995. *Commission de Lutte contre les Epidémies à Kikwit. J Infect Dis* 1999;179:Suppl 1: S87-S91.
- Subissi L, Keita M, Mesfin S, et al. Ebola virus transmission caused by persistently infected survivors of the 2014-2016 outbreak in West Africa. *J Infect Dis* 2018; 218:Suppl 5:S287-S291.
- Jacobs M, Rodger A, Bell DJ, et al. Late Ebola virus relapse causing meningoencephalitis: a case report. *Lancet* 2016;388: 498-503.
- Varkey JB, Shantha JG, Crozier I, et al. Persistence of Ebola virus in ocular fluid during convalescence. *N Engl J Med* 2015; 372:2423-7.
- Mbala-Kingebeni P, Aziza A, Di Paola N, et al. Medical countermeasures during the 2018 Ebola virus disease outbreak in the North Kivu and Ituri Provinces of the Democratic Republic of the Congo: a rapid genomic assessment. *Lancet Infect Dis* 2019;19:648-57.
- Regules JA, Beigel JH, Paolino KM, et al. A recombinant vesicular stomatitis virus ebola vaccine. *N Engl J Med* 2017; 376:330-41.
- Misasi J, Gilman MSA, Kanekiyo M,

- et al. Structural and molecular basis for Ebola virus neutralization by protective human antibodies. *Science* 2016;351:1343-6.
8. Guidance for managing ethical issues in infectious disease outbreaks. Geneva: World Health Organization, 2016.
  9. Holmes EC, Dudas G, Rambaut A, Andersen KG. The evolution of Ebola virus: insights from the 2013-2016 epidemic. *Nature* 2016;538:193-200.
  10. Arias A, Watson SJ, Asogun D, et al. Rapid outbreak sequencing of Ebola virus in Sierra Leone identifies transmission chains linked to sporadic cases. *Virus Evol* 2016;2(1):vew016.
  11. Blackley DJ, Wiley MR, Ladner JT, et al. Reduced evolutionary rate in reemerged Ebola virus transmission chains. *Sci Adv* 2016;2(4):e1600378.
  12. Mate SE, Kugelman JR, Nyenswah TG, et al. Molecular evidence of sexual transmission of Ebola virus. *N Engl J Med* 2015;373:2448-54.
  13. Whitmer SLM, Ladner JT, Wiley MR, et al. Active Ebola virus replication and heterogeneous evolutionary rates in EVD survivors. *Cell Rep* 2018;22:1159-68.
  14. Gaudinski MR, Coates EE, Novik L, et al. Safety, tolerability, pharmacokinetics, and immunogenicity of the therapeutic monoclonal antibody mAb114 targeting Ebola virus glycoprotein (VRC 608): an open-label phase 1 study. *Lancet* 2019;393:889-98.
  15. Mulangu S, Dodd LE, Davey RT Jr, et al. A randomized, controlled trial of Ebola virus disease therapeutics. *N Engl J Med* 2019;381:2293-303.
  16. Maiztegui JI, Fernandez NJ, de Damielano AJ. Efficacy of immune plasma in treatment of Argentine haemorrhagic fever and association between treatment and a late neurological syndrome. *Lancet* 1979;2:1216-7.
  17. Connor MJ Jr, Kraft C, Mehta AK, et al. Successful delivery of RRT in Ebola virus disease. *J Am Soc Nephrol* 2015;26:31-7.
  18. Kraft CS, Hewlett AL, Koepsell S, et al. The use of TKM-100802 and convalescent plasma in 2 patients with Ebola virus disease in the United States. *Clin Infect Dis* 2015;61:496-502.
  19. Bolay FK, Grandits G, Lane HC, et al. PREVAIL I cluster vaccination study with rVSVΔG-ZEBOV-GP as part of a public health response in Liberia. *J Infect Dis* 2019;219:1634-41.
  20. Kennedy SB, Bolay F, Kieh M, et al. Phase 2 placebo-controlled trial of two vaccines to prevent Ebola in Liberia. *N Engl J Med* 2017;377:1438-47.
  21. Henao-Restrepo AM, Camacho A, Longini IM, et al. Efficacy and effectiveness of an rVSV-vectored vaccine in preventing Ebola virus disease: final results from the Guinea ring vaccination, open-label, cluster-randomised trial (Ebola Ça Suffit!). *Lancet* 2017;389:505-18.
  22. Preliminary results on the efficacy of rVSV-ZEBOV-GP Ebola vaccine using the ring vaccination strategy in the control of an Ebola outbreak in the Democratic Republic of the Congo: an example of integration of research into epidemic response. World Health Organization. April 12, 2019 (<https://www.who.int/csr/resources/publications/ebola/ebola-ring-vaccination-results-12-april-2019.pdf?ua=1>).
  23. Di Paola N, Sanchez-Lockhart M, Zeng X, Kuhn JH, Palacios G. Viral genomics in Ebola virus research. *Nat Rev Microbiol* 2020;18:365-78.
  24. Jombart T, Jarvis CI, Mesfin S, et al. The cost of insecurity: from flare-up to control of a major Ebola virus disease hotspot during the outbreak in the Democratic Republic of the Congo, 2019. *Euro Surveill* 2020;25(2):1900735.
  25. Wells CR, Pandey A, Ndeffo Mbah ML, et al. The exacerbation of Ebola outbreaks by conflict in the Democratic Republic of the Congo. *Proc Natl Acad Sci U S A* 2019;116:24366-72.

Copyright © 2021 Massachusetts Medical Society.