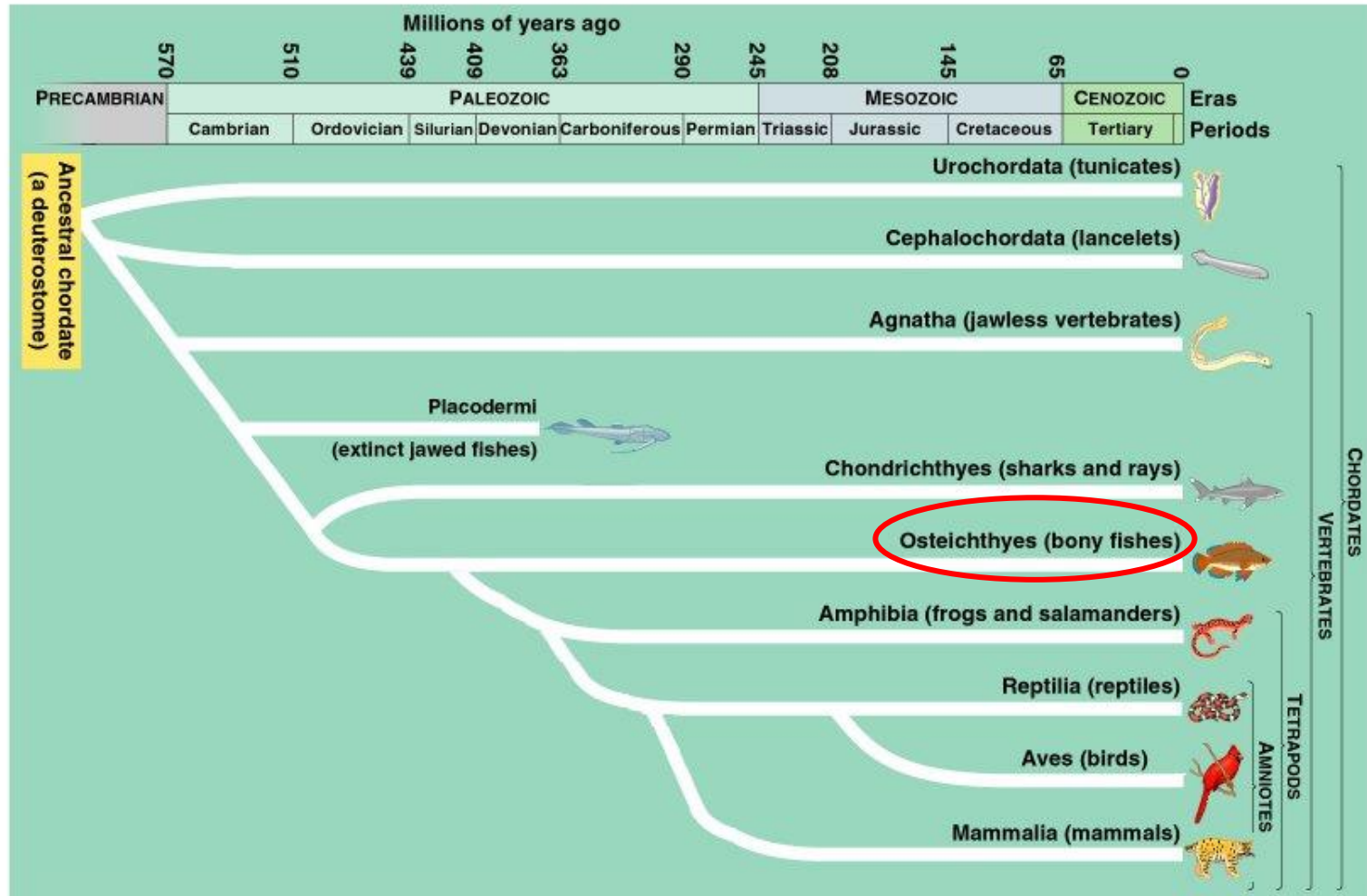
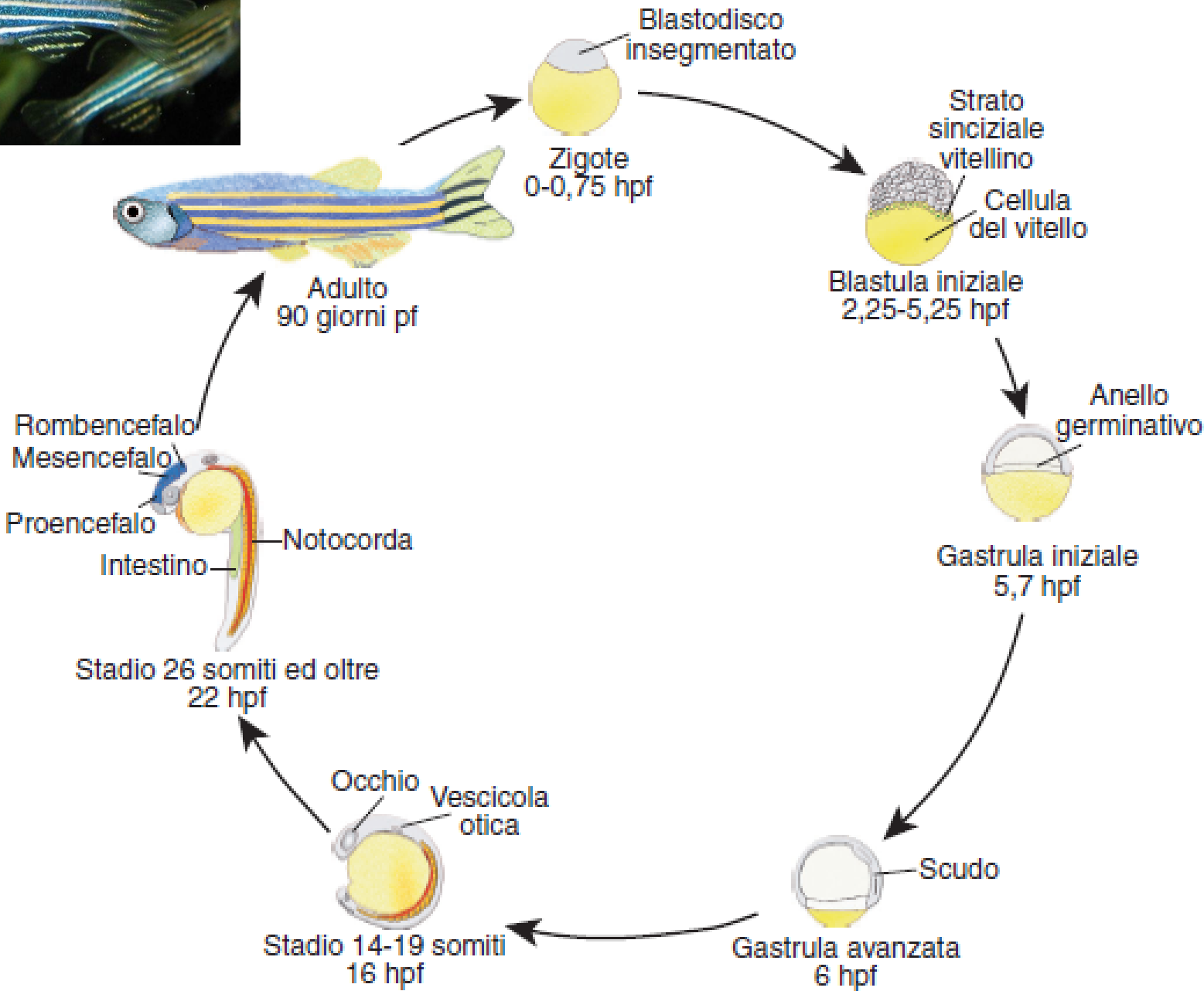
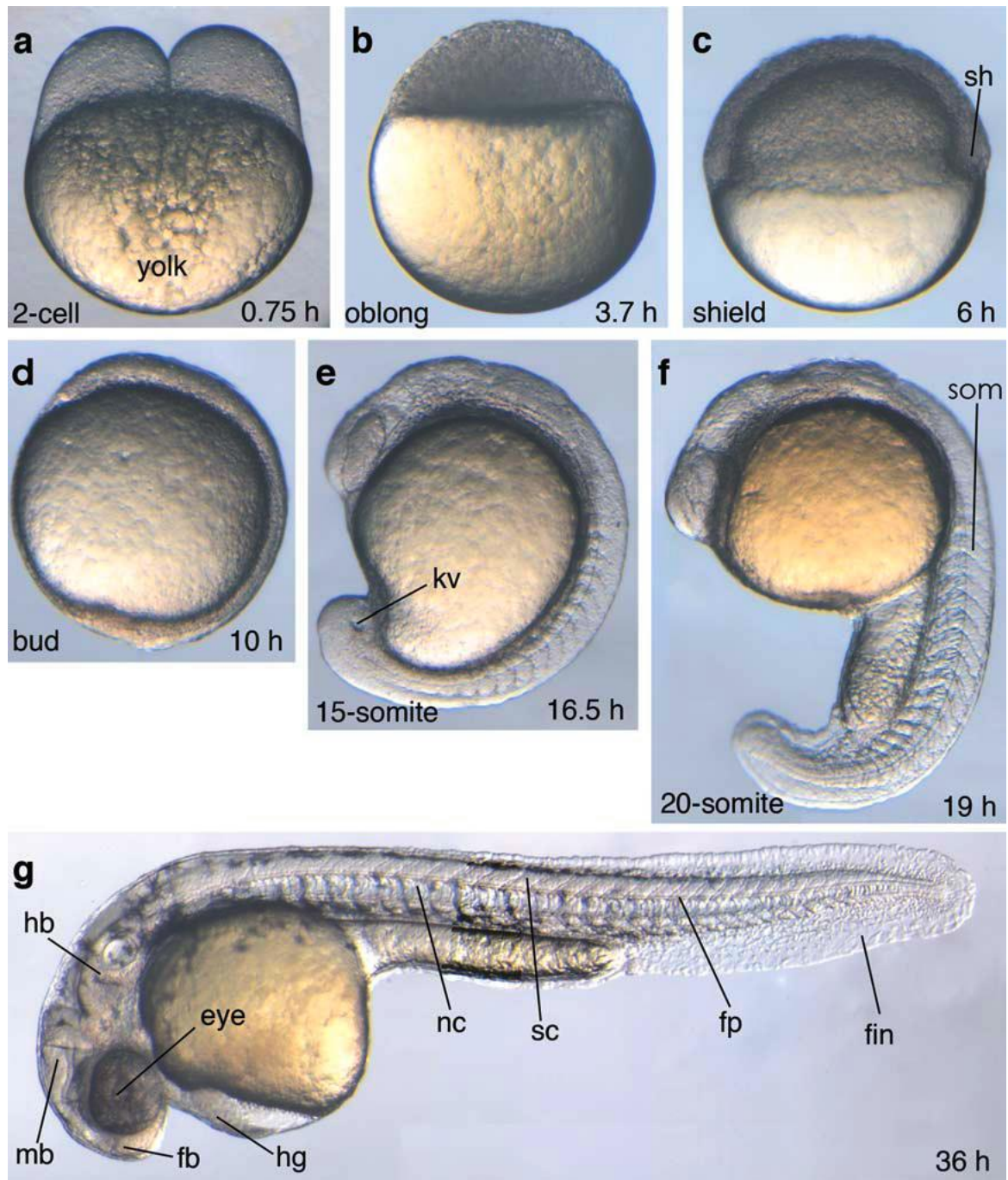


FILOGENESI DEI CORDATI



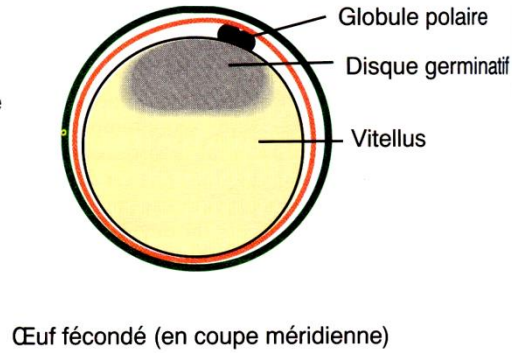
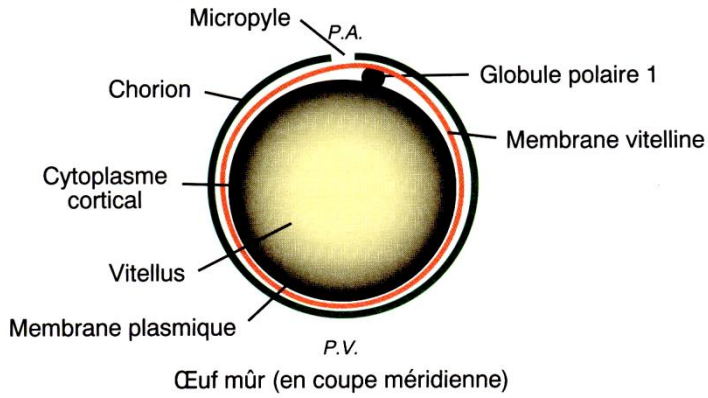
ZEBRAFISH (*Danio rerio*)



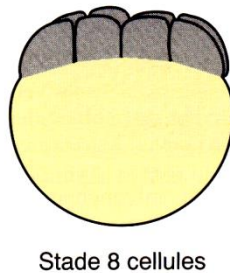
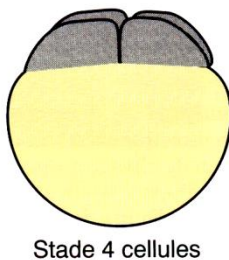
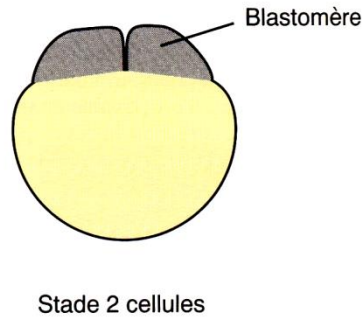
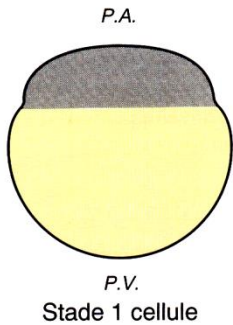


Premières étapes de la segmentation

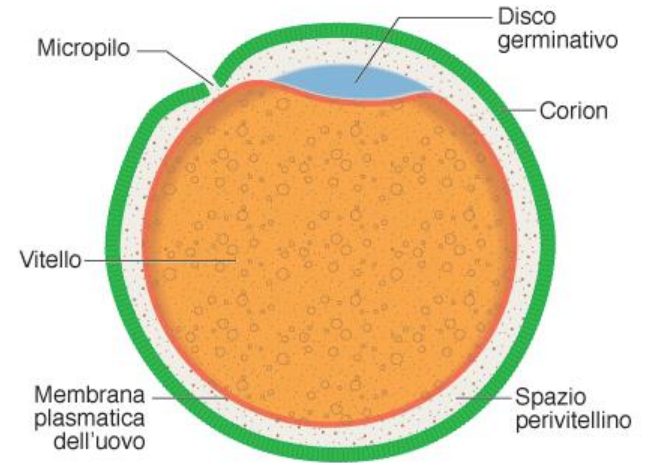
a) L'œuf insegmenté



b) La segmentation : premiers stades (vues latérales externes)

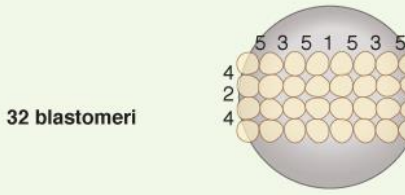
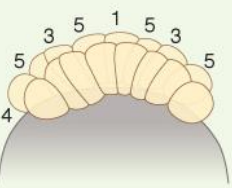
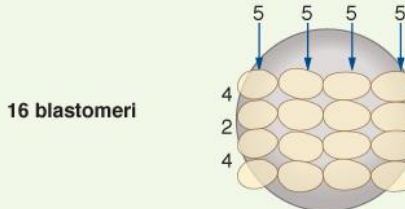
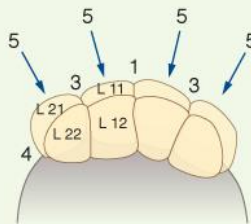
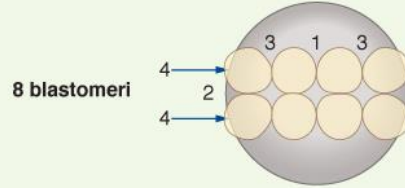
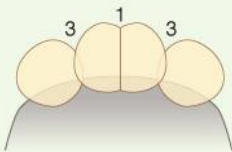
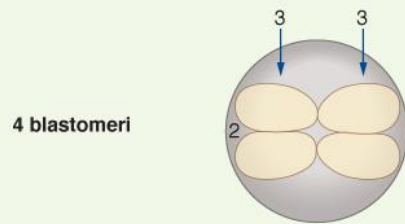
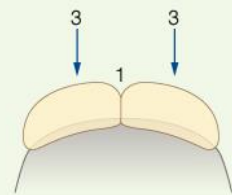
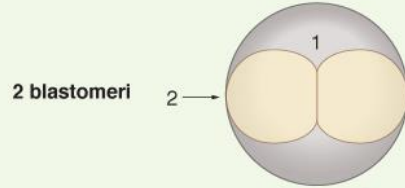
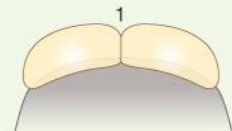
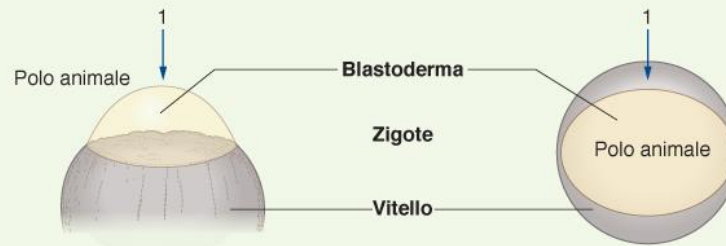


Uovo telolecitico



Segmentazione meroblastica discoidale

SEGMENTAZIONE MEROBLASTICA DISCOIDALE



SEGMENTAZIONE MEROBLASTICA DISCOIDALE

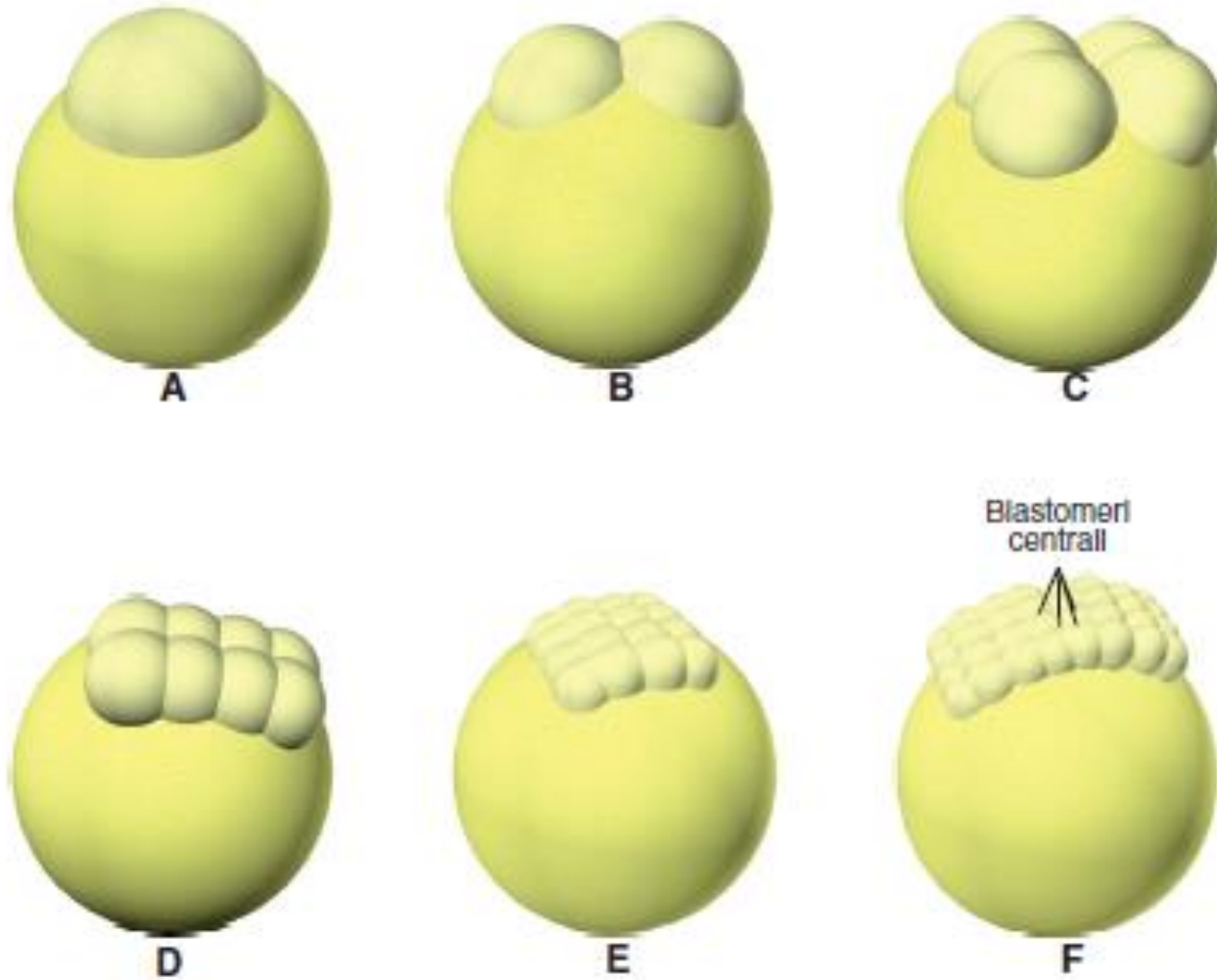
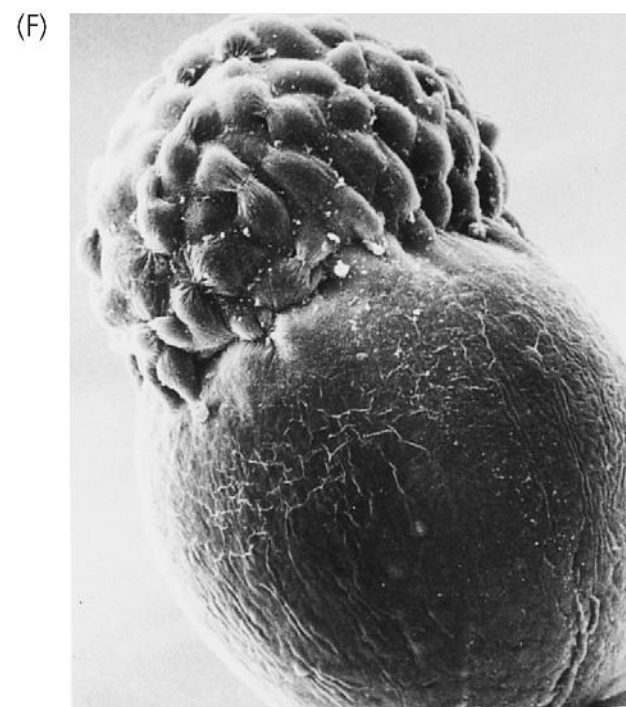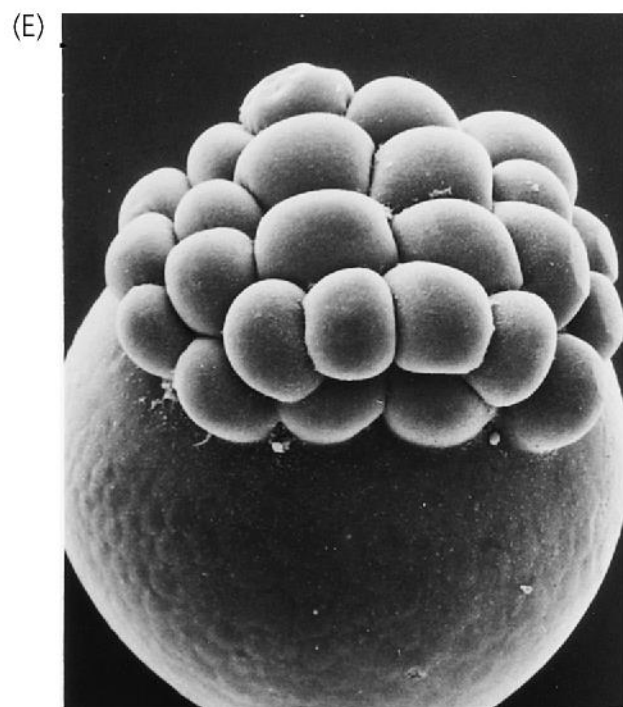
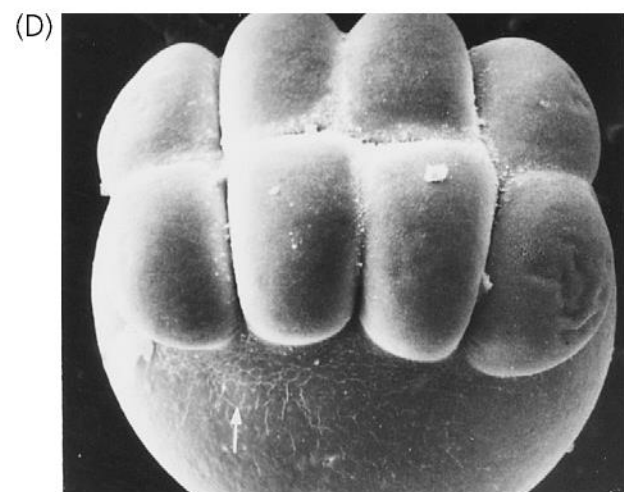
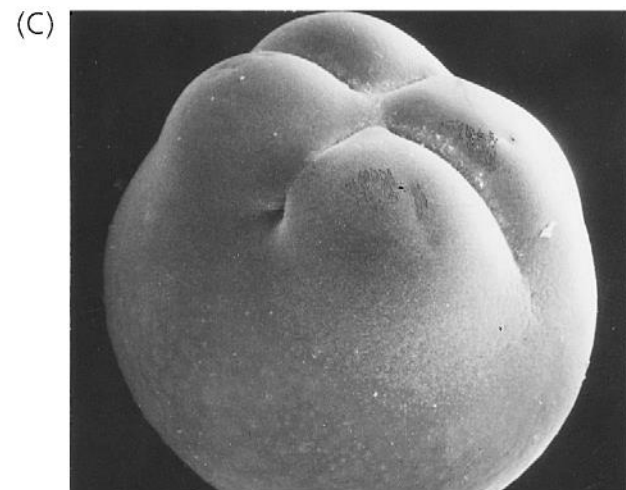
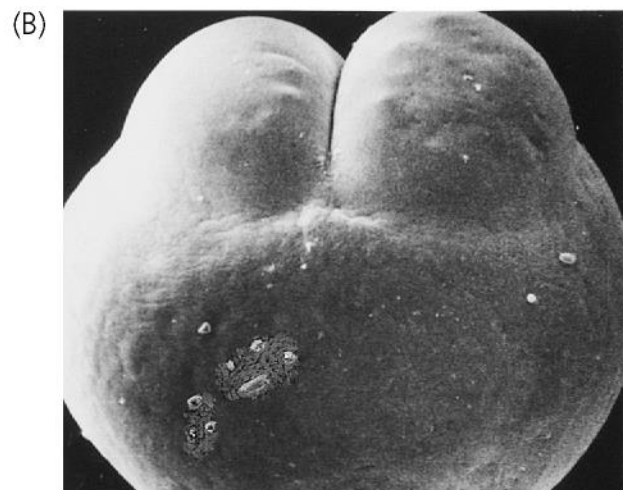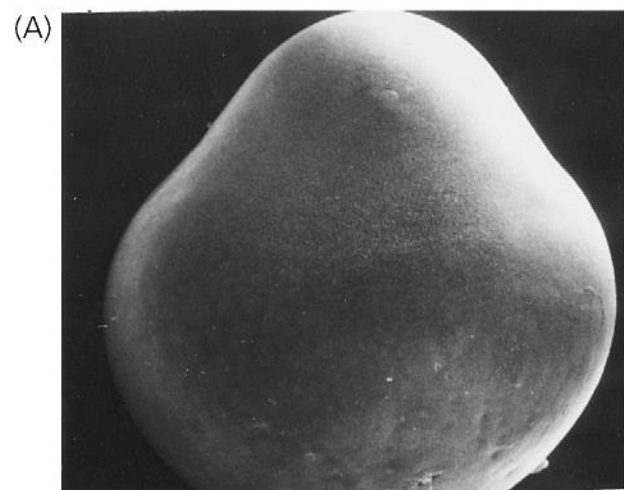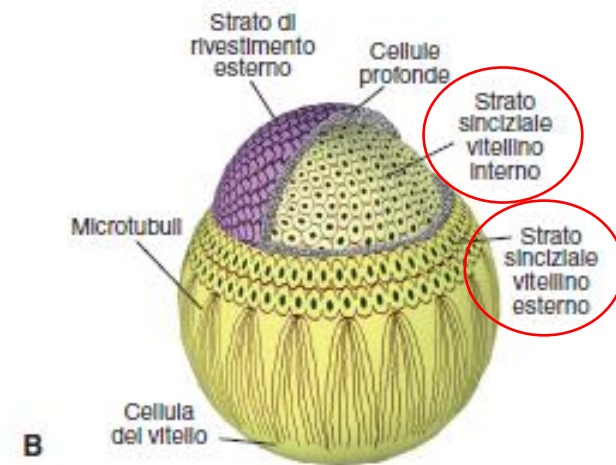
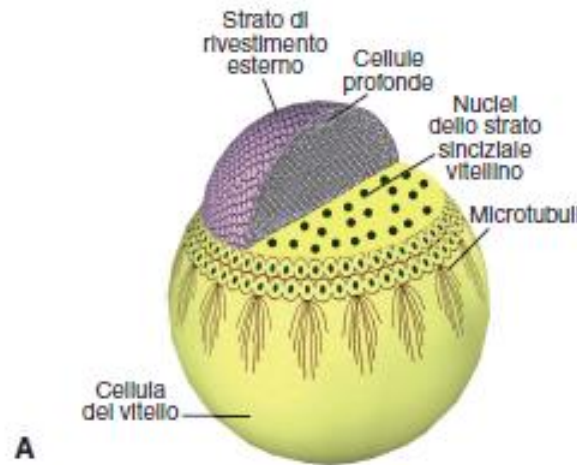
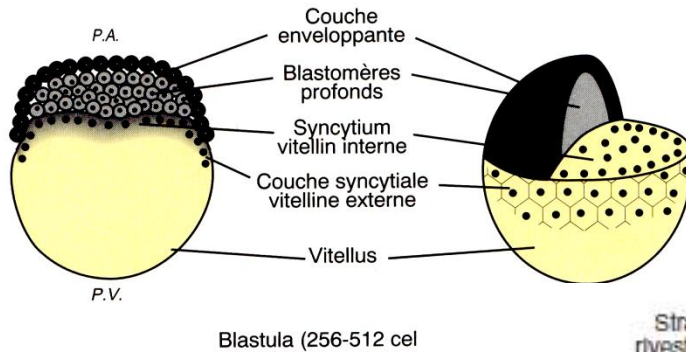
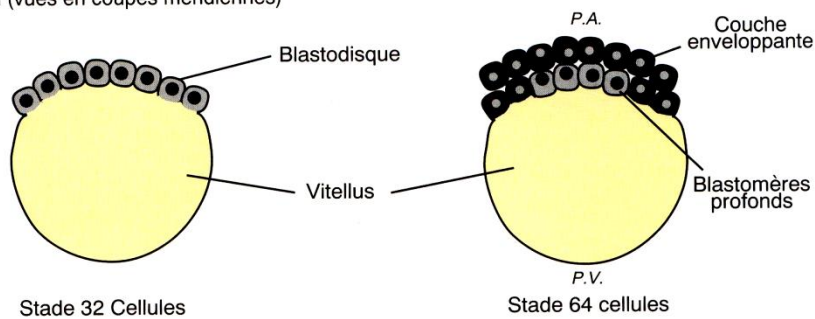


Figura 2

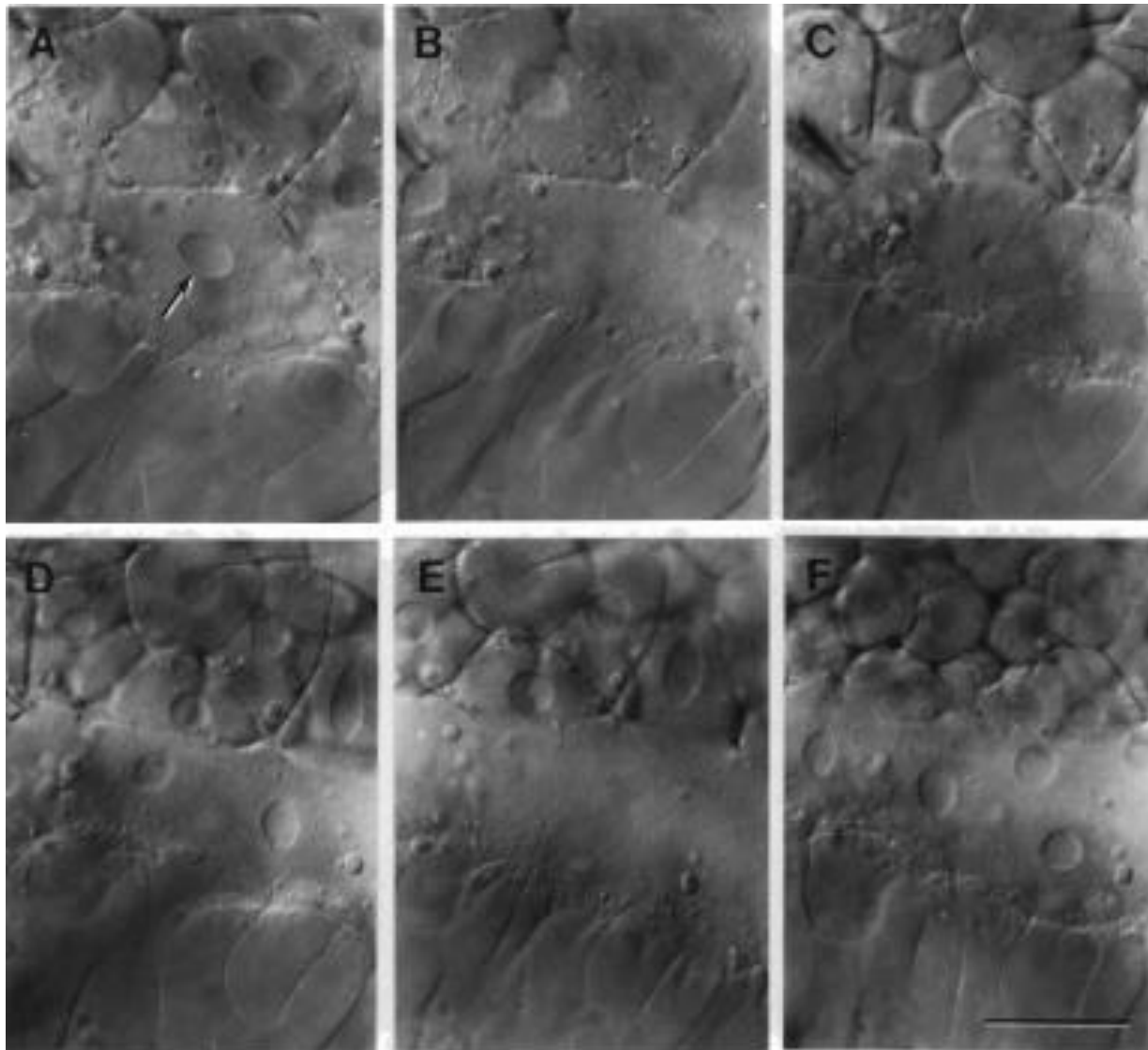


La segmentation (vues en coupes méridiennes)

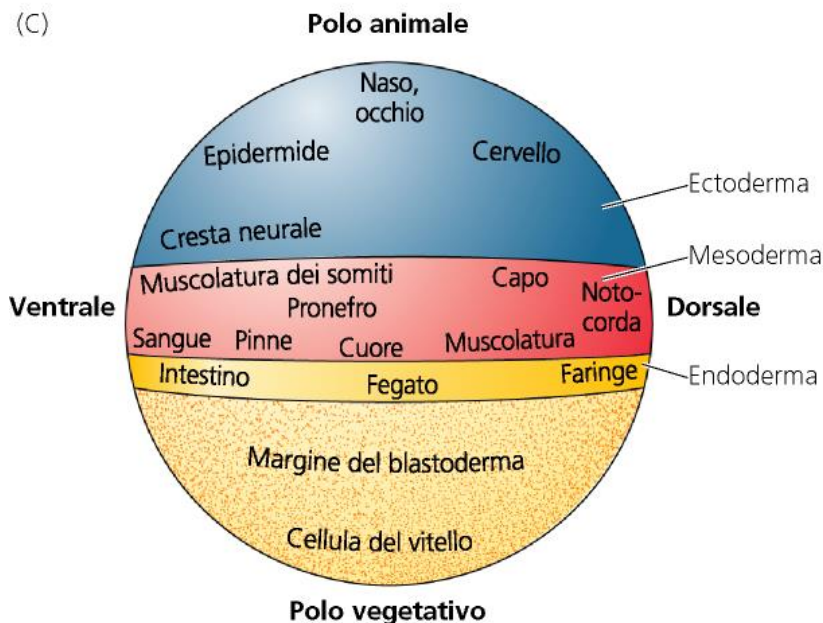
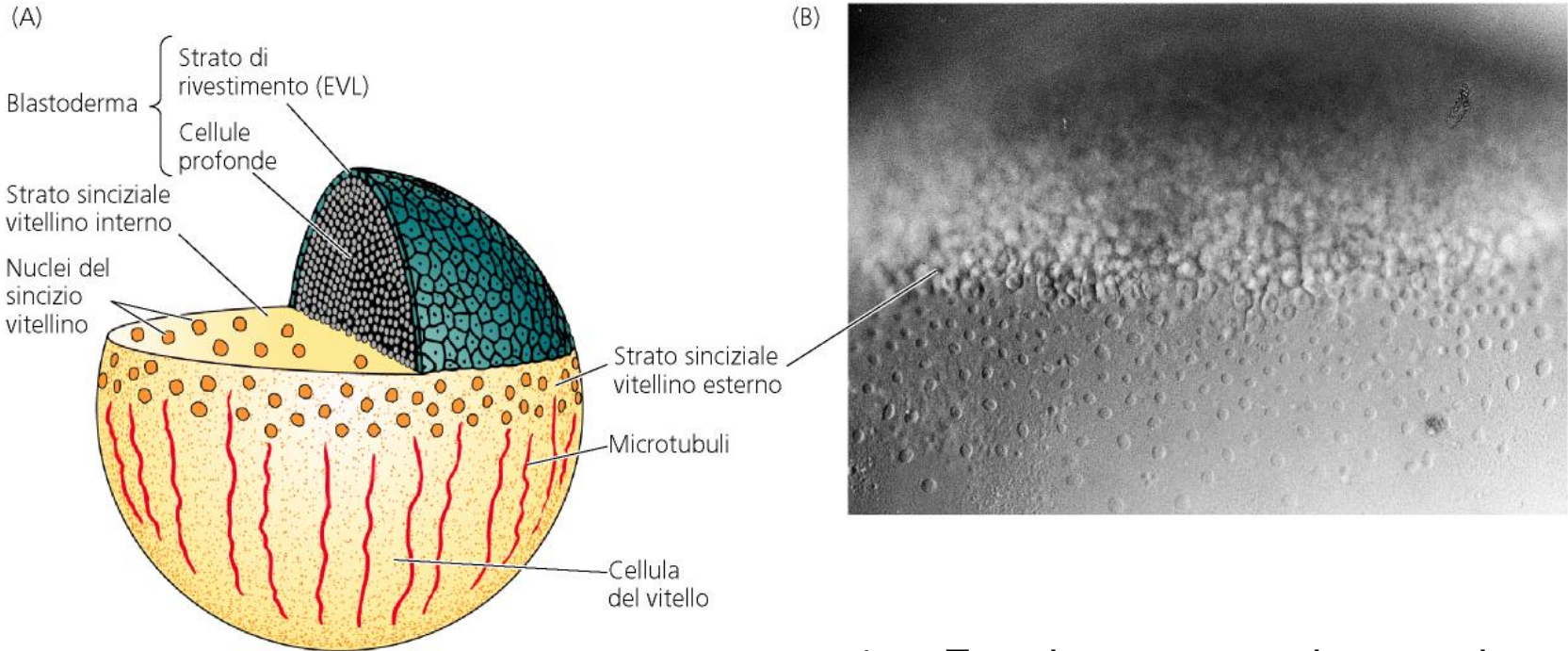


1. Rivestimento esterno: periderma
2. Blastomeri profondi: formano l'embrione
3. Sincizio vitellino

FORMAZIONE DELLO STRATO SINCIZIALE VITELLINO

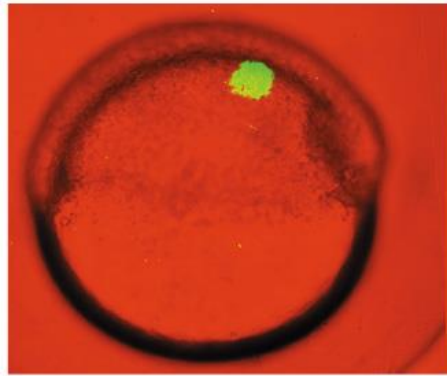


MAPPA DEI TERRITORI PRESUNTIVI NELLA BLASTULA DI ZEBRAFISH

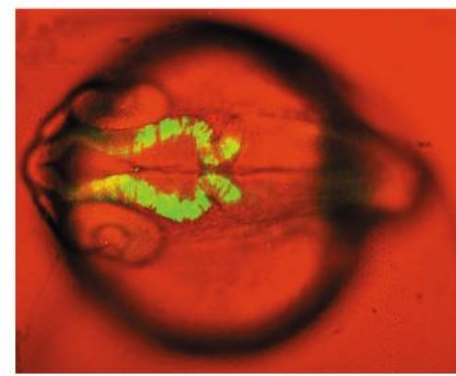


1. Ectoderma, mesoderma ed endoderma presuntivi allineati lungo l'asse animale vegetativo (ma la mappa è «compressa» nell'emisfero animale per via della segmentazione meroblastica).
2. Vicinanza dei territori presuntivi del cordomesoderma e del neuroectoderma sul futuro lato dorsale.

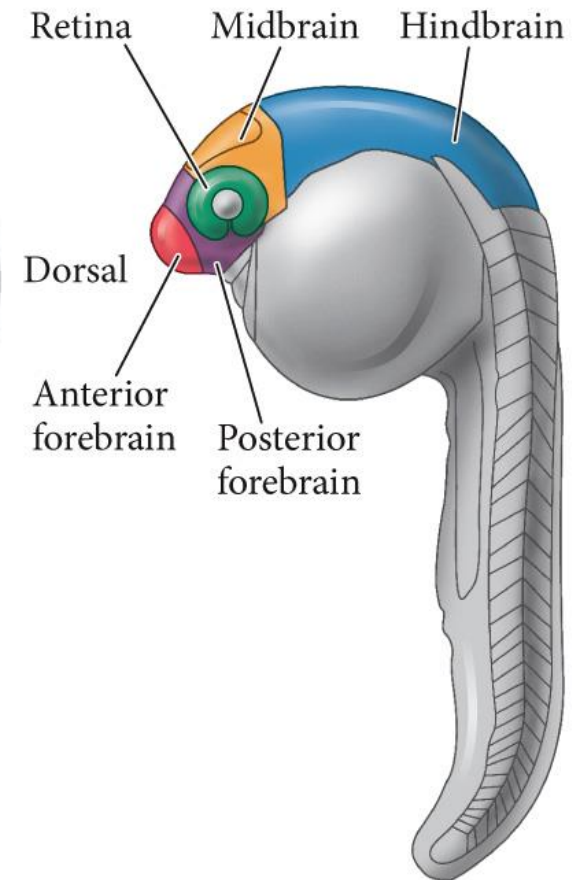
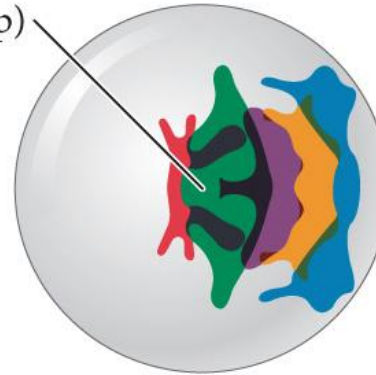
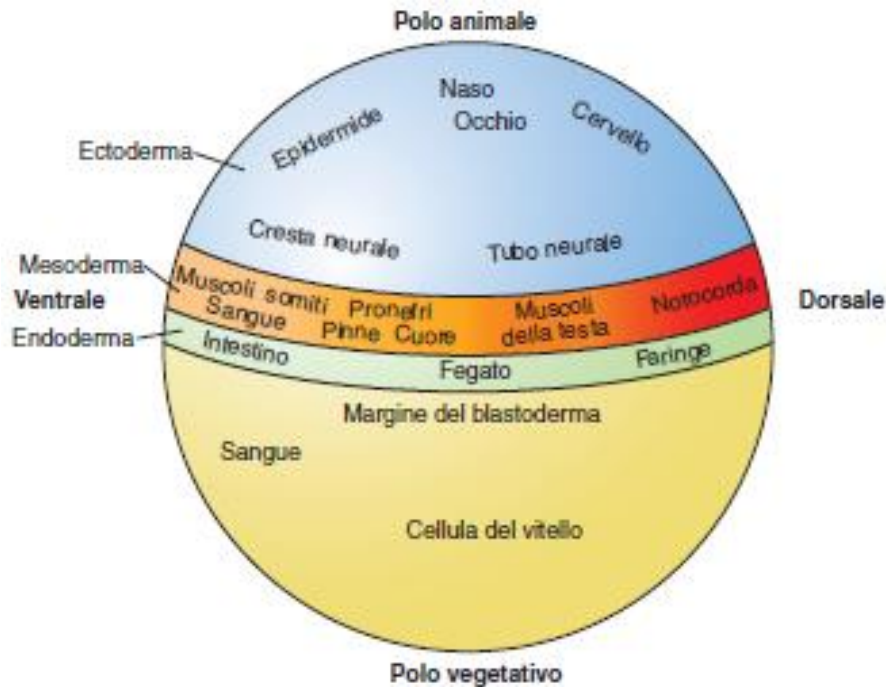
(A)



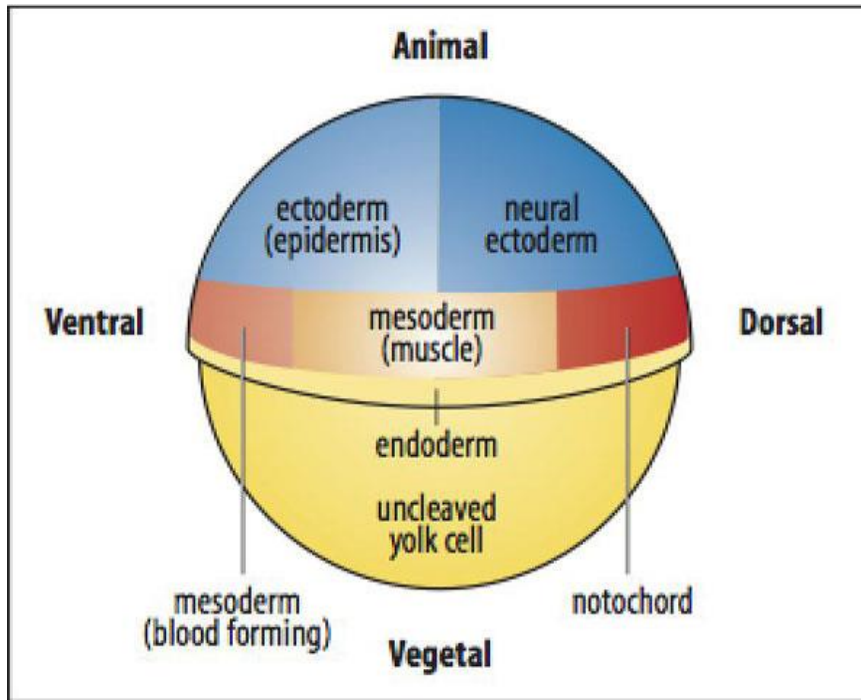
(B)



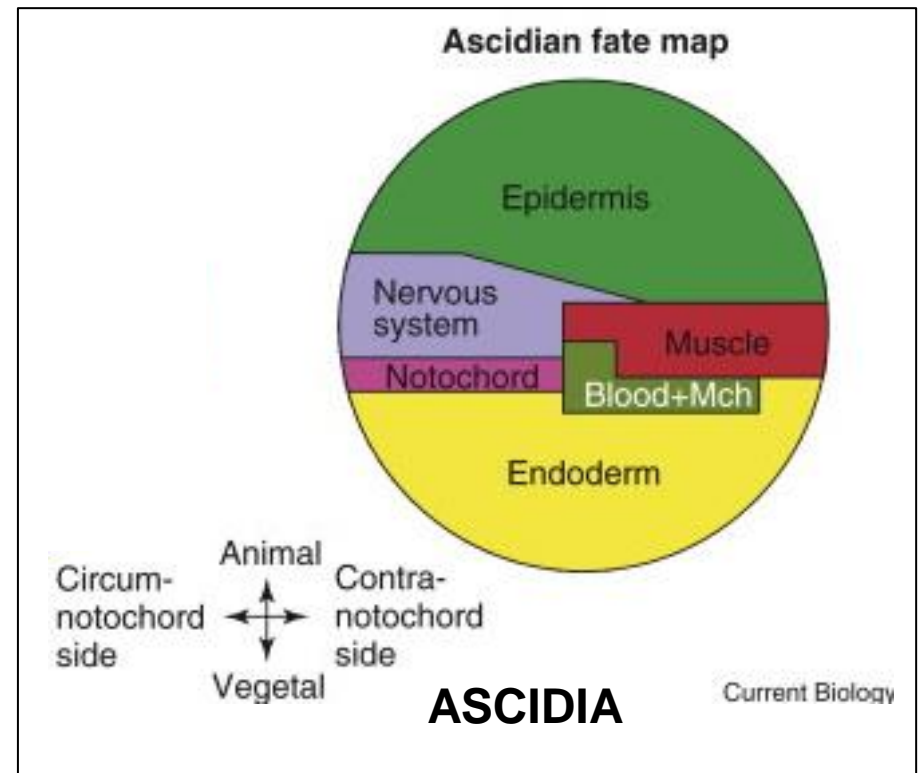
(C) Animal pole (egg viewed from top)

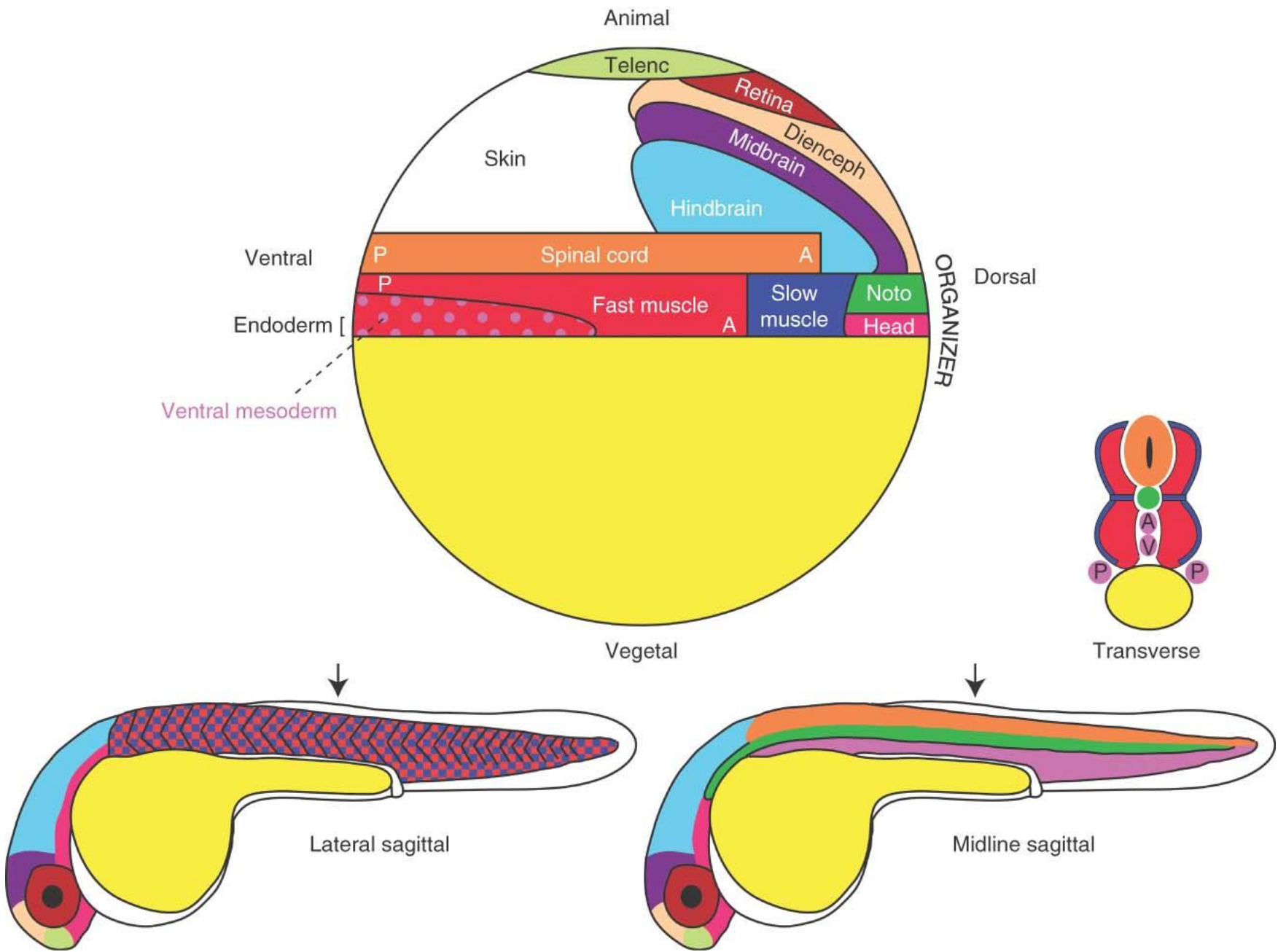


LE MAPPE DEI TERRITORI PRESUNTIVI NELLE BLASTULE DI ZEBRAFISH E TUNICATI RIVELANO UN PIANO DI ORGANIZZAZIONE CONSERVATO

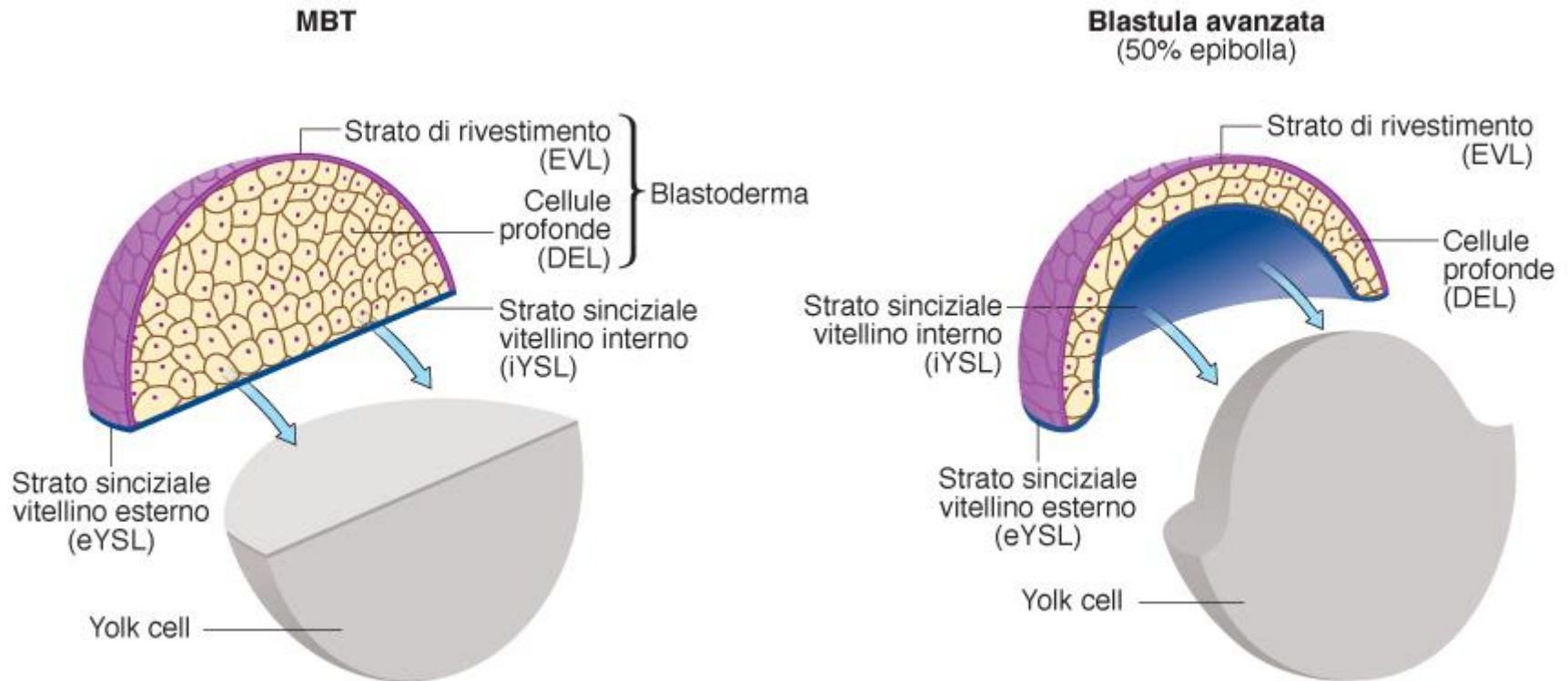


ZEBRAFISH





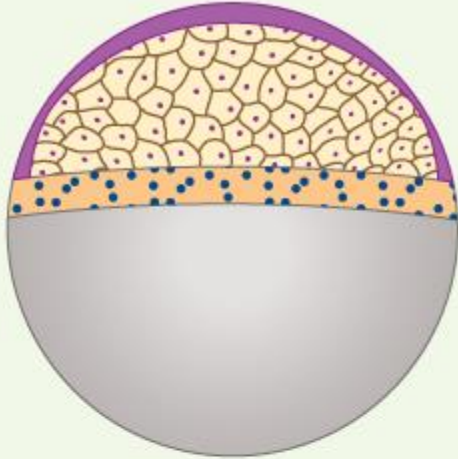
FASI INIZIALI DELL'EPIBOLIA NELLA BLASTULA DI ZEBRAFISH



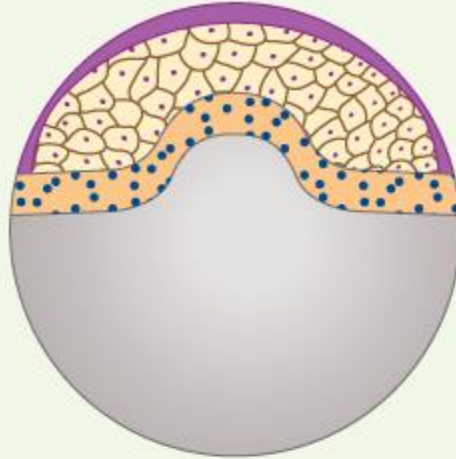
IL BLASTODISCO SI ASSOTTIGLIA PER EFFETTO DI MOVIMENTI DI INTERCALAZIONE RADIALE DELLE CELLULE DEGLI STRATI PIU' INTERNI
Si riduce il numero di strati ed aumenta la superficie

A

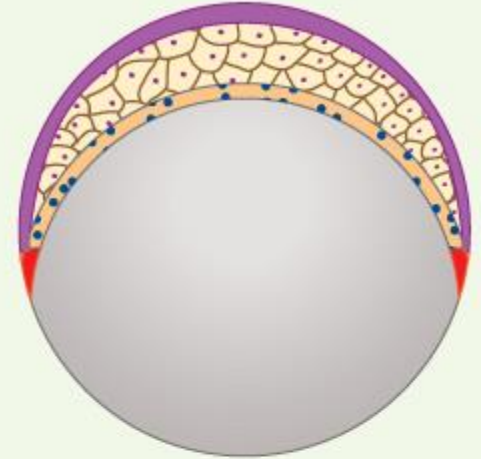
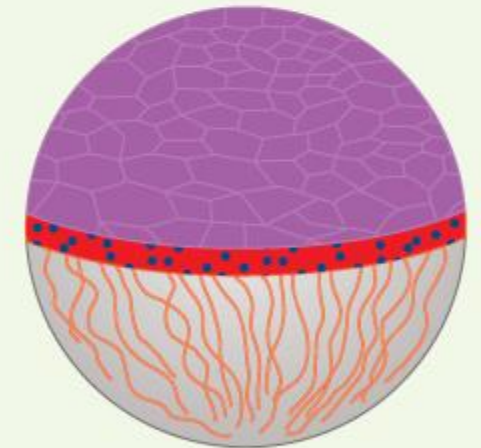
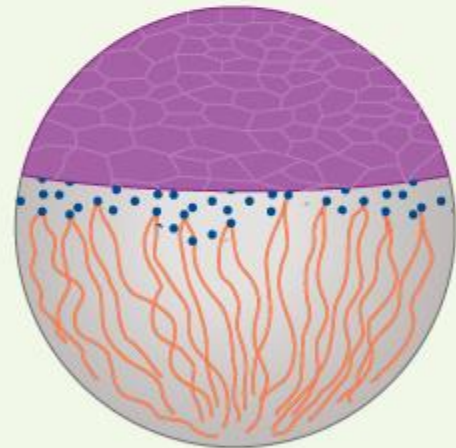
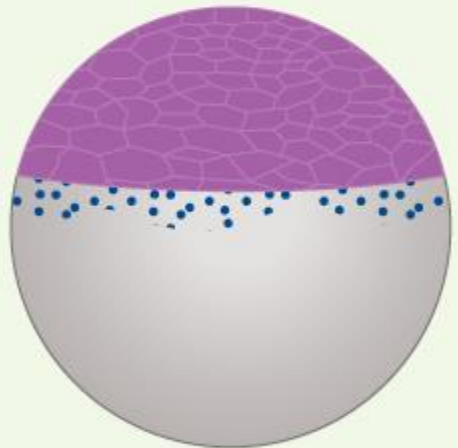
MBT



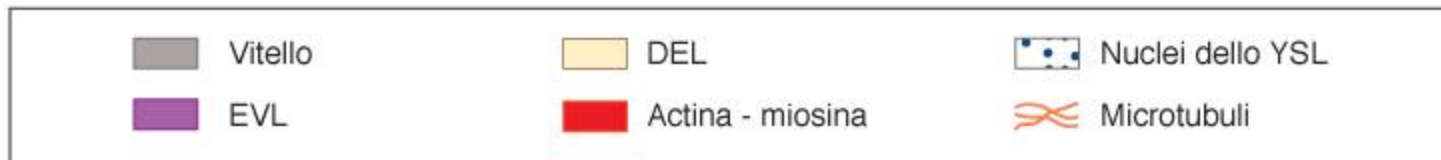
30%



50%

**B**

All'epibolia contribuisce la trazione esercitata dai nuclei del sincizio vitellino





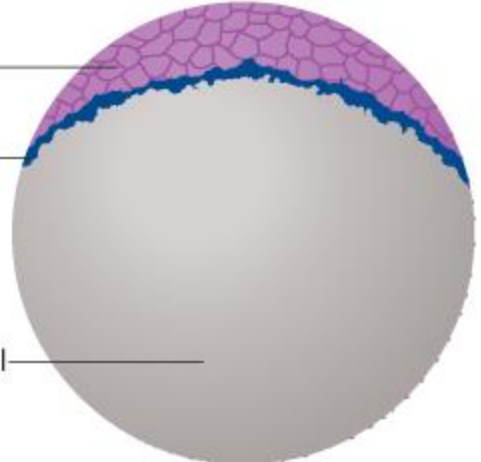


Polo animale




EVL

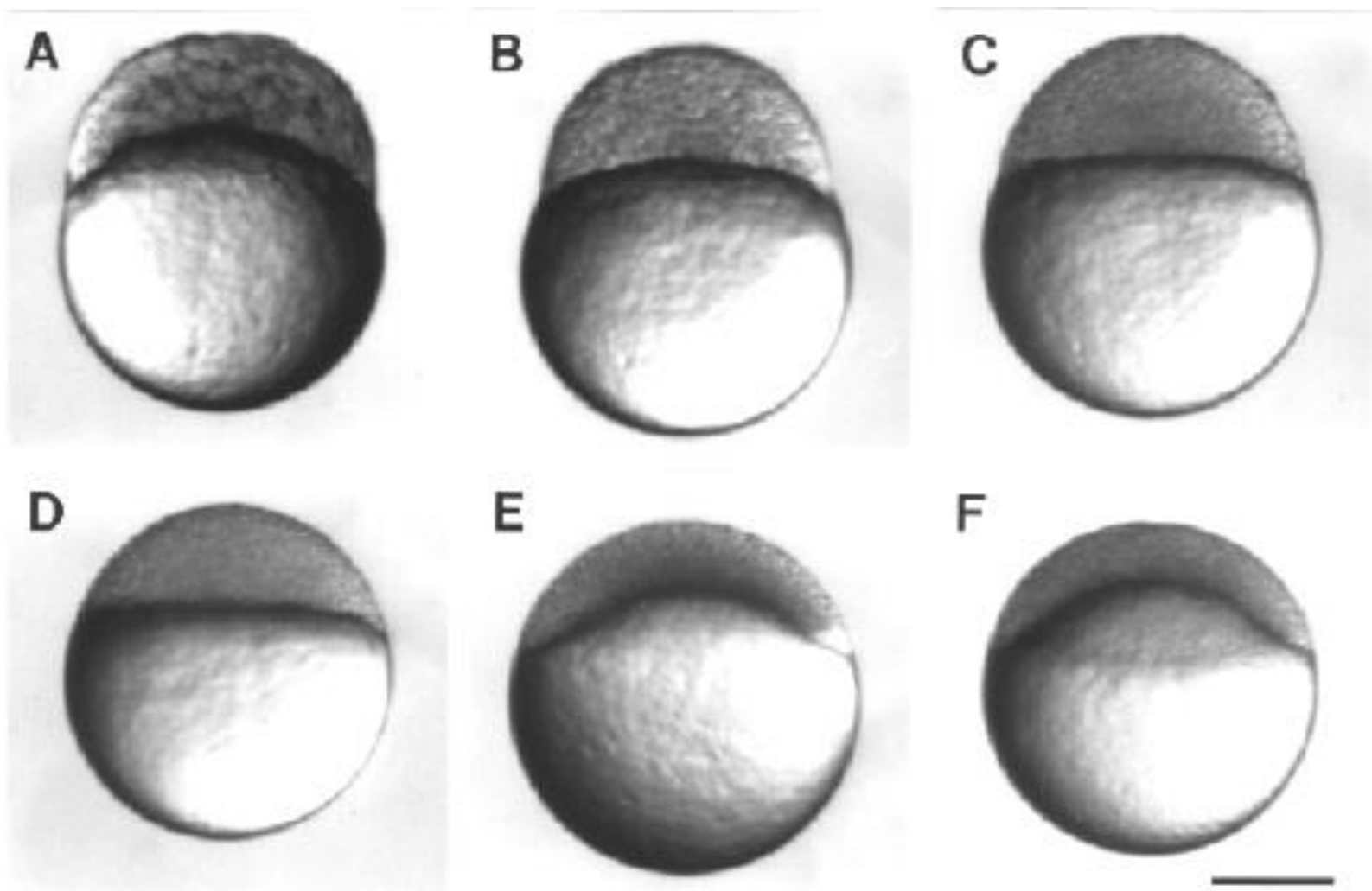
eYSL

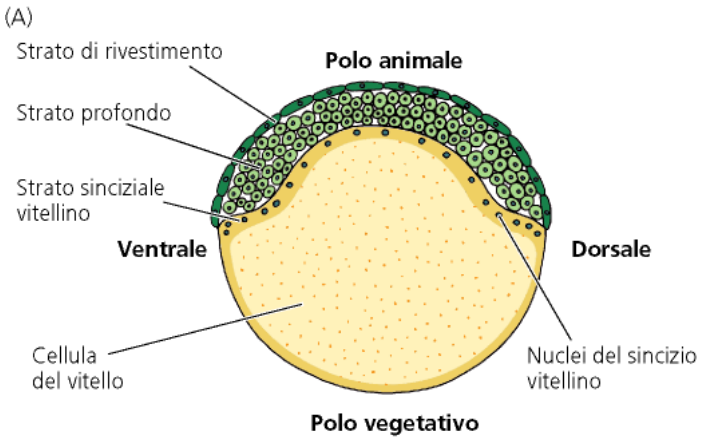
Yolk cell



Polo vegetivo

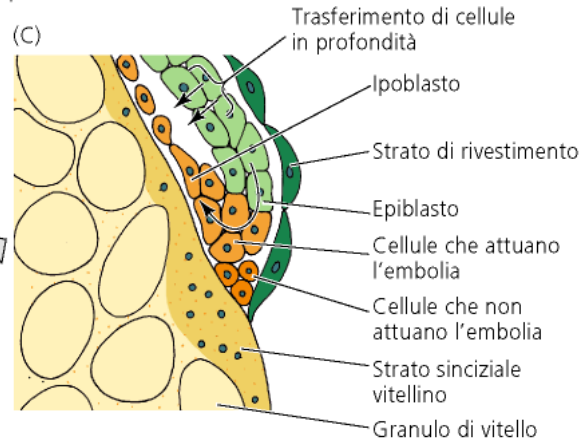
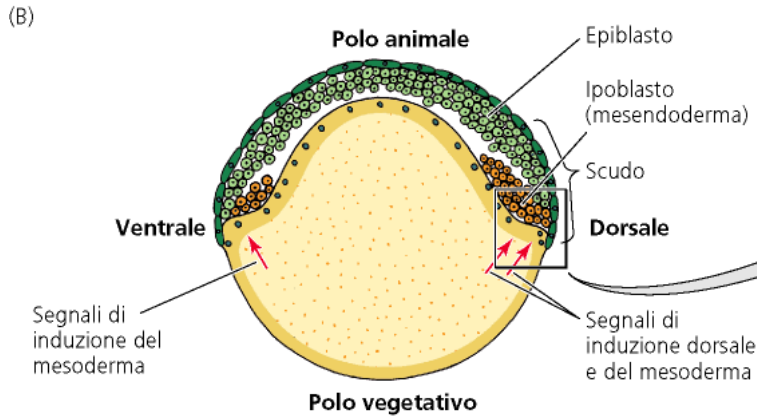




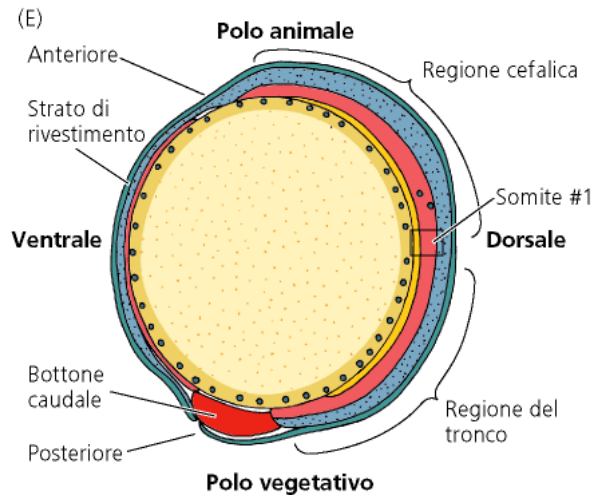
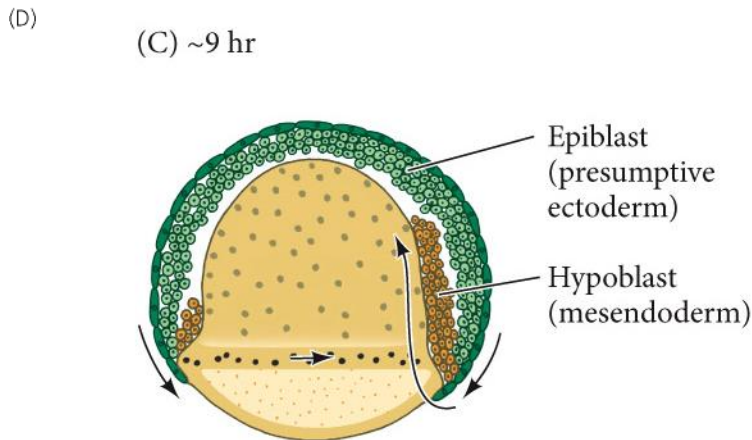


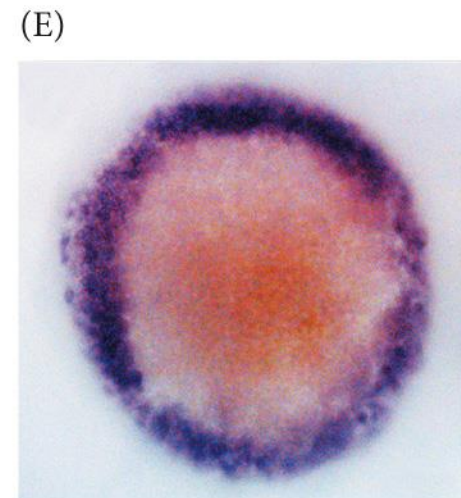
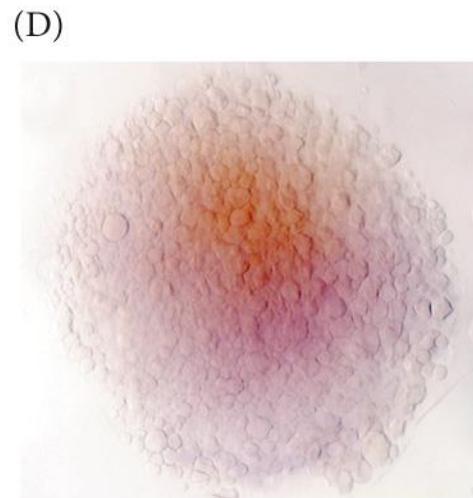
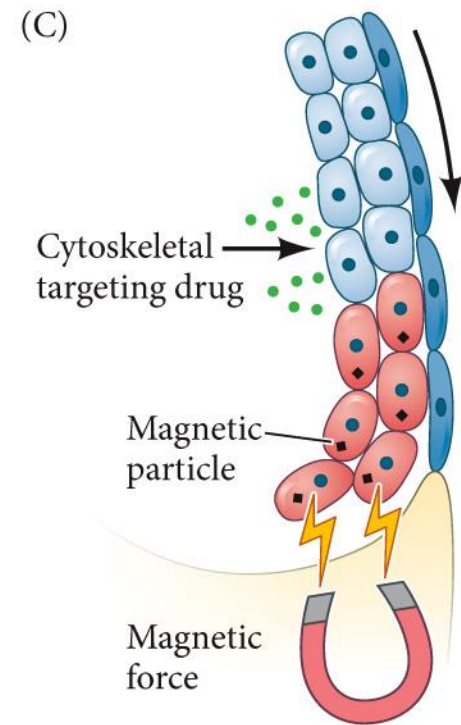
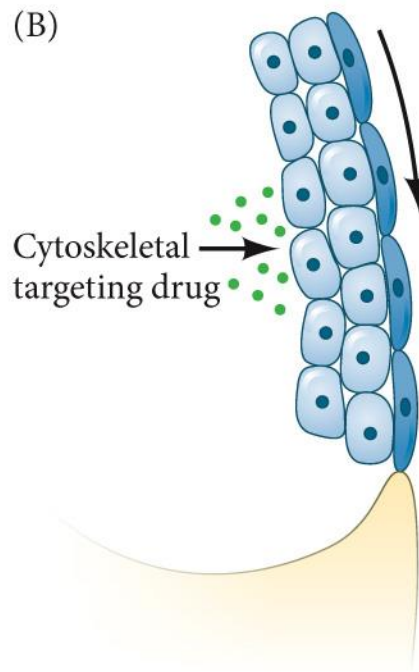
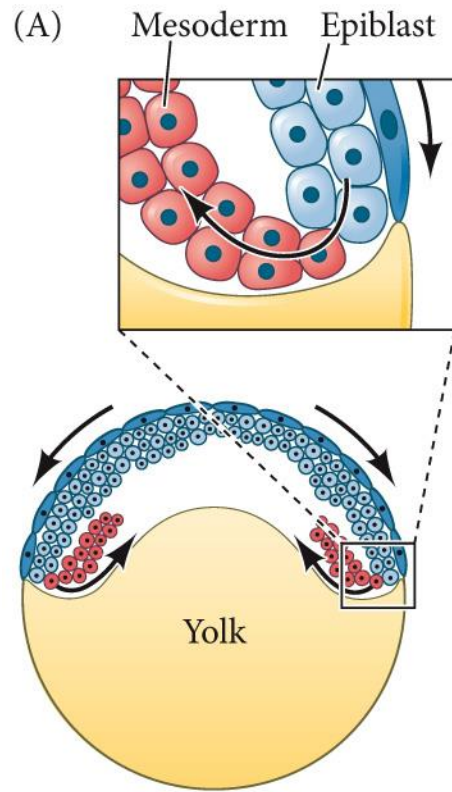
Strato esterno= periderma (verde scuro)
Epiblasto= ectoderma (verde)
Ipoblasto= mesoderma (arancio, poi rosso)
endoderma (arancio, poi giallo)

- | | |
|---------------------------------------------------------------|-----------------------------------------------------------------------------------------------------|
| ■ Mesoderma | ■ Mesendoderma: precursori sia del mesoderma sia dell'endoderma |
| ■ Ectoderma, neuroectoderma | ■ Endoderma |
| ■ Epiblasto pluripotente | ■ Strato di rivestimento (EVL) |



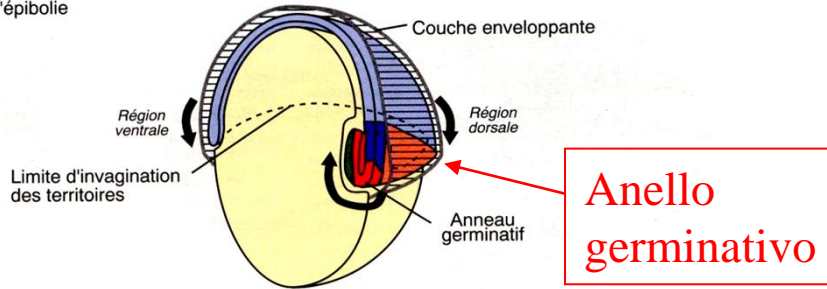
Anello germinativo



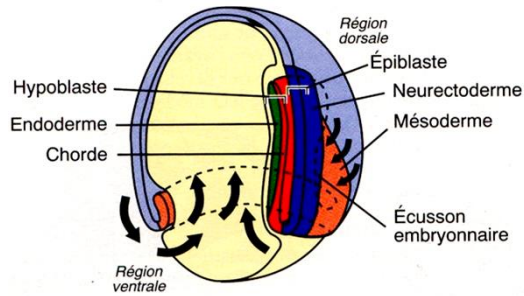


Gastrulation

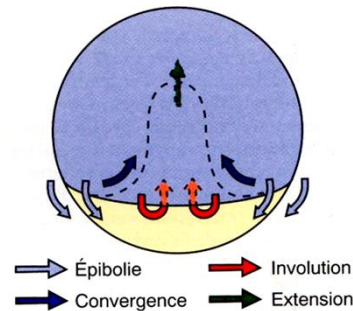
a) Embryon à 50% d'épibolie



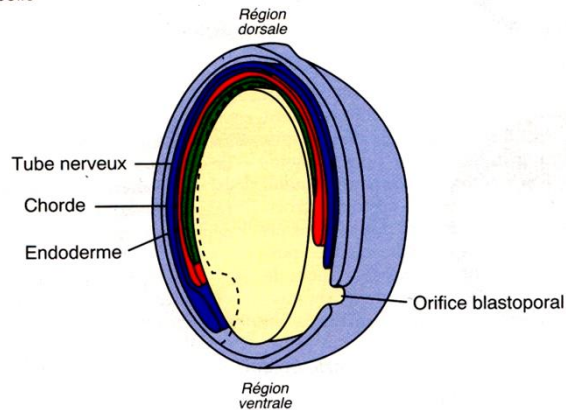
b) Embryon à 75% d'épibolie (sans la couche enveloppante)



c) Embryon à 75% d'épibolie : mouvements des territoires en vue externe dorsale



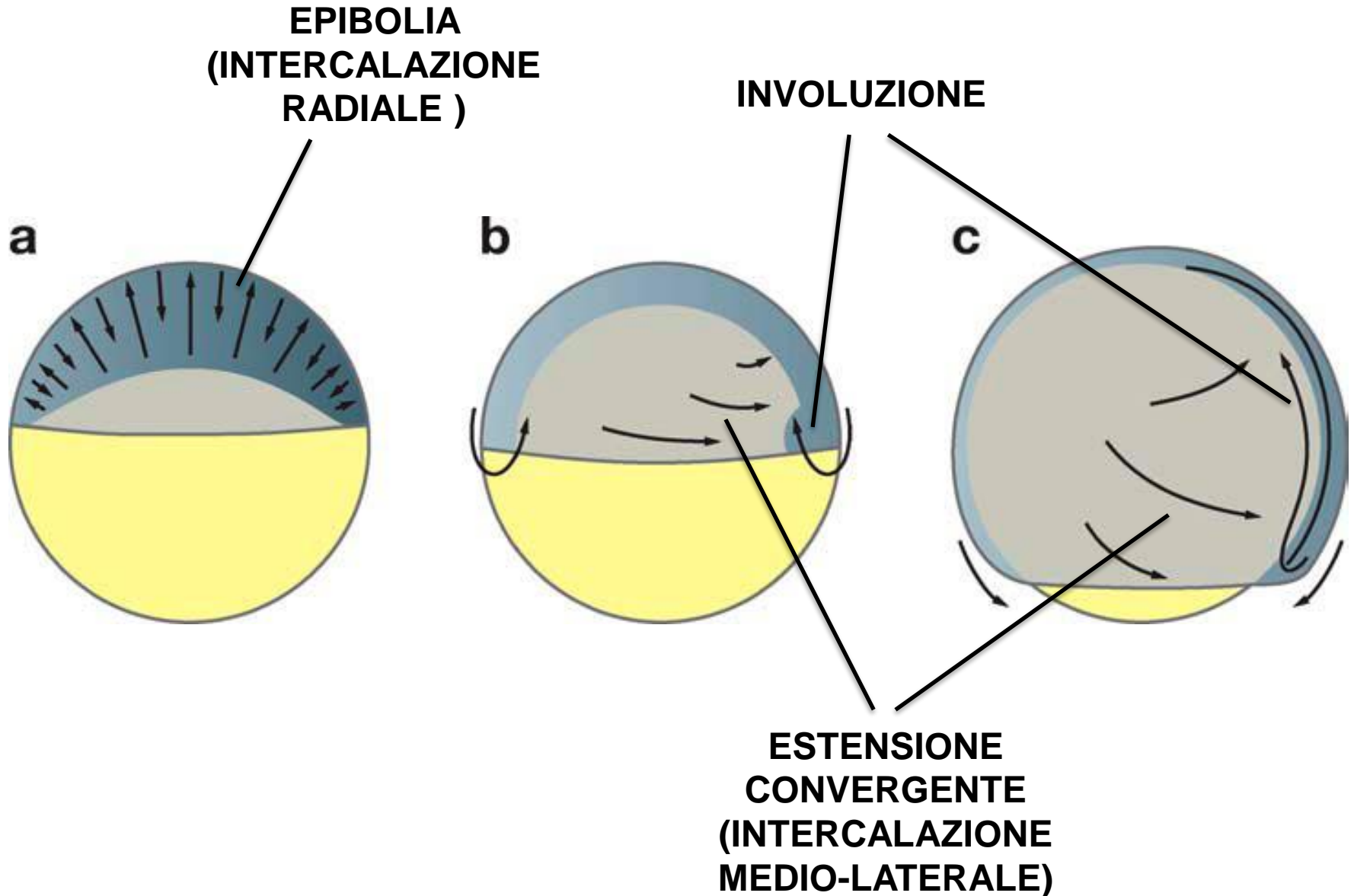
d) Embryon à 100% d'épibolie

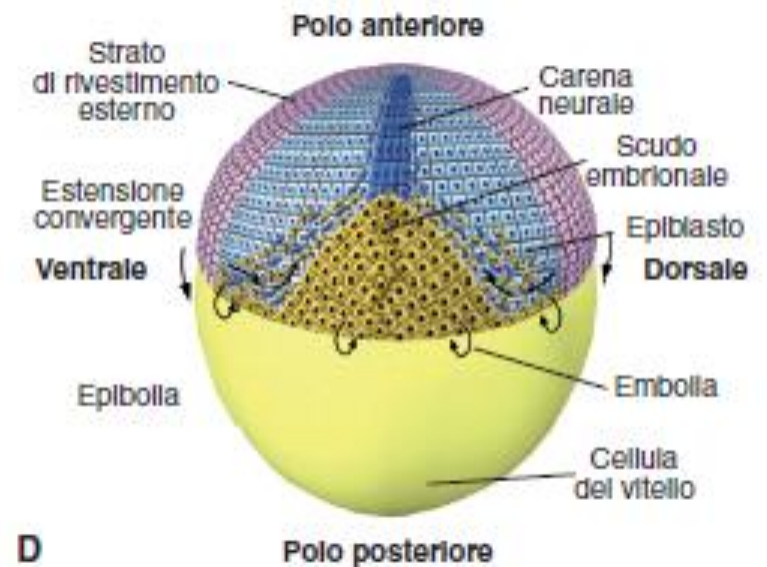
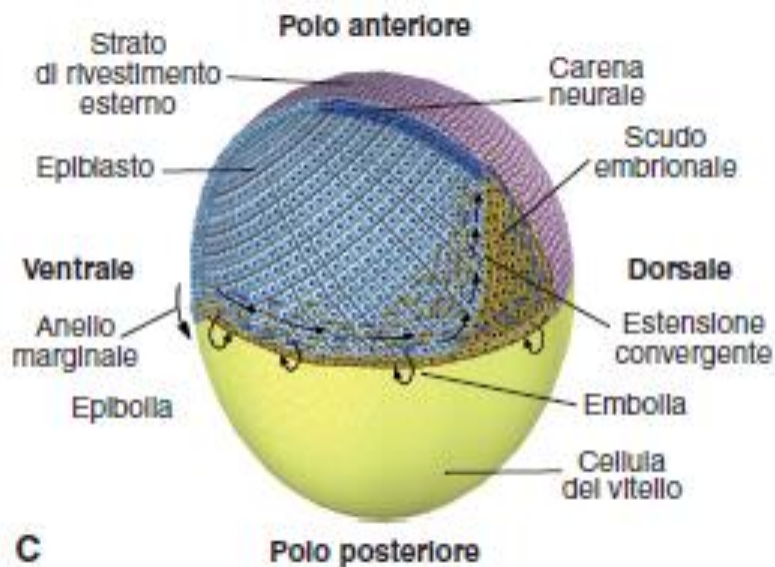
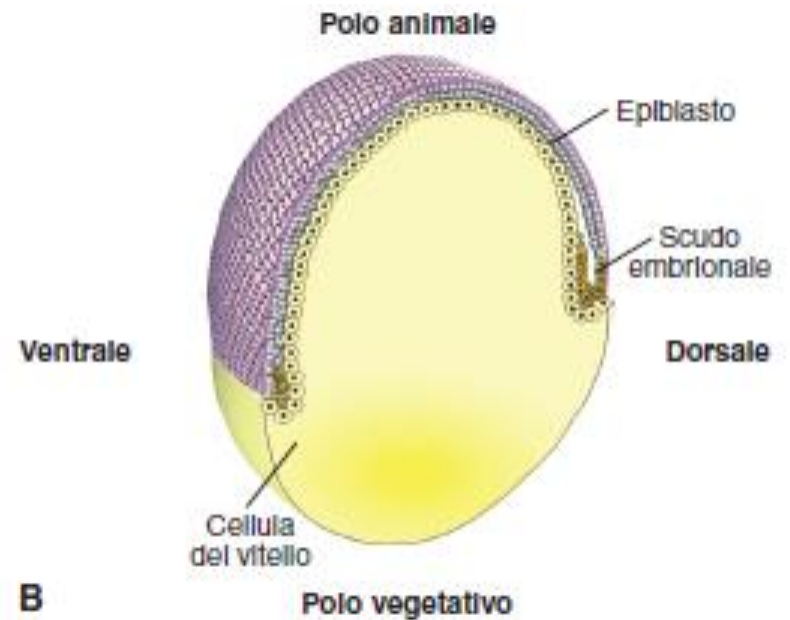
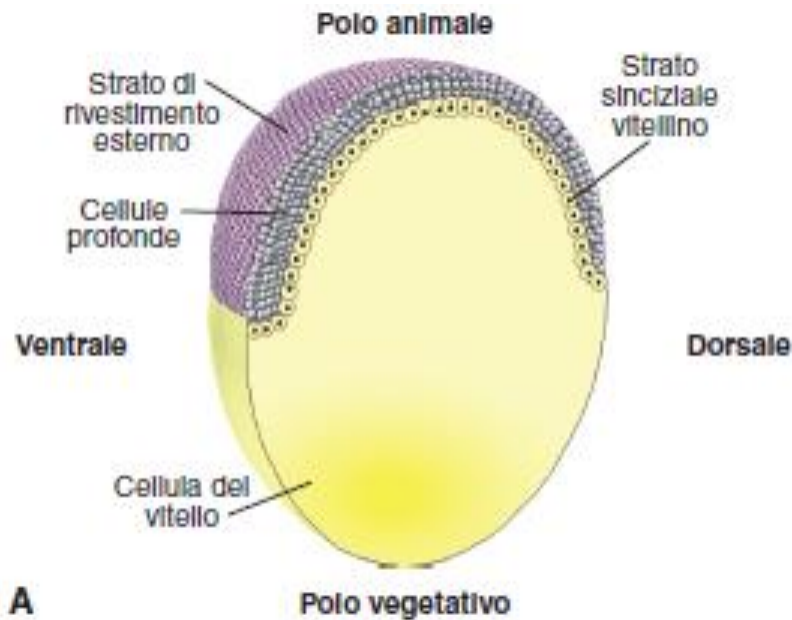


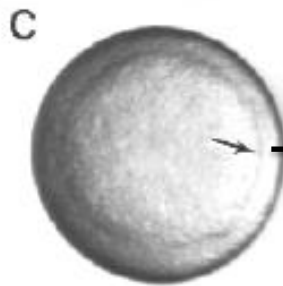
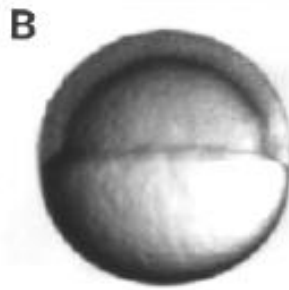
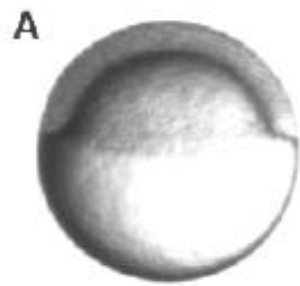
Strato esterno= periderma
 Epiblasto= ectoderma
 Ipoblasto= mesoderma
 endoderma

1. Epibolia
2. Involuzione
3. Estensione convergente


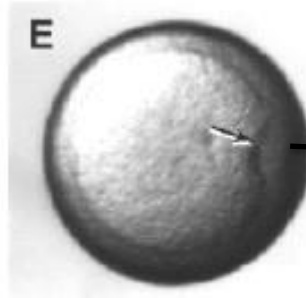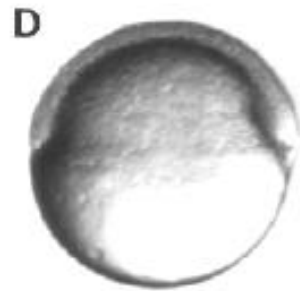
MOVIMENTI CELLULARI DURANTE LA GASTRULAZIONE IN ZEBRAFISH



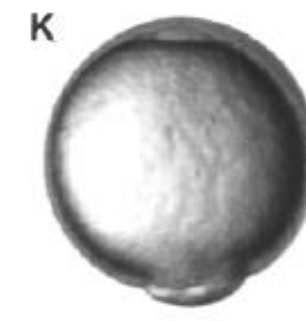

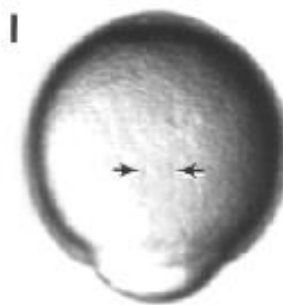
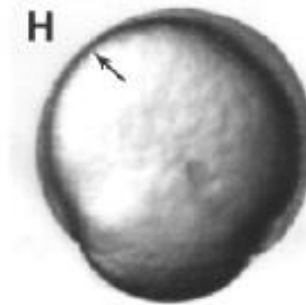
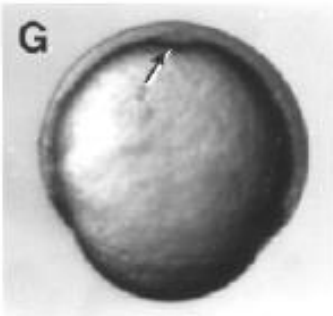


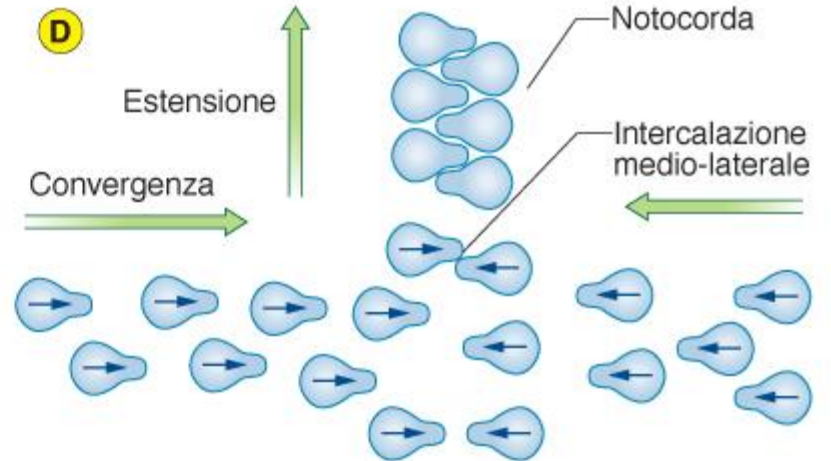
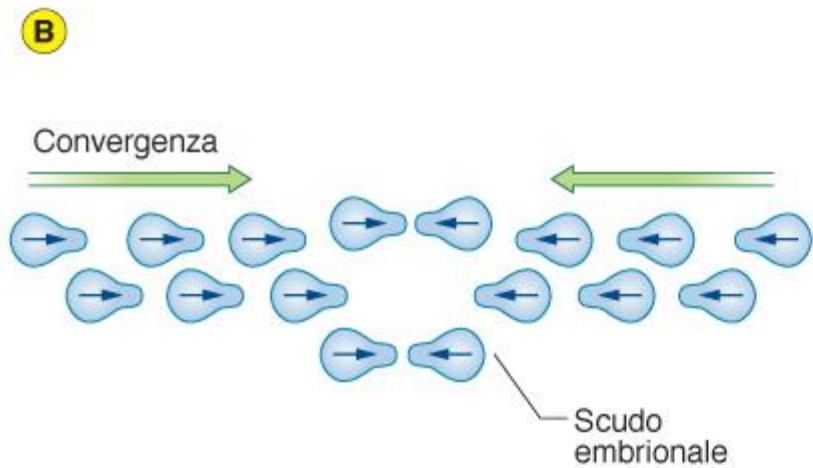
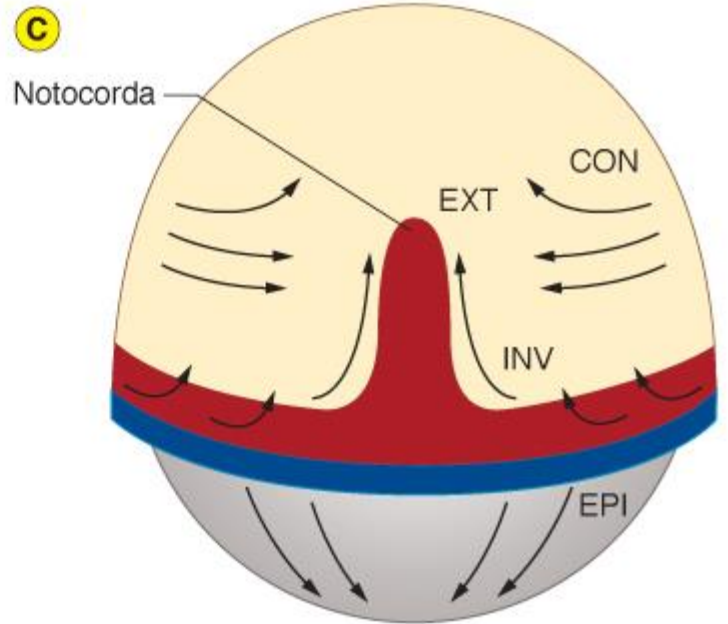
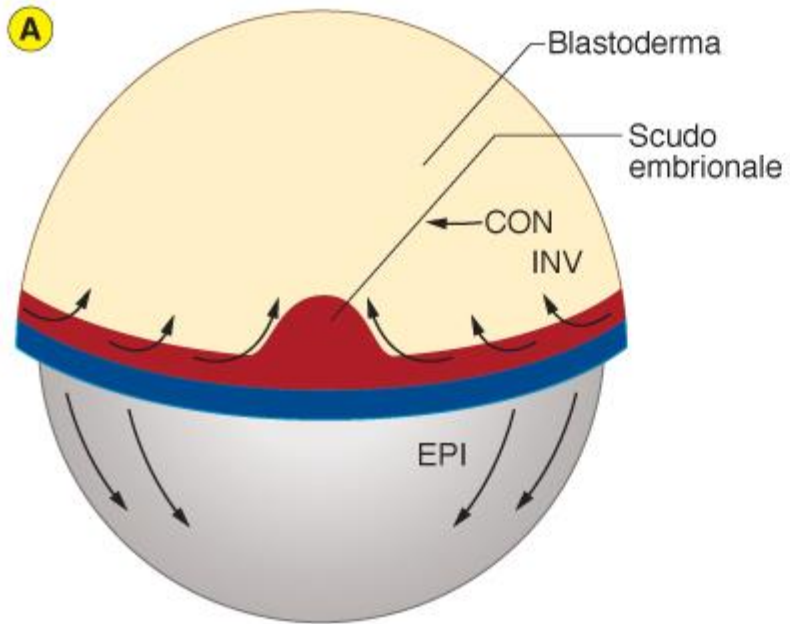


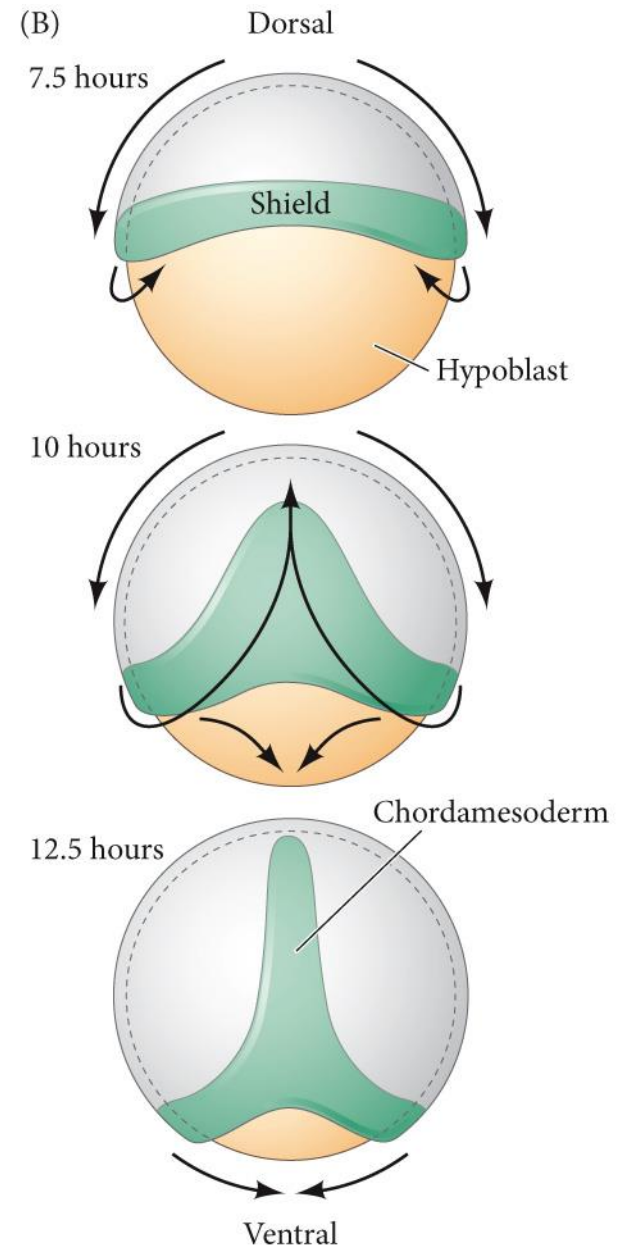
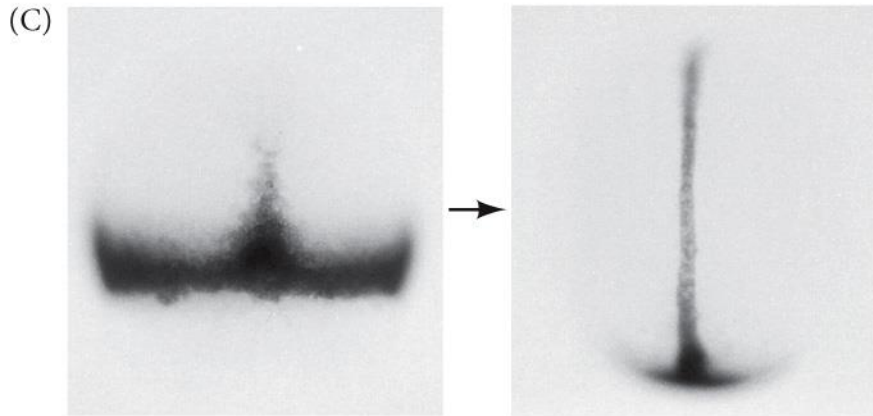
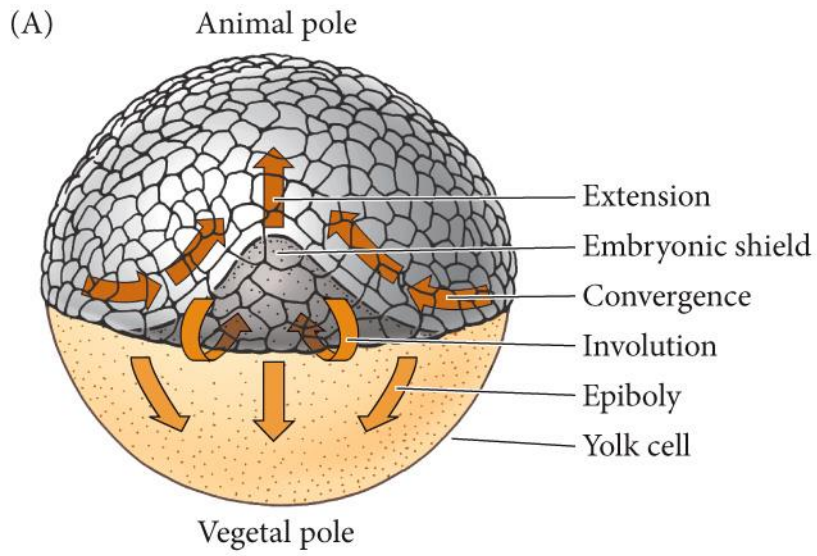
**ANELLO
GERMINATIVO**



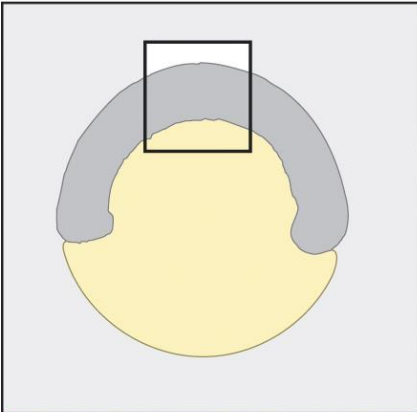
SCUDO



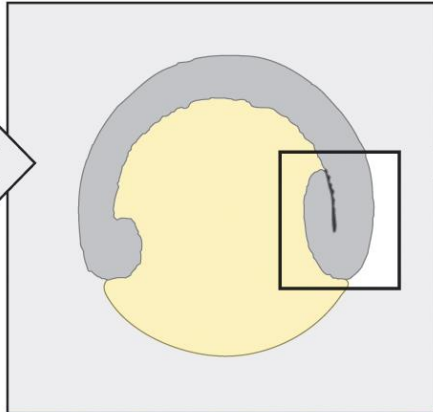
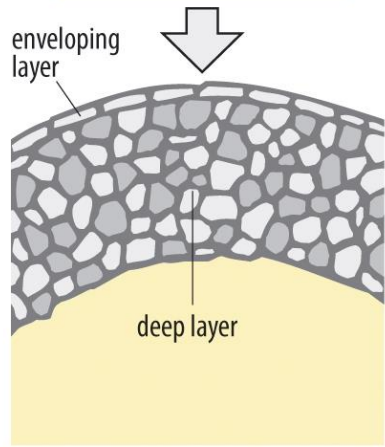
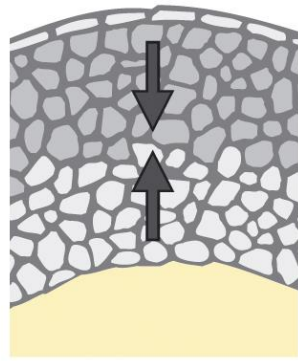




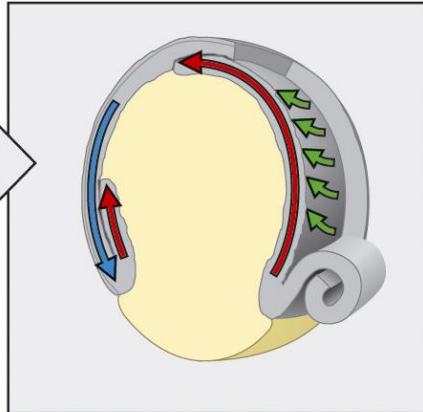
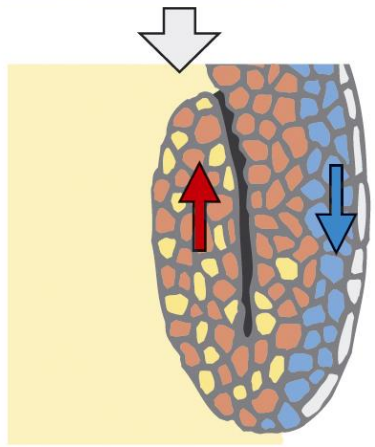
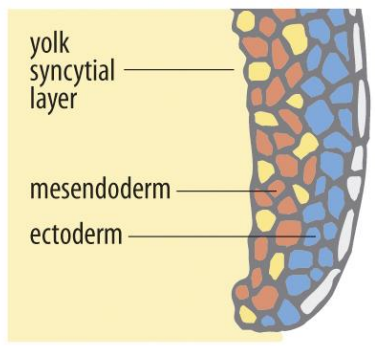
 Convergence and extension
 Epiboly  Involution



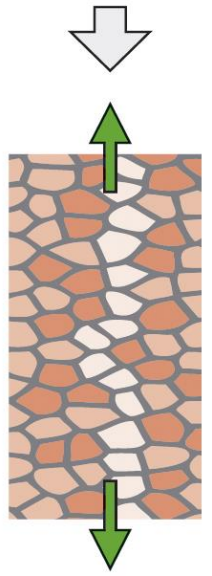
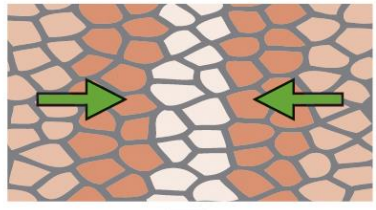
Radial intercalation

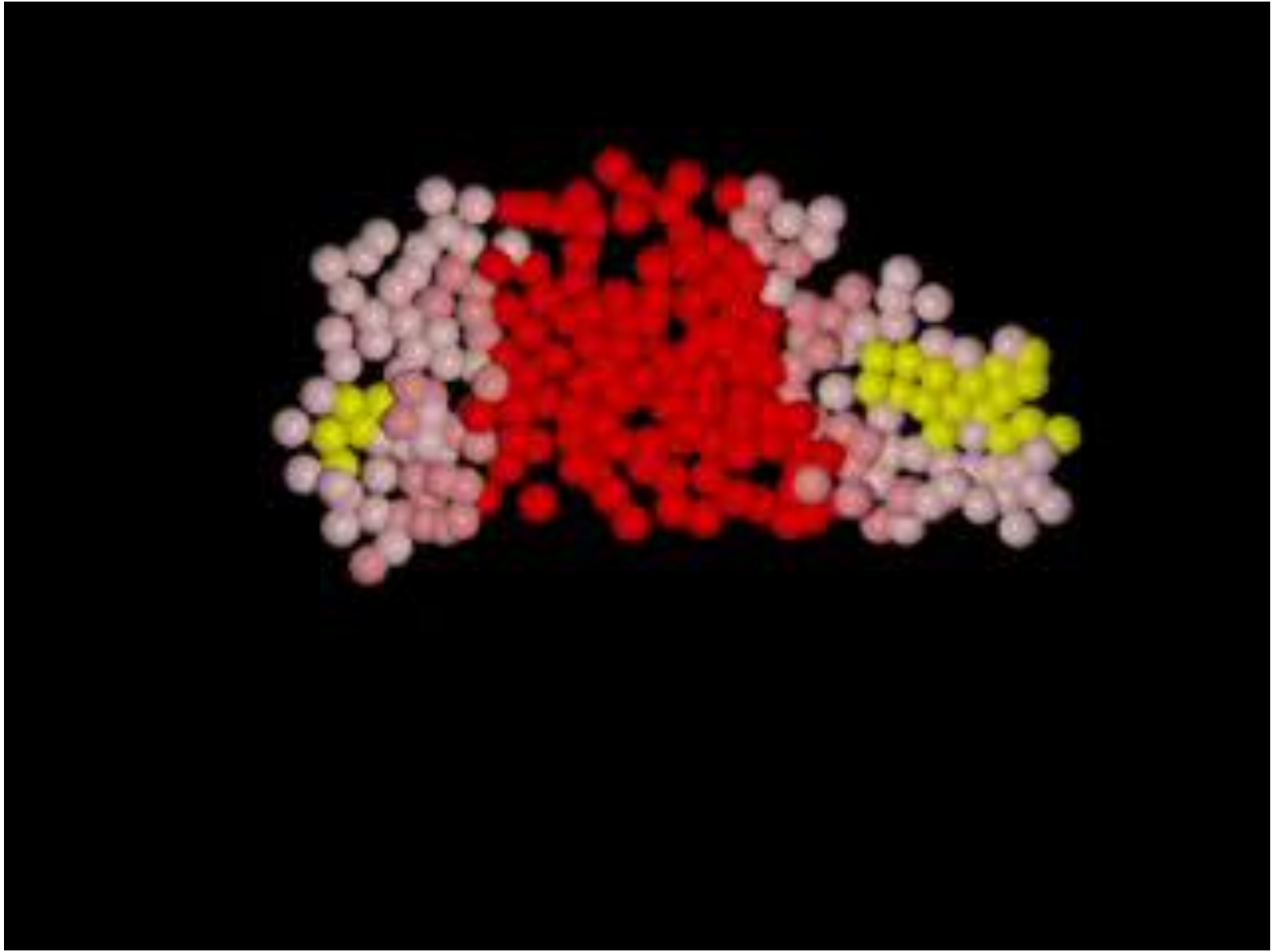



Epiboly

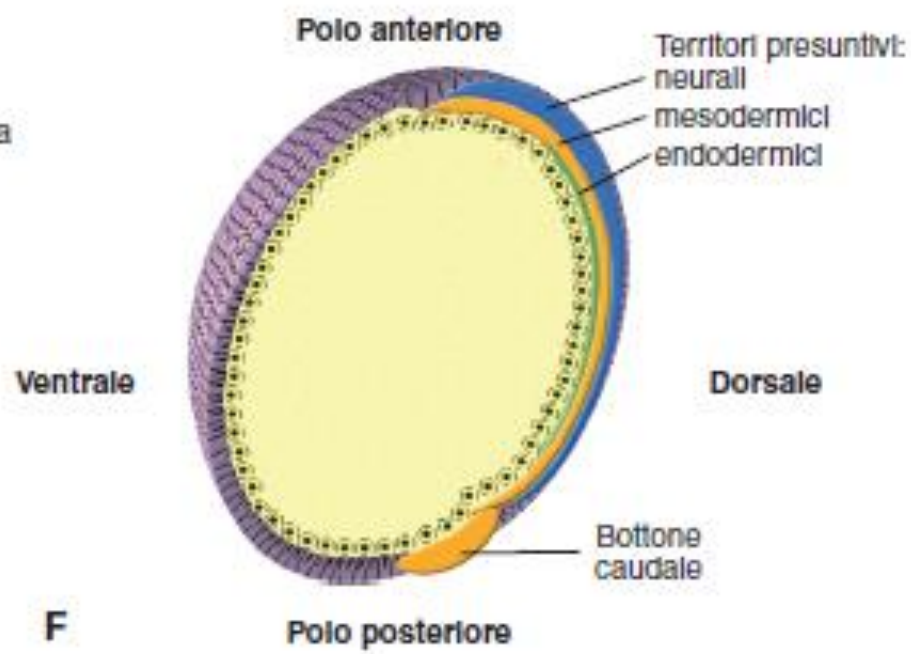
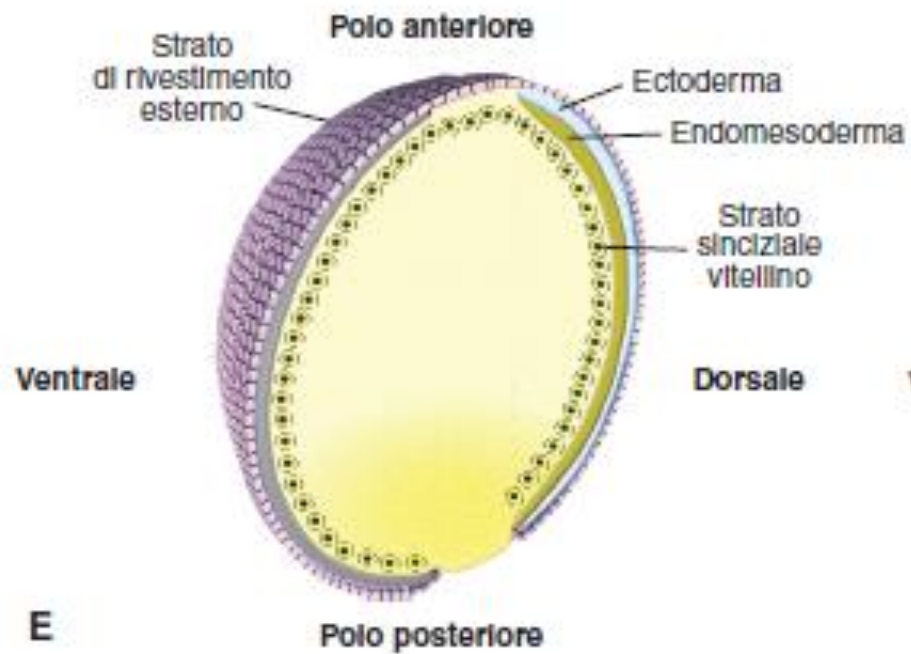


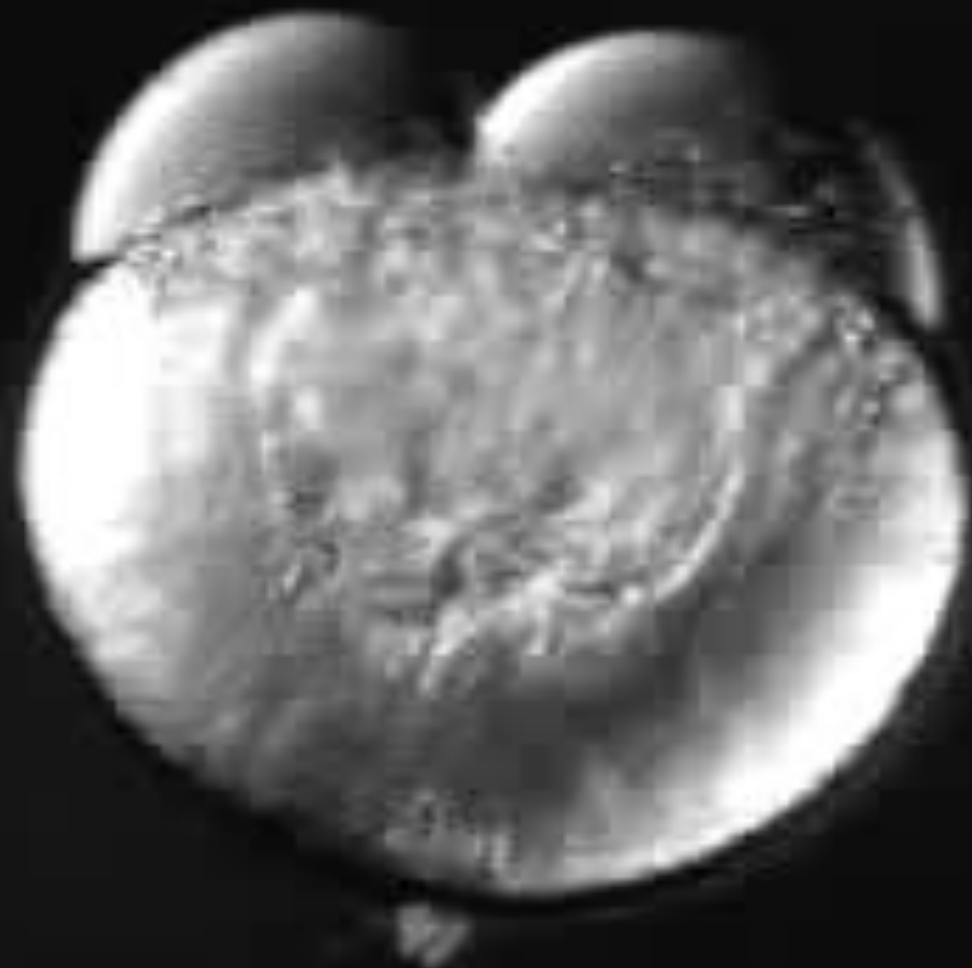
Convergent extension











FASI DELLA NEURULAZIONE IN ZEBRAFISH

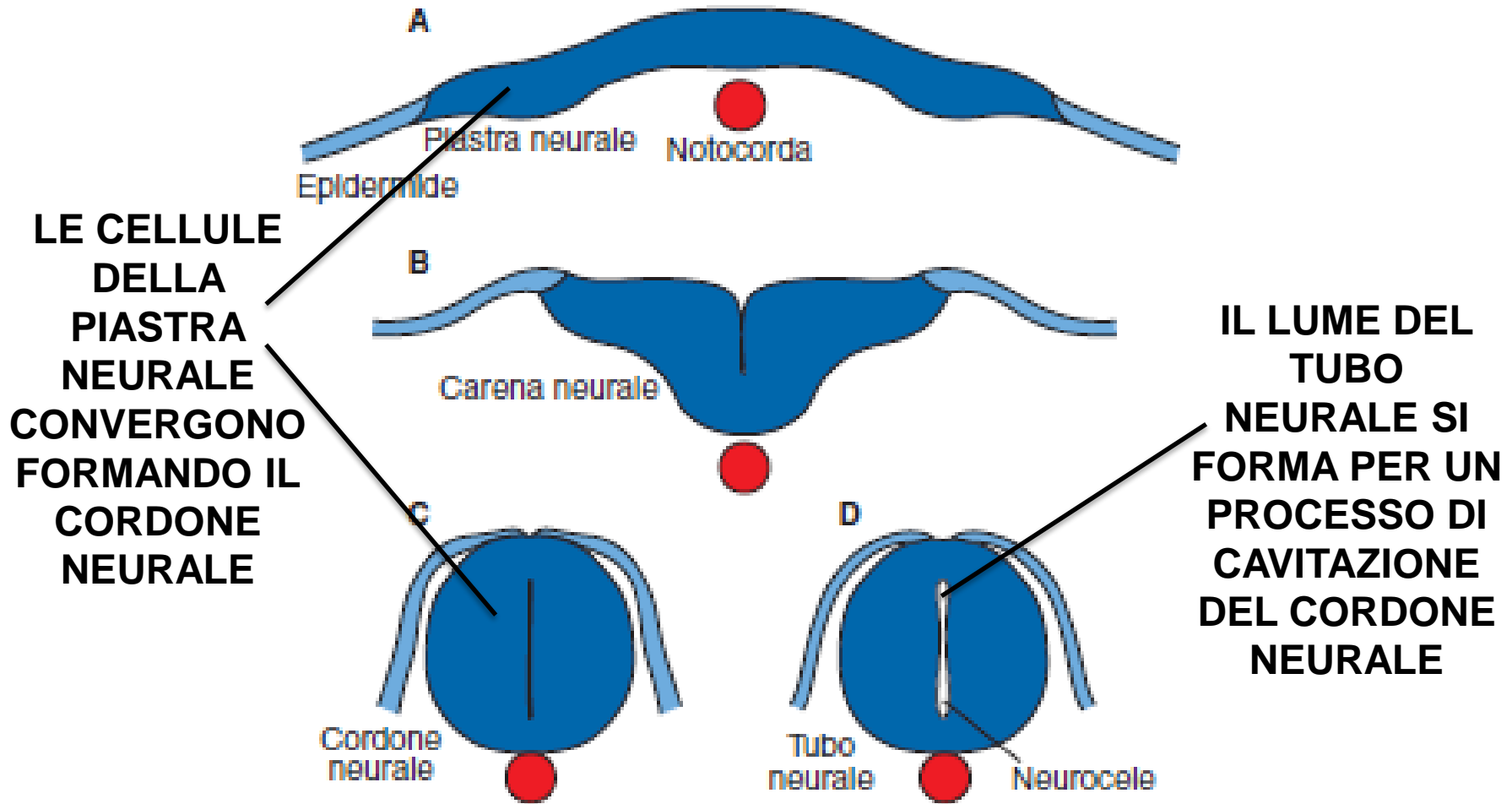


Figura 8

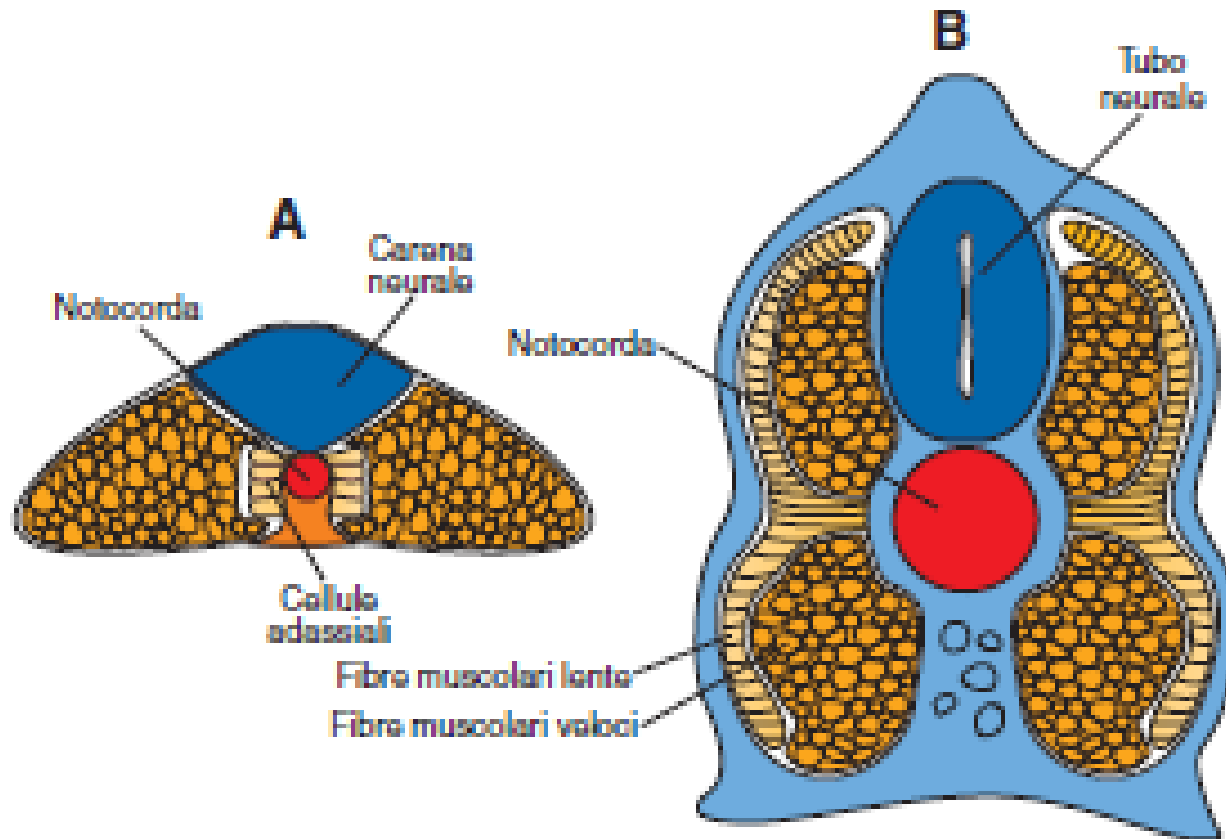
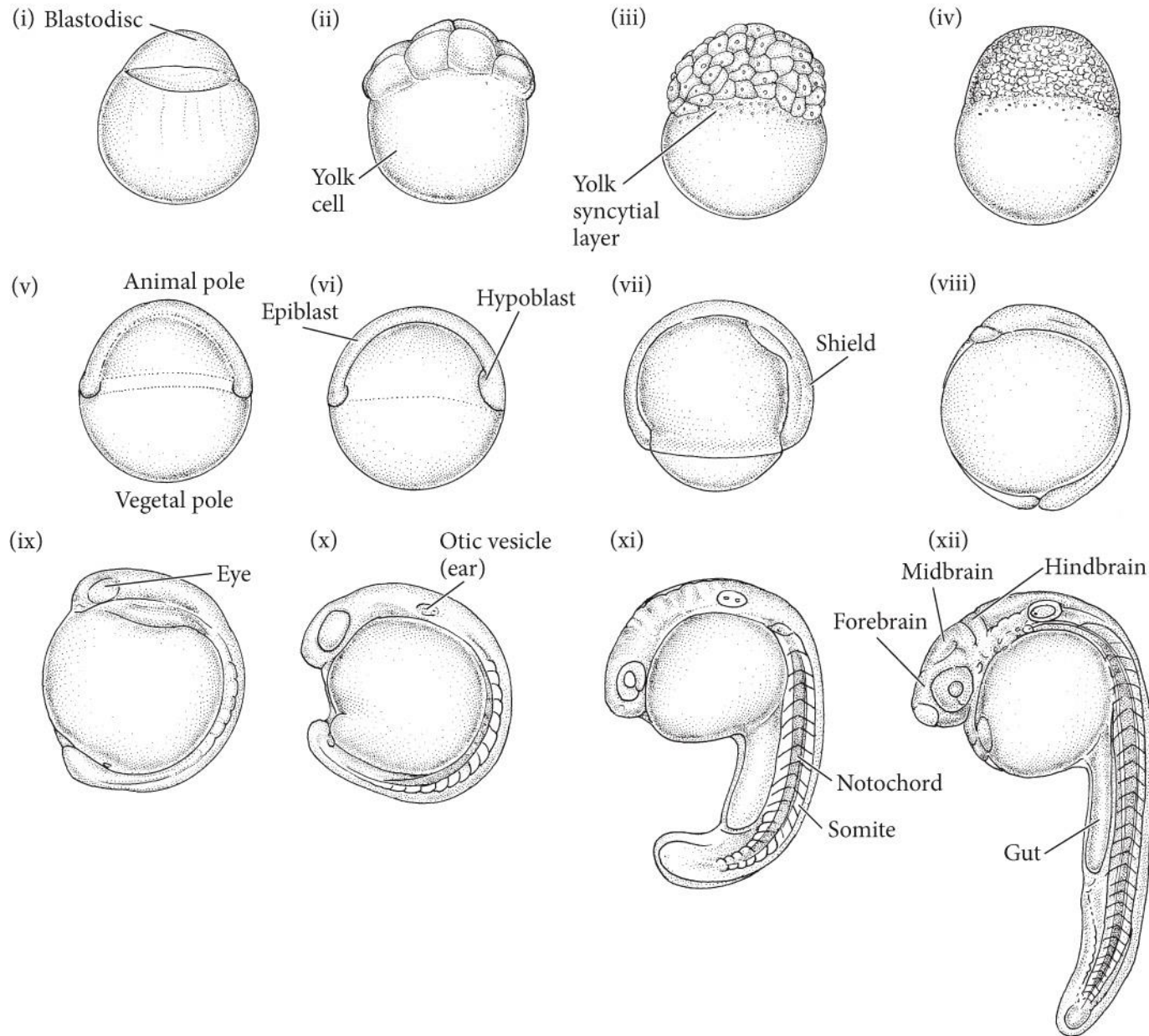
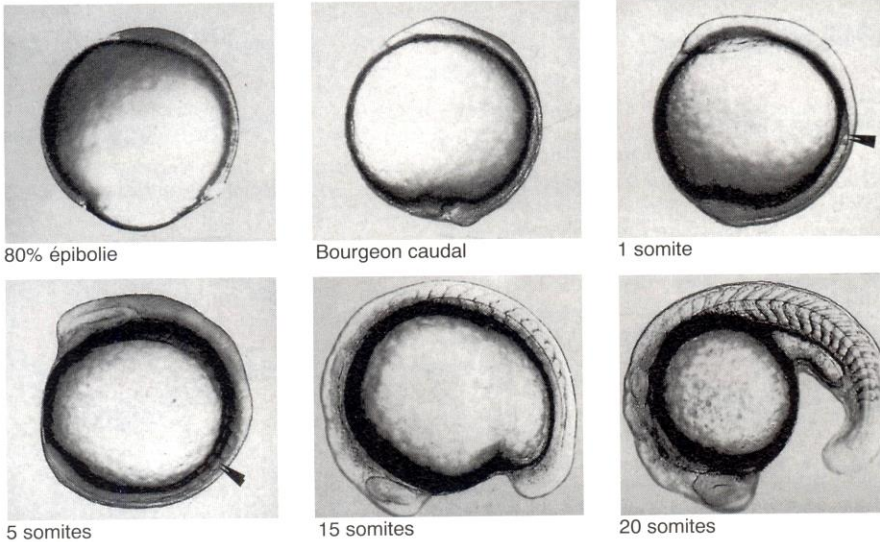


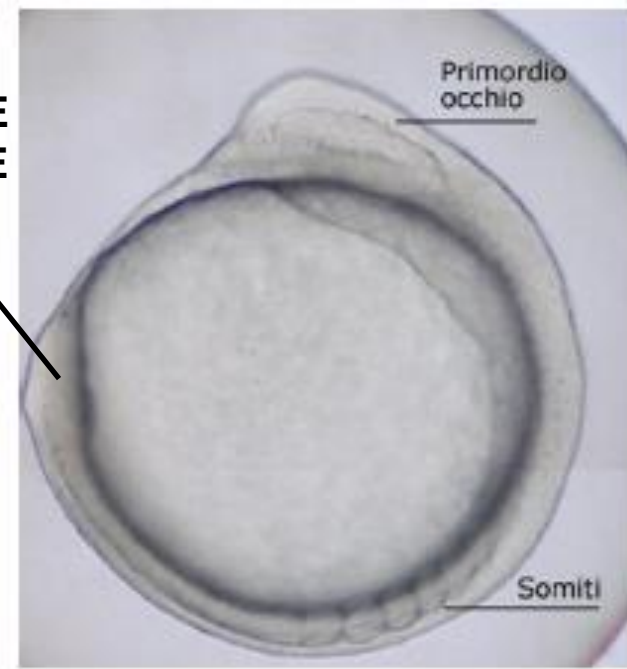Figura 7



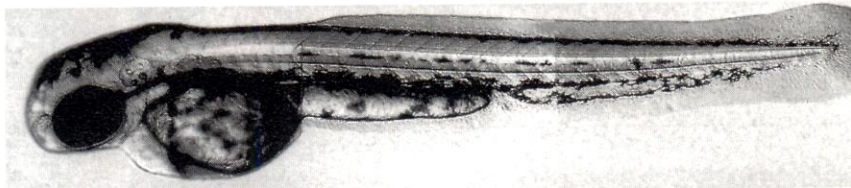
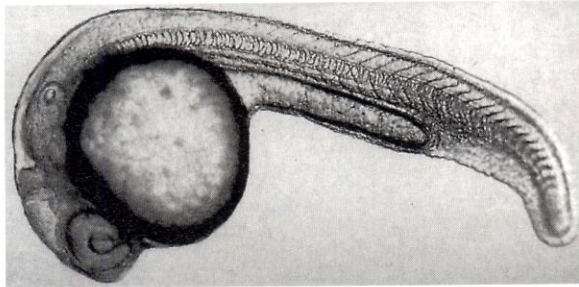
a) Formation du jeune bourgeon caudal et somitogénèse



BOTTONE CAUDALE



b) Redressement du bourgeon caudal

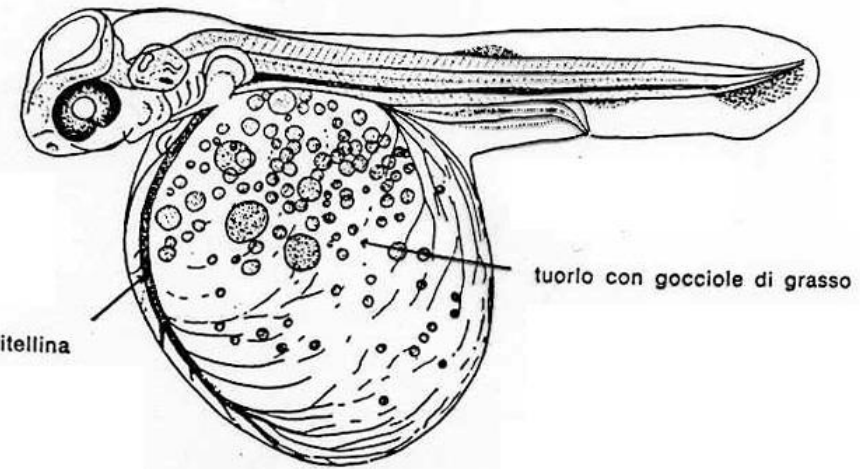


Bourgeon caudal âgé

c) Formation de la larve nageuse



(d'après Boulekbache, 1998)



Sacco del tuorlo